



Volumetric analysis of preoperative cystic jaw lesions using Manual segmentation and semiautomated segmentation

Yasmein Maher El-beblawy*, Ahmed Mohamed Bakry, Maha Eshaq Amer Mohamed
Department of Oral and maxillofacial Radiology, Faculty of Dentistry, Minia University Minia,
Egypt

Corresponding author: Yasmein Maher El-beblawy

E-mail: yasmin.maher@mu.edu.eg

Abstract

Objectives The aim of this study was to assess the volume of cystic jaw lesions using semiautomatic and manual image segmentation. **Materials and methods** 49 CBCT archived radiographs were assessed to estimate the volume of cystic lesions. Cronbach's alpha test was used to detect interobserver agreement. Simple linear regression analysis between the two methods in different-sized lesions and Correlation between the two methods in different-sized lesions was assessed. **Results** Volume showed no statistically relevant p-value (0.051 and 0.087) for small and large-sized lesions respectively, therefore this parameter does not exhibit proportional bias. **Conclusion** A semiautomated method for CBCT images has several advantages the risk of nonobjectivity and interobserver variability is greatly reduced by minimizing the active manual input of the user.

Key words: jaw cyst, cyst volume, manual image segmentation, semiautomated image segmentation

INTRODUCTION

According to cyst size, jaw cysts can be classified into small, median, and large mandibular cysts, which often invade teeth and can seriously affect quality of life. Cysts tend to enlarge and grow, leading to resorption of bone tissue. Depending on the degree of resorption, cysts may cause severe damage such as bone fractures. Treatment planning for cysts depends on cyst location, size, the extent of tissue damage, the availability of surgical access, patient's age, the proximity of the cyst to vital structures, and the significance of the affected teeth in terms of eruption. Marsupialization or decompression is the first consideration if the lesion invades adjacent structures or if primary enucleation could cause pathological fractures or neurological damage.¹⁻³

After the development of Computer Aided Diagnosis and Detection (CADD), the radiologists mostly depend on the computer for very efficient and early diagnosis. Radiological size delineation has its relevancy in the context of diagnostic and therapeutic management decisions. Volume analysis is therefore a useful parameter for risk stratification, which provides stronger evidence about volume changes and, indirectly, about the healing rate and improve patient individualized treatment.⁴⁻⁶

This is a definite indication for a three-dimensional assessment of cysts and the segmentation of cysts in bone tissue. This detailed assessment provides surgeons with information about the total volume of a cyst and the spatial relationship between the cyst and surrounding high-risk structures. In

addition, surgeons can evaluate the real dimensions of the cyst when removing a cyst from the bone.^{7,8}

Image segmentation techniques can be divided into manual, automatic, and semi-automatic techniques. Manual segmentation techniques require the user to manually mark voxels on each slide by outlining the structure of interest slice by slice on a 3D image. This requires prior knowledge about the shape of the structure of interest and the intensity of grey values that compose its image. This technique is exact; however, it is user-dependent, time-consuming, and only feasible for small image datasets. Manual Segmentation is necessary as it provides the ground truth labeled images to further develop semi-automatic and fully automatic segmentation techniques.⁹⁻¹⁰ **Thus the aim of this study was to assess volume of cystic jaw lesions using semiautomatic and manual image segmentation.**

MATERIALS AND METHODS

This retrospective using archived data was granted by the Research Ethics Committee (REC) of the faculty of dentistry, Minia University, under approval number 534 – 1/11/2021. All 36 images were taken using the same CBCT scanner (SCANORA® 3Dx, Helsinki, Finland), with 4-10 mA and 60-90 kV, 18- 34 seconds of exposure time, and focal spot 0.5 mm. The acquired data from the X-ray machine were exported using a specific type of file (Digital Imaging and Communication in Medicine (DICOM)). (DICOM) formatted images were created from axial slices 0.5 mm in thickness. Thereby generated data was extracted and further processed with the help of biomedical

image processing software, for image segmentation purposes.

- 3D Volumetric Analysis from CBCT Data

This study compares Mimics and Invesalious which were compatible with the Windows operating system. Segmentations were performed according to each software manufacturer's recommendations and using the interactive threshold technique. This means that the operator selected the best threshold interval for visualizing the entirety of the anatomic boundaries of the cystic lesion. To investigate the reliability of the employed volume calculation procedure, 5 randomly selected patients were measured twice by 3 investigators to analyze inter-observer reliability. All readers were blinded to each other's results. **The sample was grouped into 3 categories, according to the cystic lesion' estimated volume and the treatment plane, into small, medium and large cyst.**

STATISTICAL ANALYSIS

Statistical analysis was performed with IBM SPSS Statistics for Windows, Version 23.0. Armonk, NY: IBM Corp. Numerical data were explored for normality by checking the distribution of data and using tests of normality (Kolmogorov-Smirnov and Shapiro-Wilk tests). All data showed non-normal (non-parametric) distribution. Data were presented as median, range, mean, and standard deviation (SD) values. The inter-examiner agreement was assessed using Cronbach's alpha reliability coefficient and Intra-Class Correlation Coefficient (ICC). Closer values of these coefficients to one indicate better inter-observer agreement.

Qualitative data were presented as frequencies and percentages. The significance level was set at $P \leq 0.05$. The analysis of the data was carried out using the IBM SPSS version 25 statistical package software and Med-calc version 12. The normality of the data was tested using the Shapiro-Wilk test. Data were expressed as mean \pm SD and by median (IQR) for non-parametric quantitative data. Analyses were done between the two techniques in each group using the Wilcoxon signed rank test. Correlation between two techniques in each group was done using **Pearson's correlation** followed by **simple linear regression analysis**. Assessment of reliability between the two techniques was done using **Cronbach's alpha** and **interclass correlation**. The agreement between the two techniques in each group using the **Bland-**

Altman plot. The **p value less than 0.05** was considered statistically significant.

RESULTS

1- The present study was conducted on 36 patients: 21 males (53.1%) and 15 females (46.9%). The most common type of cyst was radicular cyst (36.7%) followed by odontogenic keratocyst (20.4%). Almost half of the cysts (51%) were found in the lower arch and 49% were in the upper arch. The 2- software showed very good inter-examiner agreement. The highest inter-examiner agreement for volume measurement was found with Invesalius (Cronbach's alpha = 0.992), followed by Mimics (Cronbach's alpha = 0.989). Pairwise comparisons revealed that there was no statistically significant difference between Mimics and Invesalius software (**Figure 1**).

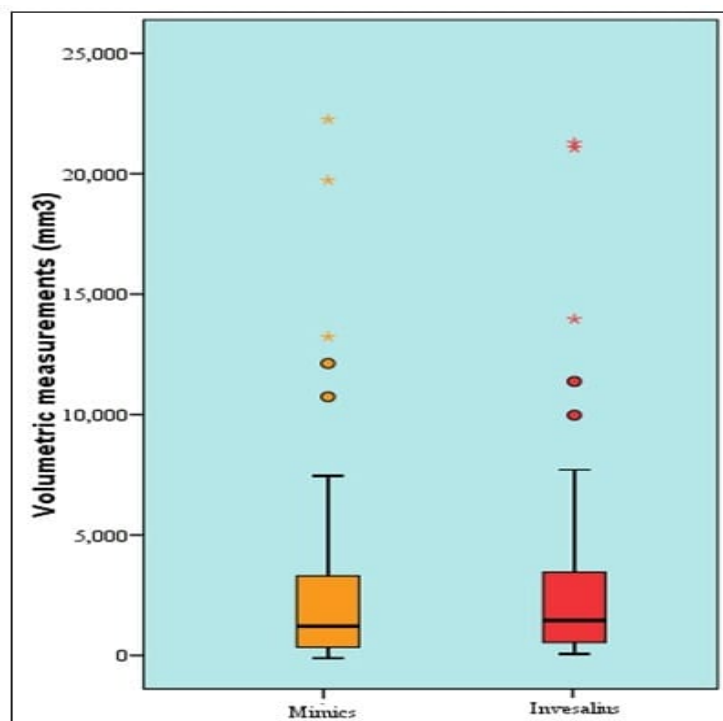


Figure (1). Box plot representing median and range values for volumetric measurements Mimics and Invesalius different software (Stars and circles represent outliers)

2- Results related to groups of cysts size
As regards the Bland Altman plot: The differences between the manual segmentation method and semiautomated segmentation method are plotted against the averages of the two measurements (X-axis). The *green lines* illustrate the mean difference between both measurements, the *red lines* illustrate the 95% limits of agreement. The *dashed blue lines* represent the linear regression line with the difference as the dependent variable

(criterion) and the mean as the independent variable (predictor). Simple linear regression analyses for volume showed no statistically relevant p-value (0.051 and 0.087) for small and large-sized lesions respectively, therefore this parameter does not exhibit proportional bias. While showed a statistically relevant p-value (0.019) for medium-sized lesions, therefore this parameter exhibited proportional bias.

Pairwise comparisons between the two methods in different sized lesions

Group		Manual segmentation	Semiautomated segmentation	P value
Small sized (n=17)	Mean ± SD Median / IQR	444.6±240.8 383.9/ (227.9-628.9)	409.5±224.2 394.5/ (211-577.9)	0.001*
Medium sized (n=9)	Mean ± SD Median / IQR	1442.6±228.6 1477.3/ (1237-1549.2)	1393.7±296.2 1336.1/ (1142.1-1530.1)	<i>0.110</i>
Large sized (n=10)	Mean ± SD Median / IQR	8544.3±5799.6 6326.4/ (4316.9-12076.2)	8766.6±6119.8 6257.6/ (4371.4-12615.7)	<i>0.575</i>

*Wilcoxon signed rank test; *: Significant level at P value < 0.0*

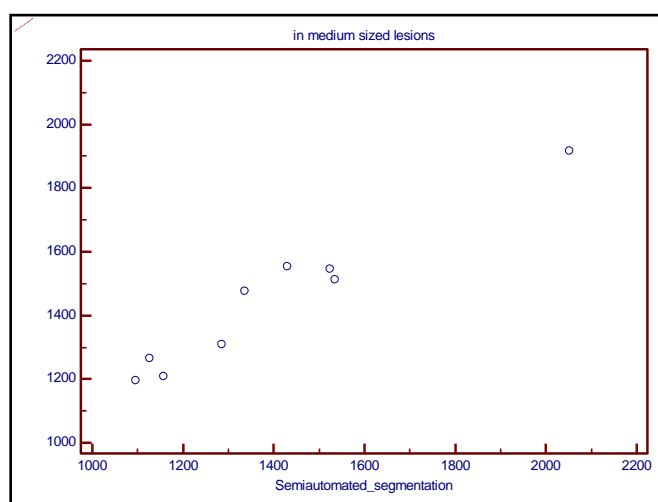
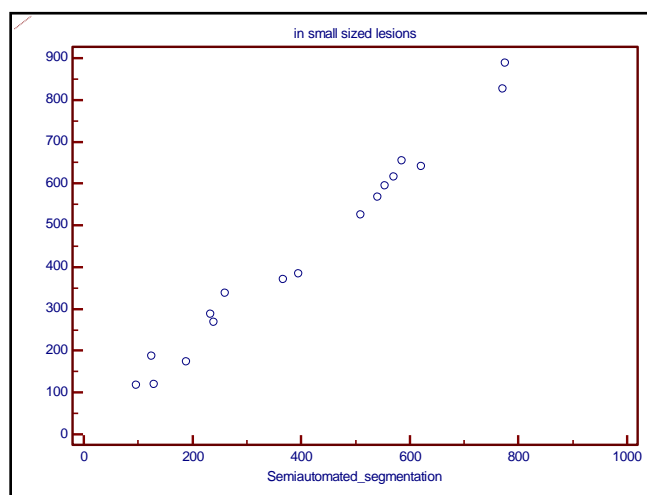
Correlation between the two methods in different sized lesions

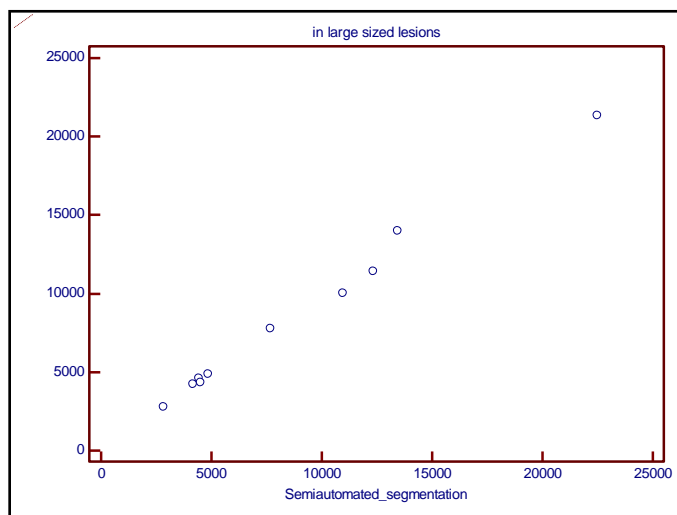
	Manual segmentation vs Semiautomated segmentation	
	R	P value
Small sized (n=17)	0.991	<0.001*
Medium sized (n=9)	0.974	<0.001*
Large sized (n=10)	0.997	<0.001*

Simple linear regression analysis between the two methods in different sized lesions (Manual segmentation is the dependent variable)

Semiautomated segmentation	Constant	B	P value	R	R ²
Small sized	8.434	1.065	<0.001*	<i>0.991</i>	<i>0.983</i>

Medium sized	395.155	0.752	<0.001*	0.974	0.948
Large sized	261.829	0.945	<0.001*	0.997	0.994



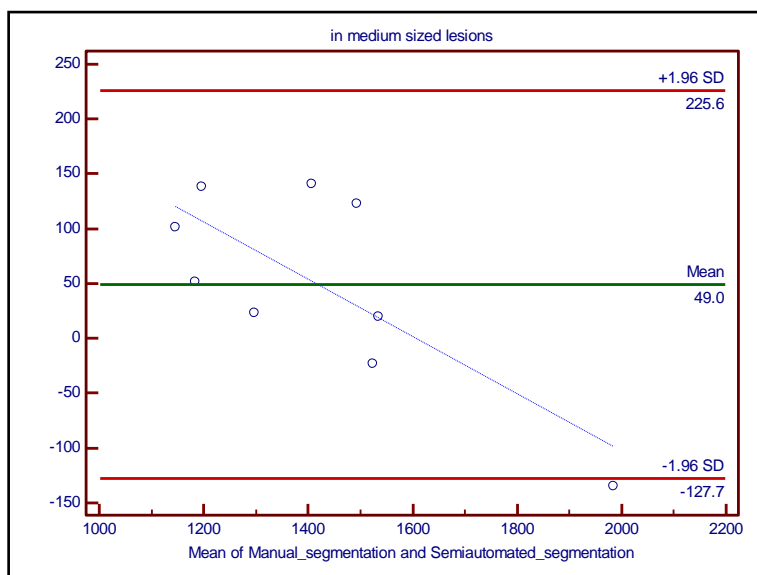
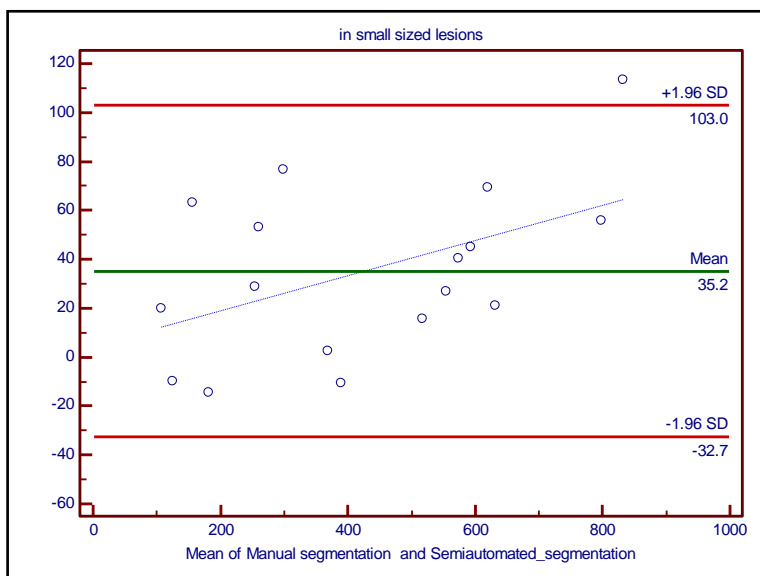


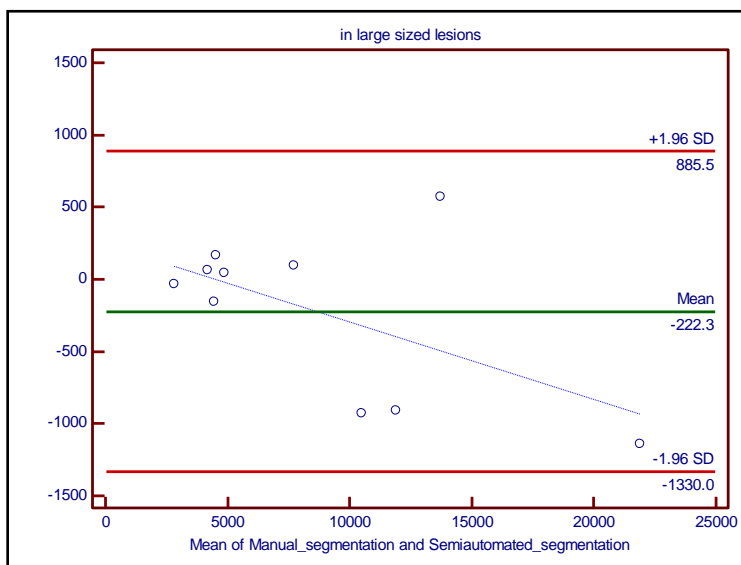
Reliability and interclass correlation between the two methods in different-sized lesions.

	Manual segmentation vs Semiautomated segmentation		
	Cronbach's alpha	ICC	P value
Small sized (n=17)	0.994	0.989	<0.001*
Medium sized (n=9)	0.970	0.942	<0.001*
Large sized (n=10)	0.998	0.996	<0.001*

Bland-Altman plot analysis between the two methods in different-sized lesions

Manual segmentation vs Semiautomated segmentation	Bland-Altman Plot			
	Bias	Limits of agreement		P value (linear regression)
		Lower	Upper	
Small sized (n=17)	35.16	-32.73	103.05	0.051
Medium sized (n=9)	48.95	-127.66	225.57	0.019*
Large sized (n=10)	-222.2	-1330	885.5	0.087





DISCUSSION

Cone Beam Computerized Tomography (CBCT) is a volumetric imaging modality used in the oral and maxillofacial field for diagnosis and treatment planning of both dental and non-dental pathologies including bone lesions. Bone lesions consist of cysts, benign and malignant tumors that may be clinically apparent or may be found incidentally on CBCT.¹¹

In the current study, the DICOM data from CBCT scans were segmented using MIMICS, and InVesalius software. MIMICS software allows semiautomatic segmentation and interpolation between slices and detects the margins for saving time. InVesalius software provided manual segmentation and was included due to its easy availability for everybody on a free open-source basis. As in this study, many studies that evaluated the accuracy of different segmentation procedures have used manual segmentation as the gold standard.¹²⁻¹⁴

In this study, segmentation procedures were based on image thresholding. Since the

segmentation process and the volume measurements are carried out in ideal conditions, the variability among the measurements may be attributed to the segmentation method itself and the threshold selection methods; semi-automatically using MIMICS and manually.

Concerning the operator-dependent reliability, manual and semi-automatic segmentation showed high interexaminer agreement according to the ICC values and to the small volumetric differences found between the three recordings. **Weissheimer et al**¹⁵ also compared the precision and accuracy of different imaging software programs including MIMICS and concluded that threshold adjustment is solely dependent on the operator; thus, checking the integrity of the segmented object on 3 spatial planes is crucial.

Simple linear regression analyses for volume showed no statistically relevant p-value (0.051) for small and large-sized lesions respectively. While showed a statistically relevant p-value (0.019) for medium-sized

lesions. This can be explained by **Vallaey K et al.**¹⁴ who concluded that cyst variability and the frequent absence of a strong grey gradient near their boundaries make the segmentation step difficult, which leads to an overextension of the segmentation beyond the limits of the lesion with the semi-automatic procedure. This leads to underestimation or overestimation of size. Even when utilizing the manual procedure, it is hard to segment accurately when boundaries are not sufficiently dense, robust, or discriminating.

References

1. Qazi AA, Pekar V, Kim J, Xie J, Breen SL, Jaffray DA: Auto-segmentation of normal and target structures in head and neck CT images: a feature driven model-based approach. *Med Phys* 2011, 38(11):6160–6170.
2. **Yanık S, Polat ME.** Planning of Large Odontogenic Cysts Treatment Using Panoramic and CBCT Images. *Middle Black Sea Journal of Health Science*. 2020; 6(1):45-53.
3. **Kwon YJ, Ko KS, So BK, Kim DH, Jang HS, Kim SH, Lee ES, Lim HK.** Effect of Decompression on Jaw Cystic Lesions Based on Three-Dimensional Volumetric Analysis. *Medicina (Kaunas)*. 2020; 56(11):602.
4. **Suter VG, Warnakulasuriya S, Reichart PA, Bornstein MM.** Radiographic volume analysis as a novel tool to determine nasopalatine duct cyst dimensions and its association with presenting symptoms and postoperative complications. *Clin Oral Investig*. 2015;19(7):1611-8.
5. **Kauke M, Safi AF, Grandoch A, Nickenig HJ, Zöller J, Kreppel M.** Image segmentation-based volume approximation-volume as a factor in the clinical management of osteolytic jaw lesions. *Dentomaxillofac Radiol*. 2019;48(1):20180113.
6. **Berretta LM, Melo G, Mello FW, Lizio G, Rivero ERC.** Effectiveness of marsupialisation and decompression on the reduction of cystic jaw lesions: a systematic review. *Br J Oral Maxillofac Surg*. 2021;59(10): E17-E42.
7. **Stoetzer M, Nickel F, Rana M, Lemound J, Wenzel D, von See C, Gellrich NC.** Advances in assessing the volume of odontogenic cysts and tumors in the mandible: a retrospective clinical trial. *Head Face Med*. 2013 Apr 20;9:14.
8. **Karthika R, Banumathi A, Sangavi G, Sheik dawood M.** A Novel Region Based Thresholding for Dental Cyst Extraction in Digital Dental X-Ray Images. S. Smys, Abdullah M. Iliyasu, Robert Bestak, Fuqian Shi (Ed). In: *New Trends in Computational Vision and Bio-inspired Computing, Selected works presented at the ICCVBIC 2018, Coimbatore, India*. Springer, 2020, pp 1633:1640.
9. **Safi A, Grandoch A, Dreiseidler T, Nickenig H, Zöller J, Kreppel M.** Can cyst volume be used to stratify risk of complications following cyst defect reconstruction with iliac crest graft? *Journal of Cranio-Maxillofacial Surgery*. 2017;45(8):1165-1169
10. **Haque I R I, Neubert J.** Deep learning approaches to biomedical image

- segmentation. *Informatics in Medicine Unlocked*, 2020,18,100297
11. **Yeshua T, Ladyzhensky S, Abu-Nasser A, Abdalla-Aslan R, Boharon T, Itzhak-Pur et al.** Deep learning algorithm for the detection and 3D segmentation of maxillofacial bone lesions in CBCT. *Research Square* 2022; 1-16
 12. **Forst D, Nijjar S, Flores-Mir C, Carey J, Secanell M, Lagravere M.** Comparison of in vivo 3D cone-beam computed tomography tooth volume measurement protocols. *Prog Orthod* 2014; 15: 69.
 13. **Rana M, Modrow D, Keuchel J, Chui C, Rana M, Wagner M, et al.** Development and evaluation of an automatic tumor segmentation tool: a comparison between automatic, semiautomatic and manual segmentation of mandibular odontogenic cysts and tumors. *J Craniomaxillofac Surg* 2015; 43: 355-9.
 14. **Vallaey K, Kacem A, Legoux H, Le Tenier M, Hamitouche C, Arbab-Chirani R.** 3D dento-maxillary osteolytic lesion and active contour segmentation pilot study in CBCT: semi-automatic vs manual methods. *Dentomaxillofac Radiol* 2015; 44: 20150079
 15. **Weissheimer A, Menezes LM, Sameshima GT, Enciso R, Pham J, Grauer D.** Imaging software accuracy for 3-dimensional analysis of the upper airway. *Am J Orthod Dentofacial Orthop* 2012;142: 801-13