



## **Histomorphological and immunohistochemical study on lung carcinoma**

**Dr. Tejasvini Chauhan** Junior Resident, Department of Pathology, School of Medical Sciences and Research, Sharda Hospital, Greater Noida, Uttar Pradesh, India

**Dr. Jyoti Mishra** Professor, Department of Pathology, School of Medical Sciences and Research, Sharda Hospital, Greater Noida, Uttar Pradesh, India

**Dr. Salony Mittal**, Associate Professor, Department of Pathology, School of Medical Sciences and Research, Sharda Hospital, Greater Noida, Uttar Pradesh, India

**Dr. Devendra Kumar Singh**, Professor, Department of Pulmonary Medicine, School of Medical Sciences and Research, Sharda Hospital, Greater Noida, Uttar Pradesh, India. **Email:** [dr.deva29@gmail.com](mailto:dr.deva29@gmail.com)

**Dr. Vatsala Gupta**, Assistant Professor, Department of Pathology, School of Medical Sciences and Research, Sharda Hospital, Greater Noida, Uttar Pradesh, India

**Dr. Prachi Saxena**, Senior Resident, Department of Pathology, School of Medical Sciences and Research, Sharda Hospital, Greater Noida, Uttar Pradesh, India

Corresponding Author:

Dr. Salony Mittal

---

### **Abstract:**

Accurate subtyping of lung carcinomas requires the use of immunohistochemistry along with histopathology in small biopsies. This forms the basis of targeted therapies. In this study, we classified lung biopsies morphologically and immunohistochemical. **Materials and methods:** All lung biopsies received in 10 % NBF from January 2017 to May 2022 in the Department of Pathology, School of Medicine and Research, Sharda University, Greater Noida were studied. Histological diagnosis was rendered on H&E. The doubtful cases were subjected to IHC p63, TTF-1, and chromogranin with positive controls. **Results:** The age of patients ranged from 32 to 82 years with male predilection. The most common symptom was cough (27.3 %), followed by hemoptysis, dyspnoea, and chest pain. Out of forty cases of lung carcinomas 20 cases of NSCLC (out of which 13 were of AC and 7 were SCC). Eight cases of small cell carcinoma. Twelve cases were of poorly differentiated carcinomas. Twelve cases of poorly differentiated carcinoma were subjected to immunohistochemistry (TTF-1, p63 and chromogranin). TTF-1 positive 5 cases were further classified as AC, p63 positive 3 cases as SCC and 3 cases expressed chromogranin A positivity as small cell lung carcinoma. One case did not express positivity for any immunohistochemical marker and was labelled as undifferentiated carcinoma. **Conclusion:** The present study gives the glimpse of the histological subtypes of lung carcinoma in the Delhi-NCR region over the period of past 5 years diagnosed on histomorphology and immunohistochemistry.

**Keywords:** Lung Carcinoma, Immunohistochemistry, Squamous Cell Carcinoma, Adenocarcinoma, Small Cell

---

**Introduction:** Lung carcinomas are a leading cause of morbidity and mortality worldwide, claiming more lives than any other cancer.<sup>[1]</sup> There are 1.61 million newly diagnosed cases of lung carcinoma each year and 1.38 million deaths worldwide. Each year, roughly 63,000 new cases of lung cancer are recorded in India itself.<sup>[2]</sup>

Lung carcinomas are classified into two broad categories on the basis of morphology- small cell lung cancer (SCLC) and non-small cell lung cancer (NSCLC). NSCLC constitutes upto 85% of lung malignancies, with adenocarcinoma, the most frequent subtype.<sup>[3]</sup> Lung carcinoma is mainly classified on morphology on conventional hematoxylin and eosin stain. The tumors with diffuse sheets of small round cells with salt and pepper chromatin are classified as small cell carcinoma of lung. The keratinization of cells and/or intercellular-bridges hint towards the diagnosis of squamous cell carcinoma (SCC) while the glandular differentiation and/or mucin production points to adenocarcinoma (AC). Carcinomas with absence of both keratinization as well as glandular elements are placed morphologically under the category of poorly differentiated carcinomas.

Adenocarcinomas have a poorer prognosis, compared to squamous cell carcinoma with a 5-year-survival rate of fewer than 15%.<sup>[4]</sup> Accurate histopathological subtyping of lung tumors is essential for targeted therapeutic agents.<sup>[5,6]</sup> Majority of squamous cell carcinoma show absence of unequivocal keratinization. These subtypes of non-keratinizing SCC such as of basaloid, papillary type are difficult to diagnose on morphology alone.

Several challenges are faced by the reporting histopathologist. Many adenocarcinomas also show squamous morphology.<sup>[8]</sup> Most often small biopsies are received in cases of lung lesion including neoplasms. Moreover, the lung biopsies maybe insufficient for diagnosis and at times may show extensive crushing artifact. These small biopsy samples are small tumor fractions and may not reflect the full lesion, making proper subtyping on histomorphology problematic.<sup>[7,8]</sup> Therefore, in 2011 IASLC, ATS and ERS multidisciplinary update collectively incorporated IHC in World Health Organization (WHO) 2015 criteria.<sup>[9]</sup>

Morphologic assessment of tiny biopsy or cytology specimens determines the predominant form of lung cancer, which is AC or SCC. When the morphology is inconclusive or poorly differentiated, the use of histochemical stains allows for the differentiation of cases into SCLC and NSCLC.

In the present study, we utilized p63, TTF-1 and chromogranin to classify squamous cell carcinoma (SCC), lung adenocarcinoma (ADC) and small cell carcinoma of the lung.

### **Materials and Methods:**

**Study design:** Prospective and retrospective cohort study

**Sample Size:** 40 cases

**Method of recruitment:** Histopathologically diagnosed lung carcinoma cases from June 2017- December 2023, in the Department of Pathology, SMS&R Greater Noida were included in the study. These included both retrospective and prospective cases.

### **Inclusion criteria:**

Histologically diagnosed lung carcinoma cases from June 2017- December 2022 (6 years)

### **Exclusion criteria:**

- i. Specimens with benign tumour or inflammatory diagnosis.
- ii. Patients who were already on chemotherapy.
- iii. Specimens that were improperly fixed or with more necrotic tissue.
- iv. Inadequate samples.

The detailed history including the age, occupation, socioeconomic status, diet, history of smoking was taken. CT scan was done in each case. A biopsy was taken in each case and submitted in histopathology section in 10% formalin. After proper specimen description, the entire tissue was submitted for routine histopathological processing. The AC and SCC cases were well distinguished with easily appreciated glandular or squamous differentiation. The tumors were classified as SCC if they showed intercellular-bridges or keratin while as AC if had glandular formation or production of mucin. In poorly differentiated lung carcinomas on H&E the accurate histopathological typing of tumours were done using IHC. Immunohistochemical staining was performed with markers TTF-1, p63 and chromogranin on lung biopsies which could not be differentiated solely on the basis of morphology. (**Table No.1**)

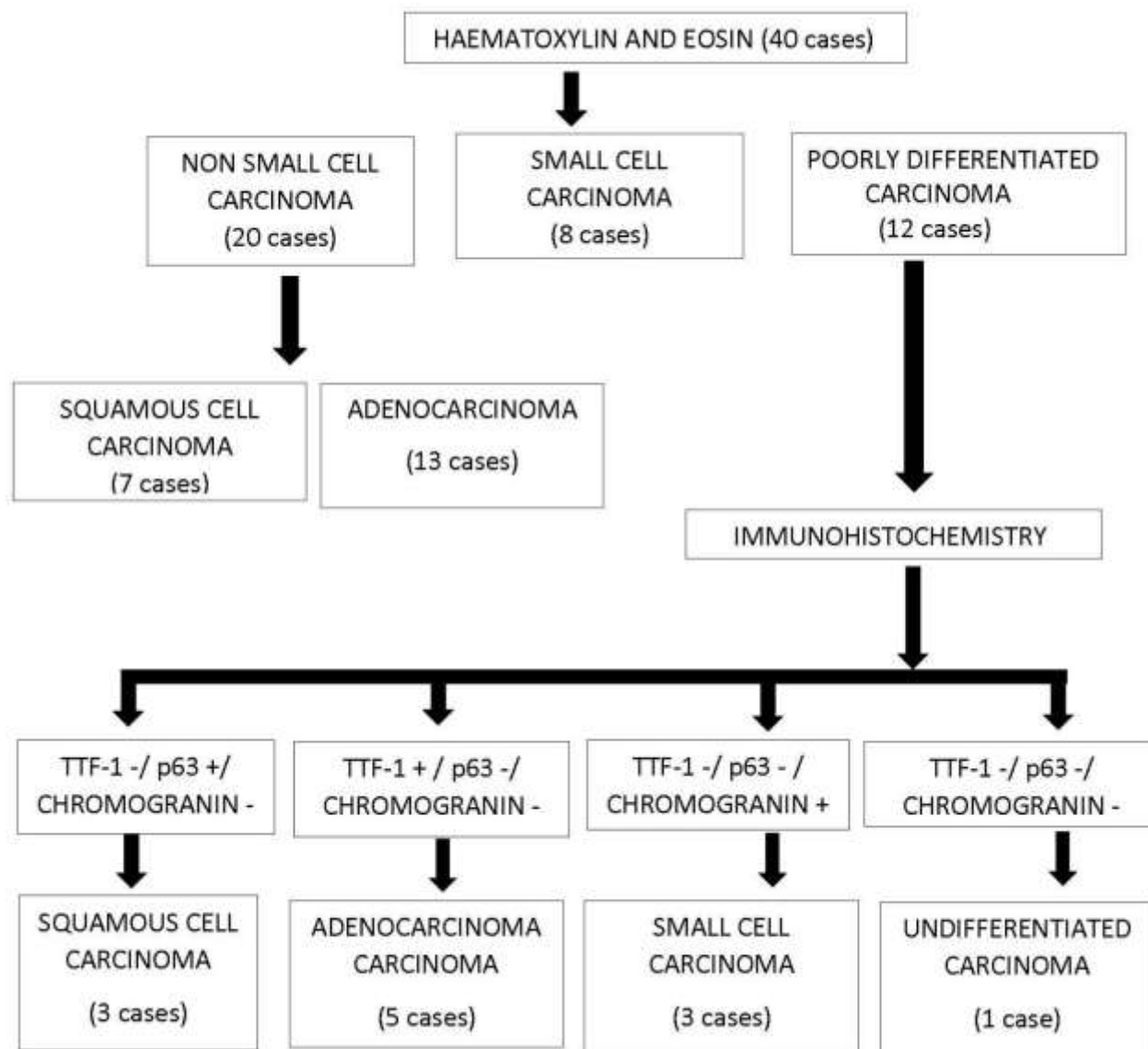
**Scoring for TTF-1, p63 and chromogranin:** Scoring of TTF-1, p63 and chromogranin expression was done semi-quantitatively. <sup>[10]</sup> Based on the proportion of cells with nuclear TTF-1 and p63 staining and chromogranin staining in the cytoplasm, 0% weakly positive or negative, 10% or less cells positive +, 10% to 50% positive ++ and >50% positive +++.

Based on the staining's severity (rated + to +++), weak (1+, less than normal cells), moderate (2+, equal to normal cells), and strong (3+, more than normal cells).

The approval from institutional ethical committee has been taken for this study. Complete confidentiality regarding the subject information was maintained through all the phases of the study.

## **Results**

The age of the cases ranged from 32 to 82 years with mean + S.D =  $61.2 \pm 14.5$  years. Majority of the patients were of more than 60 years (26 cases; 66.7%) followed by 12 cases (30%) in the age group of 40-60 years. Only one patient of 32 years was noted in the age group of class interval between 20-40 years. (**Table No.2**) Out of 30 cases there were 39 males and 1 female. Majority of the patients had a habit of cigarette smoking. Out of 40 cases, 37 patients (90 %) gave history of cigarette smoking of which two had left smoking in the last two years. Three (30 %) patients did not smoke at all. Most common symptom was cough (27, 3.3 %) followed by dyspnea in (15). Hemoptysis was reported in only 8 cases (26.7%) followed by weight loss (7%). Chest pain was the chief complaint in one case. The right lung was involved in 19 cases (63.3%) and left lung in remaining 11 cases (37%). Out of 40 cases, 28 (73.3%) were centrally located masses while the remaining 12 (26.7%) were peripherally situated lesions. Ten tumors showed central necrosis and cavitation. Four cases showed solitary pulmonary nodule. In our study the biopsies were obtained by two procedures namely, transbronchial lung biopsy and CT-guided core needle biopsy. In 39 cases bronchoscopic biopsy (96.7%) while in one case (3.3%) core needle biopsy specimen was submitted. Out of forty cases of lung carcinomas 20 cases of NSCLC (out of which 13 were of AC and 7 were SCC). (**Figure 1 a, b and Figure 2 a, b**) Eight cases (20%) of SCLC. (**Figure 3 a, b**) Twelve cases (26.6%) were of poorly differentiated carcinomas. Adenocarcinoma comprised of papillary (23%), acinar (23%), mixed (66%), lepidic and solid pattern. (**Table No.3, Figure 2 a, b**) Twelve cases of poorly differentiated carcinoma were subjected to immunohistochemistry (TTF-1, p63 and chromogranin). TTF-1 positive 5 cases were further classified as AC, p63 positive 3 cases as SCC and 3 cases expressed chromogranin A positivity as small cell lung carcinoma. One case did not express positivity for any immunohistochemical marker and was labelled as undifferentiated carcinoma. (**Figure 4 a, b and Figure 5 a, b**)



**Table No. 1: Panel used in the present study and criteria for evaluation of immunostaining**

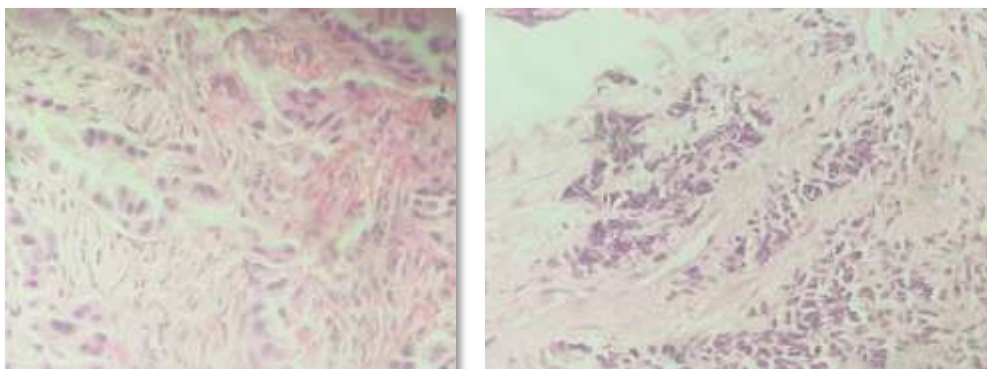
S.No.	Antigen	Clone	Supplier	Dilution	Criteria for positivity
1.	p63	DAK-p63	Dako	Pre-diluted	Distinct nuclear staining of $\geq 50\%$ cells
2.	TTF-1	8G7G3/1	Dako	Pre diluted	Distinct nuclear staining of $> 5\%$ cells
3.	Chromogranin A	DAK-A3	Dako	Pre diluted	Distinct, intense cytoplasmic staining of $> 5\%$ cells

**Table No. 2: Age and gender wise distribution of cases of Lung Carcinoma**

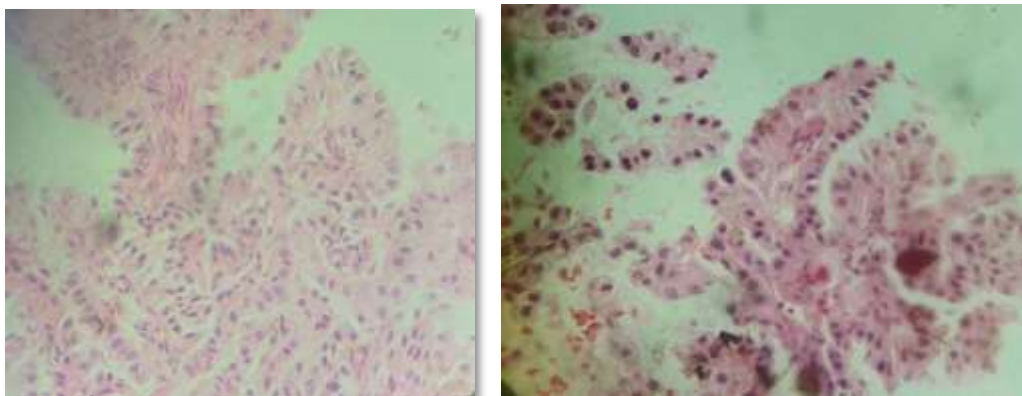
Age group	Male	Female	Total	Percentage (%)
20-40 years	1	-	1	3.3
40-60 years	12	-	12	30
> 60 years	26	1	27	66.7
<b>Total</b>	39	1	40	100

**Table No. 3: Histological Subtyping of Adenocarcinoma Cases (n=13) according to morphology on H&E sections**

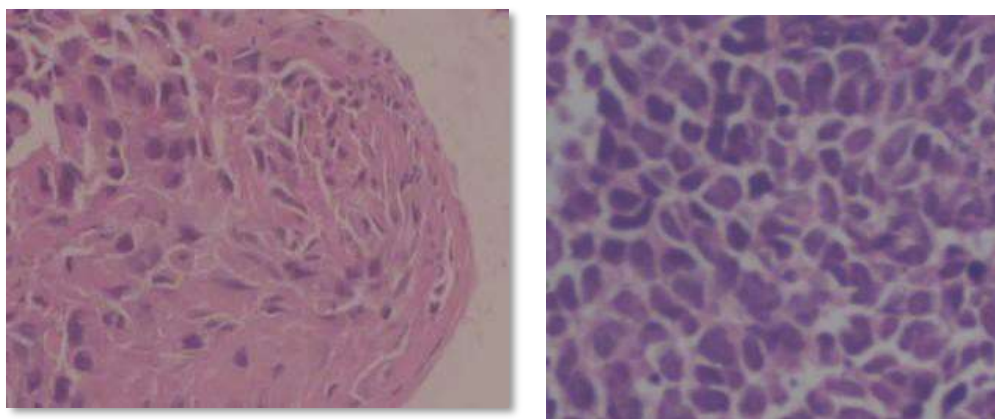
<b>Histological Subtype</b>	<b>Cases (n=09)</b>	<b>Percentage%</b>
<b>Papillary</b>	03	23
<b>Acinar</b>	0	23
<b>Lepidic</b>	01	11
<b>Solid</b>	01	11
<b>Mixed</b>	06	66
<b>Total</b>	13	100



**Figure No. 1a and b:** Lung biopsy of adenocarcinoma form tumour cells showing “GLANDULAR PATTERN”. (H&E; 40X)

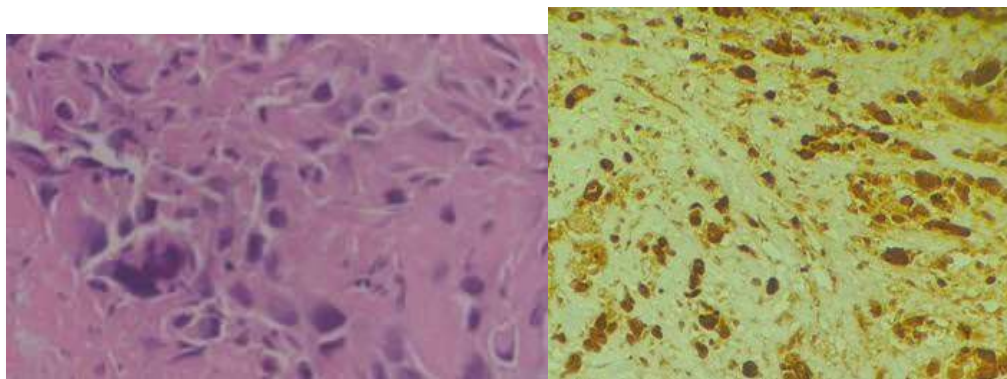


**Figure No. 2a and b:** Lung biopsy of adenocarcinoma with tumour cells disposed in papillae and micro papillae pattern exhibiting “PAPILLARY PATTERN” (H&E; 40X)

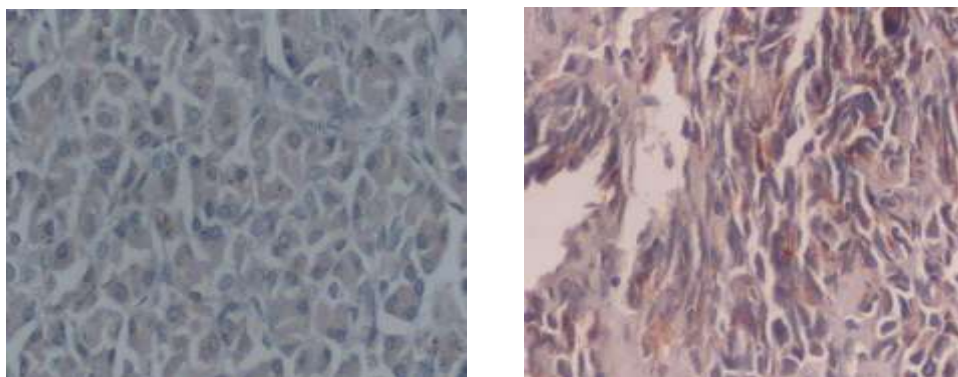


**Figure No. 3a:** Lung biopsy of squamous cell carcinoma with clusters of polygonal hyperchromatic cells. **b** Lung biopsy of small cell carcinoma with sheets of small cells with scant cytoplasm and nuclear moulding (H&E; 40X)





**Figure No.4:** a. Lung biopsy of poorly differentiated carcinoma showing bizzare cells and desmoplastic stroma (H&E; 40X) Intensity b. Lung biopsy of adenocarcinoma showing TTF-1 positivity (H&E; 40X -Strong (3+) Intensity Nuclear Positivity)



**Figure No.5 :** a. Lung biopsy of small cell carcinoma showing chromogranin positivity (H&E; 40X Strong (3+) Intensity Cytoplasmic Positivity) b. Lung biopsy of squamous cell carcinoma showing p63 positivity (p63; 100X Moderate (2+) Intensity Nuclear Positivity)

**Discussion:** Lung cancers are broadly sub classified into NSCLC and SCLCs. As per WHO 2015 classification, the subtyping of NSCLC is essential owing to therapeutic implications. Most of the lung biopsies are obtained by the aid of bronchoscopy and biopsies are taken by via transbronchial /transthoracic route. Video-assisted thoracic surgery (VATS), CT-guided percutaneous route are the newer modalities to retrieve lung biopsies. In our study out of forty cases of lung carcinoma, in 39 cases bronchoscopic biopsy was obtained while in one case core needle biopsy was obtained. Difficulty in subtyping on morphologic grounds is usually due to insufficient material or scant tumour area or unequivocal morphology. *Acharya KV et al* in his study reported that bronchoscopic procedures had a good accuracy of 81.25% in diagnosis of lung malignancies in central tumours

and also in peripheral tumours that are not access able. [11] *Andolfi M et al* suggests tissue biopsy is the gold standard investigation for premalignant and malignant lung lesions. [12] Further this group also considers bronchoscopy as the safest and most accurate tools to evaluate both central and distal airway lesions. *Parigi et al* reported percutaneous core needle biopsy of lung (PCNBL) is of more use than bronchoscopic biopsies to get samples for peripheral lung lesions including non-malignant lesions. [13]

Many studies state that the degree of distortion often noticed in the small biopsies is a major contributing factor to the lack of specificity in the labelling of lung tumors on histomorphology. We also undoubtedly found crushing artefacts in the small biopsies received by us as a limiting factor for making an accurate diagnosis on the histological sections.

WHO classification of lung tumors the criteria for identifying the poorly differentiated and undifferentiated carcinomas are not defined. This creates lots of ambiguity among the different pathologists group making the imprecise designations for such cases. The pathologists are honestly unable to classify these cases into any group on the basis of histomorphology. In our study, we labelled the cases in which were lacking specific diagnostic criteria on histomorphology as poorly differentiated carcinomas. There were 12 cases of poorly differentiated carcinoma in our study.

In our study out of 40 cases there were 39 males and 1 female. The males outnumbered the females. Our finding was in concordance with the findings of *Albasri et al*, *Alamoudi et al*, *Bhatti et al* who also reported male preponderance. [14, 15,16] This trend presently exists in the developing countries. However, in the developed countries, the rate of incidence in males and females has started converging.

In our study age of the cases ranged from 32 to 82 years with mean + S.D =  $61.2 \pm 14.5$  years. Majority of the patients were of more than 60 years (26 cases; 66.7%) followed by 12 cases (30%) in the age group of 40-60 years. Only one patient of 32 years was noted in the age group of class interval between 20-40 years. *Albasri et al* reported the age range of 6- 97 years with mean of  $60.6 \pm 14.7$  years in their study cohort. [14] The age group in all the studies were in concordance with the present study.

In present study, majority of the patients had a habit of cigarette smoking. Twenty-seven (90%) had habit of cigarette smoking of which two had left smoking in last two years. *Song MA et al* suggested smoking as a risk factor in 80% to 90% of lung cancer diagnoses and 5-year survival is 18%, highlighting the importance of prevention. [17]

In the present study AC formed the maximum number of the cases (13 out of 40 cases, 32.5%) followed by SCC (7 out of 40 cases, 17.5 %) and the SCLC (8 out of 40 cases, 20%). There were 12

cases (30%) of poorly differentiated carcinoma in our study. The tumors were classified into SCLC and NSCLC on the basis of histomorphology on hematoxylin and eosin sections. It has been reported by *Travis WD et al*, *Gurda GT et al* in their independent studies that usually most NSCLC can be subtyped into AC and SCC on biopsies without the use of any ancillary tests (special stain or IHC). [18, 19] Similarly, in the present study we initially classified tumors on histomorphology. The tumors with intracellular bridges and evidence of keratinization were classified as SCC. The tumors showing glandular differentiation on morphology were classified as AC. The malignant neoplasm showing small size of tumor cells with finely granular cytoplasm and scant chromatin, exhibiting nuclear moulding were typified as small cell carcinomas. The tumors which did not clearly show any above of the characteristic features were classified as poorly differentiated carcinomas. This was attributed to unequivocal morphology, scant tumour and inadequate sampling. Such cases were then subjected to IHC. Twelve cases of poorly differentiated carcinoma were subjected to immunohistochemistry (TTF-1, p63 and chromogranin). TTF-1 positive 5 cases were further classified as AC, p63 positive 3 cases as SCC and 3 cases expressed chromogranin A positivity as small cell lung carcinoma. One case could not be diagnosed both on morphology and the IHC panel used. This was concordant with the results of *Albasri A et al* who also found AC was the most common primary tumor. [14] However, this was discordant to study by *N.H.C Au et al* who reported SCC as the commonest tumor. In our study a two-step approach was followed to diagnose small lung biopsies. [15] The studies by *Travis WD et al*, *Gurda GT et al*, *Kadota K et al*, *Bhatti V et al*, *Mukhopadhyay et al*, *Shankar Shanmughapriya et al* etc. [19, 20, 16, 21, 22] advocated the judicious use of immunohistochemical markers with the latter being reserved for the poorly differentiated cases. The approach was in concordance to our study. On the other hand, unlike the present study, many independent studies by *Bernadi FDC et al*, *Koh Jaenoon et al*, [23, 24] carried out immunohistochemistry on all the cases of lung carcinomas included in their respective studies.

In the present study, we evaluated 3 monoclonal antibodies (TTF-1, p63, chromogranin A) in poorly differentiated carcinomas. Many studies including *Thunnissen E*, *Travis WD et al*, *Gurda GT et al*, *Kadota K et al*, *Bhatti V et al*, *Mukhopadhyay et al*, *Shankar Shanmughapriya et al* [25,18,19, 20, 16, 21, 22 ] in their respective literatures, emphasized that TTF 1 and Napsin A are the reliable markers for adenocarcinomas of lung and reveal positive results in 85% of AC. Expression of either of these two markers is considered de facto evidence of AC or adenocarcinoma differentiation in NSCLC if other tumours that also commonly express these markers (including SCLC and LCNEC) can be excluded. IHC markers commonly expressed in SCC include p40, CK5/6, CK5, and p63. *NHU Au et al* carried out study on tissue microarray and found out of 408 cases consisting 123 SCC, 93 AC, 68 classic carcinoids and 14 cases of SCLC. 96.9 % cases of SCC were positive for p63. [26] The study by *Bhatti V et al* utilized the panel of CK7, CK 20, CK 5/6, p63, TTF-1, Napsin A, Synaptophysin, chromogranin A, neuron specific enolase, CD 56 and CDX2. [16] The authors included only primary lung tumours in their study

and metastatic cases were not included. This was concordant with our study too where only primary lung cancers were considered. *M Albasri et al* reported AC as the commonest pathological type (47.8%), followed by SCC (25.3%), neuroendocrine tumor (8.7%) and metastatic carcinoma (8%). IHC was not used as adjunct in this study. [14] *Conde et al* in their independent study validated the expression of p63 on tissue microarray; for identification of SCC and found highly significant positivity in SCC in comparison to adenocarcinoma. [27] *Reeve et al* evaluated neuron specific enolase (NSE) in the cases of SCLC and concluded that NSE immunoreactivity per se is an unreliable marker for the SCLC phenotype. [28] In the present study Chromogranin A was used to confirm SCLC. *Varma A et al* carried on IHC by TTF-1 and p63 for typing NSCLC and founded p63 utility in SCC and TTF-1 in all cases of adenocarcinoma. [29] This study included 16 cases of adenocarcinoma, 22 SCC and 12 cases of NSCLC-NOS. *Conde E et al* carried study on 106 patients (33 AC, 69 SCLC, 70 large cell carcinoma, 3 sarcomatoid carcinoma and used p63 for SCC of lung and concluded p63 to be useful tool in diagnosis of SCC. [27] *Reeve J et al* evaluated NSE as a marker for SCLC using a monoclonal antibody and found NSE an unreliable marker for the small cell lung carcinoma. [28] *Terry et al* assessed four IHC markers (CK7, CK 20, TTF-1, p63) on biopsy specimens and followed two step algorithms for accurate sub classification of NSLC. [30] Unlike our study, this study did not include SCLC cases while metastatic tumors were included. *Shankar Shanmugapriya et al* subtyped NSCLC based on expression of TTF-1, p63 along with the expression of EGFR in adenocarcinomas. [22] *Wu Maoxin et al* used automated staining for TTF-1 and p63 on PDSCC in formalin and alcohol fixed specimens. [31] They evaluated the usefulness of both the immunomarkers for differentiating PDSCC from SCLC. SCLC showed strong p63 positivity and TTF weak positivity or negativity.

*Koh Jaemoon et al* reported CK 7 positivity was seen in 99.1%, followed by Napsin A in 93.5 % cases followed by TTF-1 in 86.1% cases in adenocarcinoma. [25] p63 was negative in all the cases. SCC showed p40 and p63 positivity in 93.2% and 79.7 % cases respectively. TTF-1 was not expressed in any of the cases. Hence congruent to our result we selected TTF-1 and p63 markers to classify lung cancers. This study emphasizes upon the importance of morphology and immunohistochemistry for distinction of SCLC from NSCLC and further subtyping of NSCLC especially AC in order to effectively drive patients to specific molecular targeted therapy. The limitation of this study was that the resection specimens were not included in it. As small biopsies are just a fraction of large tumour masses, the correct subtyping especially of carcinomas with mixed features of AC and SCC would have been missed in our study.

**Conclusion:** The present study gives the glimpse of the histological subtypes of lung carcinoma in the Delhi-NCR region over the period of past 5 years diagnosed on histomorphology and immunohistochemistry.

**References:**

1. Ferlay J, Colombet M, Soerjomataram I, Mathers C, Parkin DM, Pineros M, Znaor A, Bray F. Estimating the global cancer incidence and mortality in 2018: GLOBOCAN sources and methods. *Int J Cancer*. 2019 Apr 15;144(8):1941-1953.
2. Barta JA, Powell CA, Wisnivesky JP. Global Epidemiology of Lung Cancer. *Ann Glob Health*. 2019;85(1):8.
3. Shankar S, Thanasekaran V, Dhanasekar T, Duvooru P. Clinicopathological and immunohistochemical profile of non-small cell lung carcinoma in a tertiary care medical centre in South India. *Lung India*. 2014 Jan;31(1):23-8.
4. De Mello RA, Marques DS, Medeiros R, Araújo AM. Epidermal growth factor receptor and K-Ras in non-small cell lung cancer-molecular pathways involved and targeted therapies. *World J Clin Oncol*. 2011 Nov 10;2(11):367-76.
5. Kobayashi S, Boggon TJ, Dayaram T, Jänne PA, Kocher O, Meyerson M, Johnson BE, Eck MJ, Tenen DG, Halmos B. EGFR mutation and resistance of non-small-cell lung cancer to gefitinib. *N Engl J Med*. 2005 Feb 24;352(8):786-92.
6. Dacic S. Molecular diagnostics of lung carcinomas. *Arch Pathol Lab Med*. 2011 May;135(5):622-9.
7. Loo PS, Thomas SC, Nicolson MC, Fyfe MN, Kerr KM. Subtyping of undifferentiated non-small cell carcinomas in bronchial biopsy specimens. *J Thorac Oncol* 2010;5:442–447.
8. Chirieac LR, Dacic S. Targeted Therapies in Lung Cancer. *Surg Pathol Clin*. 2010;3(1):71-82.
9. Jafarian AH, Gharib M, Mohammadian Roshan N, Sherafatnia S, Omidi AA, Bagheri S. The Diagnostic Value of TTF-1, P63, HMWK, CK7, and CD56 Immunostaining in the Classification of Lung Carcinoma. *Iran J Pathol*. 2017;12(3):195-201.

10. Zachara-Szczakowski S, Verdun T, Churg A. Accuracy of classifying poorly differentiated non-small cell lung carcinoma biopsies with commonly used lung carcinoma markers. *Hum Pathol.* 2015 May;46(5):776-82.
11. Acharya K V, B U, Shenoy A, Holla R. Utility of Various Bronchoscopic Modalities in Lung Cancer Diagnosis. *Asian Pac J Cancer Prev.* 2017 Jul 27;18(7):1931-1936.
12. Andolfi M, Potenza R, Capozzi R, Liparulo V, Puma F, Yasufuku K. The role of bronchoscopy in the diagnosis of early lung cancer: a review. *J Thorac Dis.* 2016 Nov;8(11):3329-3337.
13. Parigi M, Hui M, Uppin SG, Kapoor A, Kumar NN, Bhaskar K, Stalin BJ, Sadashivudu G, Paramjyothi GK. Percutaneous core needle biopsy in the diagnosis of lung lesions: An experience on 280 consecutive cases from a university hospital in southern India. *Lung India.* 2021 Jan-Feb;38(1):41-52.
14. Albasri AM. A histopathological analysis of lung cancers. An 11-year retrospective study from Al-Madinah Al-Munawwarah, Saudi Arabia. *Saudi Med J.* 2019;40(5):503-6.
15. Alamoudi OS. Lung cancer at a university hospital in Saudi Arabia: A four-year prospective study of clinical, pathological, radiological, bronchoscopic, and biochemical parameters. *Ann Thorac Med* 2010;5:30-6.
16. Bhatti V, Kwatra KS, Puri S, Calton N. Histopathological Spectrum and Immunohistochemical Profile of Lung Carcinomas: A 9-Year Study from a Tertiary Hospital in North India. *Int J Appl Basic Med Res.* 2019;9(3):169-175.
17. Song MA, Benowitz NL, Berman M, et al. Cigarette filter ventilation and its relationship to increasing rates of lung adenocarcinoma. *J Natl Cancer Inst.* 2017;109(12).
18. Travis WD, Brambilla E, Noguchi M, et al. Diagnosis of lung cancer in small biopsies and cytology: implications of the 2011 International Association for the Study of Lung Cancer/American Thoracic Society/European Respiratory Society classification. *Arch Pathol Lab Med.* 2013; 137(5):668-84.
19. Gurda GT, Zhang L, Wang Y, Chen L, Geddes S, Cho WC, Askin F, Gabrielson E, Li QK. Utility of five commonly used immunohistochemical markers TTF-1, Napsin A, CK7, CK5/6 and P63 in primary and metastatic adenocarcinoma and squamous cell carcinoma of the lung: a retrospective study of 246 fine needle aspiration cases. *Clin Transl Med.* 2015 Apr 21;4:16.

20. Kadota K, Nitadori J, Rekhman N, Jones DR, Adusumilli PS, Travis WD. Reevaluation and reclassification of resected lung carcinomas originally diagnosed as squamous cell carcinoma using immunohistochemical analysis. *Am J Surg Pathol*. 2015 Sep;39(9):1170-80.
21. Mukhopadhyay S, Katzenstein AL. Subclassification of non- small cell lung carcinomas lacking morphologic differentiation on biopsy specimen: Utility of an immunohistochemical panel containing TTF-1, napsin A, p63, and CK5/6. *Am J Surg Pathol* 2011;35:15-25.
22. Shankar S, Thanasekaran V, Dhanasekar T, Duvooru P. Clinicopathological and immunohistochemical profile of non-small cell lung carcinoma in a tertiary care medical centre in South India. *Lung India*. 2014 Jan;31(1):23-8.
23. Bernardi FDC, Bernardi MDC, Takagaki T, Siqueira SAC, Dolhnikoff M. Lung cancer biopsy: Can diagnosis be changed after immunohistochemistry when the H&E-Based morphology corresponds to a specific tumor subtype? *Clinics (Sao Paulo)*. 2018 Oct 29;73:e361.
24. Koh J, Go H, Kim MY, Jeon YK, Chung JH, Chung DH. A comprehensive immunohistochemistry algorithm for the histological subtyping of small biopsies obtained from non-small cell lung cancers. *Histopathology*. 2014 Dec;65(6):868-78.
25. Au NH, Gown AM, Cheang M, Huntsman D, Yorida E, Elliott WM, Flint J, English J, Gilks CB, Grimes HL. p63 expression in lung carcinoma: a tissue microarray study of 408 cases. *Appl Immunohistochem Mol Morphol*. 2004 Sep;12(3):240-7.
26. Thunnissen E, Kerr KM, Herth FJ, Lantuejoul S, Papotti M, Rintoul RC, Rossi G, Skov BG, Weynand B, Bubendorf L, Katrien G, Johansson L, López-Ríos F, Ninane V, Olszewski W, Popper H, Jaume S, Schnabel P, Thiberville L, Laenger F. The challenge of NSCLC diagnosis and predictive analysis on small samples. Practical approach of a working group. *Lung Cancer*. 2012 Apr;76(1):1-18.
27. Conde E, Angulo B, Redondo P, Toldos O, García-García E, Suárez-Gauthier A, Rubio-Viqueira B, Marrón C, García- Luján R, Sánchez-Céspedes M, López-Encuentra A, Paz-Ares L, López- Ríos F. The use of p63 immunohistochemistry for the identification of squamous cell carcinoma of the lung. *PLoS One* 2010;5:1-6.
28. Reeve JG, Stewart J, Watson JV, Wulfrank D, Twentyman PR, Bleehen NM. Neuron specific enolase expression in carcinoma of the lung. *Br J Cancer*. 1986;53(4):519-528.
29. Varma A, Patidar R, Dosi S, Malpan G, Malukani R, Jain PK. Immunohistochemical Staining by TTF-1 and P63 Markers for Typing of Non Small Cell Lung Carcinomas: A Three Year Study of A Tertiary Care Health Center. *International Journal of Contemporary Medical Research*. 2018;5(3):18-22
30. Wu M, Wang B, Gil J, Sabo E, Miller L, Gan L, Burstein DE. p63 and TTF-1 immunostaining. A useful marker panel for distinguishing small cell carcinoma of lung from poorly differentiated squamous cell carcinoma of lung. *Am J Clin Pathol*. 2003 May;119(5):696-702.
31. Terry J, Leung S, Laskin J, Leslie KO, Gown AM, Ionescu DN. Optimal immunohistochemical markers for distinguishing lung adenocarcinomas from squamous cell carcinomas in small tumor samples. *Am J Surg Pathol*. 2010 Dec;34(12):1805-11.