



## THE EFFECT OF RED ONION PEEL AND FORTIFIED BREAD WITH THESE PEELS ON SOME NUTRITIONAL AND BIOCHEMICAL PARAMETERS IN DIABETIC RATS

Ashraf Abd El-Aziz Abd El-megeid; Sonia Saleh El-Marasy and Doaa Abd El- Badie M. M. Mandor

**Article History:** Received: 05.04.2023

Revised: 12.05.2023

Accepted: 17.05.2023

### Abstract

This study aimed to investigate effects of diets containing two levels of red onion peels (ROP) and bread fortified with these peels on nutritional evaluation, some biochemical parameters, and histopathology of livers in rats suffering from diabetes mellitus. Forty-eight male Albino rats were used in this study. The rats were divided into two main groups as follows: The first main group of 12 rats was divided into two subgroups as a follow: Subgroup (1): fed on a basal diet and used as a negative control group. Subgroup (2): fed on a diet containing 250 g of unfortified bread/kg of diet and kept as a control negative group. The second main group: (36 rats) was subcutaneously injected with 120 mg/kg Alloxan monohydrate to induce hyperglycemia. The rats in the second main group were distributed into six equal subgroups as follows: Subgroup (1) was fed a diet containing 250 g of unfortified bread/kg of diet (as a positive control group). Subgroups (2) and (3) were fed diets containing the best two samples from bread estimated by the sensory evaluation (250) g and fortified bread with 10% and 15% of ROP/kg diets, respectively. Subgroup (4) was fed a basal diet (as a positive control group). Subgroups (5) and (6) were fed diets containing the levels of ROP present in 250 g and fortified bread with 10% and 15% ROP/kg diet, respectively. The results indicated that Alloxan increased liver weight/body weight percent, serum result revealed that glucose and most lipid profiles decreased feed intake, body weight gain%, and high-density lipoprotein-cholesterol. Treating diabetic rats with diets containing fortified bread with two levels of ROP (10 and 15%) and also the peels used in preparing this bread improved all of these parameters and ameliorated histopathological lesions seen in the liver as compared to non-treated diabetic rats. Conclusion: Red onion peels (ROP) and bread fortified with these peels can be used to reduce the side effects of diabetes mellitus in diabetic rats. Therefore, intake of ROP may be beneficial for diabetic patients.

**Keywords:** Diabetes, Red onion peels, Fortified bread, Biochemical analysis, Histopathology.

Nutrition and Food Sciences Department, Faculty of Home Economics, Helwan University

**DOI: 10.48047/ecb/2023.12.5.233**

### 1. INTRODUCTION

Diabetes mellitus (DM) is a metabolic disorder with multiple etiologies that is characterized by chronic hyperglycemia and changes in the metabolism of carbohydrates, proteins, and lipids as a result of problems with insulin secretion, resistance, or both. The presence of symptoms like polyuria, polydipsia, and loss of weight is usually symptomatic of diabetes, and the diagnosis is confirmed by the measurement of abnormal high blood sugar level (Atef et al., 2019).

One of the most significant vegetables in the world is the onion (*Allium cepa* L. Amaryllidaceae family), which is consumed both raw and cooked. For commercial use, it is produced as an annual vegetable. The outer scales' hues (yellow, red, and white) and bulb form can vary significantly. Onionskin can reduce the amount of glucose in the blood by inhibiting glucosidase enzyme (Su Jin et

al., 2018). Furthermore, according to Mariana et al., (2020). Ethanol extract from onion peel reduced extreme postprandial increases in blood sugar and improved glucose homeostasis by inhibiting intestinal sucrose and delaying the absorption of carbohydrates. Quercetin, in particular, is abundant in the skin of red onions (*Allium cepa*). The ROP contained three to five times more isolated phenolic compounds and quercetin than the edible section of the onion. Moreover, strong antioxidant, free radical scavenging and antibacterial properties were shown by onion skin extracts (Mona et al., 2018).

Vegetables like red onions, which are deeper in color, contain a variety of phytochemicals, including flavonoids (quercetin) and phenolic compounds that can be employed in medicines as nutraceuticals (Packia et al., 2015). People who consume ROP are thought to have a lower risk of developing stomach, brain, and liver cancer as well as heart attacks and

strokes through decreasing platelet-mediated thrombosis (Asmah et al., 2018).

After oral dosing for six weeks in diabetic rats, a different study discovered quercetin might increase insulin production in a dose-dependent manner and lower blood glucose levels. Additionally, quercetin increased the production of vascular endothelial growth factor (VEGF) and its receptor, VEGFR2 in the pancreas of diabetic rats, which could hasten the recovery of cells (Suganya et al., 2018). The purpose of this study was to investigate the impact of diets containing two levels of ROP and bread fortified with these peels on some nutritional and biochemical parameters in diabetic rats.

## 2. MATERIALS AND METHODS

### Materials:

- Casein, Alloxan, vitamins, minerals, cellulose, and choline chloride were purchased from EL-Gomhoryia Company, Cairo, Egypt.

- Soy oil and red onion were obtained from an agricultural research center, in Giza, Egypt.
- Starch, wheat flour (80% extraction), and yeast were obtained from the local market, in Cairo, Egypt.
- Alloxan monohydrate was purchased from Sigma-Aldrich Chemical Co.
- Rats: Male albino rat of the Sprague Dawley strain weighting  $150 \pm 10$ g were purchased from the Helwan farm of experimental animals, Ministry of Health and Population, Helwan, Cairo, Egypt.
- Kits for biochemical analysis were obtained from Alkan for Pharmaceutical and Chemical Research in Dokki, Giza, Egypt.

### Methods:

Preparation of Bread: Normal bread consists of wheat flour (91g), yeast (5g), salt (2g), and sugar (2g).

Fortified of Bread with Dried Red Onion Peels:

-In this study, white flour was fortified with red onion peels by partially replacing the wheat flour with red onion peels, as follows:

Ingredients Samples	g / 100g				
	Red onion peels	Sugar	Salt	Yeast	Wheat Flour
Control	--	2.0	2.0	5	91
Fortified bread with 10% red onion peels	10	2.0	2.0	5	81
Fortified bread with 15% red onion peels	15	2.0	2.0	5	76
Fortified bread with 20% red onion peels	20	2.0	2.0	5	71

Sensory evaluation of all samples was used to identify the best two samples from bread, which were fortified with red onion peels.

### Sensory evaluation:

The sensory properties of the produced bread were measured by twenty personally trained judges. The judges were asked to give a score from zero to 100 for colour, odour, taste, texture, and general acceptance as reported by, Abd El-latif, (1990) and Amerine et al., (1965).

### Chemical analysis:

•Chemical analysis: moisture content, total protein, fat, fiber, and ash were determined in unfortified bread, and the best two samples from fortified bread with red onion peels powdered "fortified bread with 10% and 15% red onion peels", according to the methods outlined in A.O.A.C (1990), while the carbohydrates content will be calculated by difference.

•Moisture, protein, fat, fiber, ash, carbohydrate, and active components (anthocyanins, total flavonoids, tannins, and total phenolic content) were determined in red onion peels powdered at the Agricultural Research Center, Giza, Egypt, according to (A.O.A.C. 1990).

Biological Part: Forty-eight male rats, Sprague Dawley Strain, weighing  $150 \pm 10$  g were housed in well-aerated wire cages. All animals were kept under normal, healthy conditions and fed on a basal diet that prepared as reported by Reeves et al, (1993) and kept for one week for adaptation before the start of experiment. After the adaptation period, rats were divided into two main groups, as follows: The first main group (12 rats) was divided into two subgroups. Subgroup (1): fed on a basal diet as a control negative group. Subgroup (2): fed on a diet containing 250 g of unfortified bread/kg of diet (a control negative group). The second main group: 36 rats was injected with Alloxan (150 mg/kg b.wt.) to induce hyperglycemia and fed on a basal diet for four days (Buko et al., 1996). After this period, serum glucose was determined in each rat in the first and second main groups to ensure the induction. The rats in the second main group were divided into six subgroups as follows: The first subgroup (6 rats) fed on a diet containing 250 g of unfortified bread / kg diet (as a control positive group). The second and third subgroups (12 rats) were fed diets containing the best two samples from bread, which were estimated by the sensory evaluation (250 g of fortified bread with 10% and 15% ROP / kg diets, respectively). The fourth subgroup (6 rats) fed on a basal diet and used as a control positive group. The fifth and sixth subgroups (12 rats) were fed diets

containing the levels of red onion peels that are present in 250 g of fortified bread with 10% and 15% ROP/kg of diet.

During the experimental period (4 weeks), the diets consumed and body weights were recorded every week. At the end of the experiment, the rats were fasted overnight, and then the rats were anaesthetized by pentobarbital sodium, 40 mg/kg and sacrificed. Blood samples were collected from the aorta of all rats. The blood samples were centrifuged, and serum was separated to estimate some biochemical parameters, i.e., serum glucose (Trinder, 1959), total cholesterol (Allain et al., 1974), triglycerides (Fossati and Principle, 1982), high density lipoprotein HDL-c (Burstain, 1970), low density lipoprotein LDL-c, and VLDL-c (Friedewald et al., 1972). The liver was separated from each rat and weighted to calculate the liver weight to body weight %. The liver in each group was examined histopathologically in Pathology Department, Faculty of Veterinary Medicine, Cairo University. Livers of sacrificed rats were taken and immersed in a 10% formalin solution. The fixed specimens were then trimmed, washed, and dehydrated in ascending grades of alcohol (from 70% to 100%). They were then cleared in xylol, embedded in paraffin, sectioned at 4-6 microns' thickness, and stained with Heamatoxylin and Eosin according to (Sheehan and Hrapchak, 1980) for the examination.

The results of the biological evaluation of each group were statistically analyzed (mean  $\pm$  standard deviation and one way ANOVA test) using the SAS package and compared with each other using the suitable test (least significant differences at  $P < 0.05$  (SAS, 1996).

### 3. RESULTS AND DISCUSSION

#### Chemical Composition of Red Onion Peels (ROP) Powder (100g dry weight basis)

Table (1) presents the proximate chemical composition of powdered ROP (on a 100-g dry weight basis). The data in this table showed that the mean values of moisture, total protein, fat, ash, crude fibers, and carbohydrates were 8.16, 0.90, 0.13, 0.7, 0.30, and 89.81 g/100 g dry weight, respectively. From this data, it was revealed that ROP powder is a rich source of carbohydrates.

The approximate chemical composition of powdered ROP (on a 100-g dry weight basis) is shown in Table 1. According to the information in this table, the average amounts of moisture, total protein, fat, ash, crude fiber, and carbohydrates per 100 grams of dry weight were 8.16, 0.90, 0.13, 0.7, 0.30, and 89.81g, respectively. These findings showed that ROP powder is a rich source of carbohydrates.

**Table (1):** Chemical Composition of Red Onion Peels Powdered (100g dry weight basis)

Components (g)	Ingredients
	Dry weight
Moisture (g)	8.16
Total Protein (g)	0.90
Fats (g)	0.13
Ash (g)	0.7
Crude Fibers (g)	0.30
Carbohydrates*(g)	89.81
Anthocyanins (mg/100g)	0.105
Total flavonoids ( $\mu$ g QUE / ml)	112.53
Total phenolic content ( $\mu$ g ml/GAE)	550.73
Tannins (mg/100g)	1.30

Each value represents the mean of two determinations.

\* Total carbohydrates were calculated by differences.

The data in this table also revealed that the mean concentrations of anthocyanins, total flavonoids, total phenolic content, and tannins in powdered ROP were (0.105 mg/100g, 112.53  $\mu$ g QUE / ml, 550.73  $\mu$ g ml/GAE and 1.30 mg/100g, respectively. In this regard, (Beatrice, 2017) discovered that onion peel has a very low protein content (0.88%) and a very high carbohydrate content (88.56%). Onion peel extract yielded 98.52  $\mu$ g QUE / ml total flavonoid, 664.30  $\mu$ g / ml GAE total phenol, total antioxidant property (1338.15  $\mu$ g / ml) and scavenged DPPH radicals of 27.76  $\mu$ g / ml.

According to Manoj et al. (2022), onion peel has a variety of therapeutic benefits for treating conditions like cancer, obesity, diabetes, neurological disorders, cardiovascular disorders, microbiological damage, and erectile dysfunction due to the presence of bioactive substances. As a result, onion peel can be used as a medicinal and therapeutic agent in a variety of sectors in the form of powders or extracts. On the other hand, according to the same authors, numerous thorough studies have confirmed that onion peel is a concentrated source of bioactive compounds and provides a variety of medicinal advantages. The biochemical components, particularly

phytochemicals like quercetin and its derivatives, total flavonoids, total polyphenols, and other phytochemicals found in onion peel, make its use in the medical and pharmaceutical industries possible.

Sensory Evaluation of Bread Fortified with Three Levels of Onion Peel Powder

One of the bakery goods that is regularly consumed is bread. Considering the crucial role that nutrition plays in many diseases, including diabetes, a whole-

wheat bread diet improves postprandial blood glucose levels as compared to a diet high in refined grains, such as white bread. On the other hand, adding red onion peel powder when preparing bread is a good way to increase the bread's nutritional value. The sensory properties of prepared bread fortified with red onion peel powder are displayed in Table (2).

**Table (2):** Sensory Evaluation of Bread Fortified with Three Levels of Onion Peel Powder

Sensory Characteristics	Control	Bread with Onion Peels Powdered		
		10%	15%	20%
Color (20)	19.44 <sup>a</sup> ± 0.341	18.53 <sup>a</sup> ± 0.410	18.43 <sup>a</sup> ± 0.442	11.82 <sup>b</sup> ± 0.581
Taste (20)	19.35 <sup>a</sup> ± 0.229	18.32 <sup>a</sup> ± 0.270	17.52 <sup>b</sup> ± 0.733	13.61 <sup>c</sup> ± 0.389
Odor (20)	19.09 <sup>a</sup> ± 0.220	18.44 <sup>a</sup> ± 0.461	17.03 <sup>b</sup> ± 0.430	13.41 <sup>c</sup> ± 0.511
Texture (20)	19.41 <sup>a</sup> ± 0.352	18.72 <sup>a</sup> ± 0.353	18.74 <sup>a</sup> ± 0.334	15.24 <sup>b</sup> ± 0.45
General Acceptance (20)	19.49 <sup>a</sup> ± 0.280	18.13 <sup>a</sup> ± 0.324	17.51 <sup>b</sup> ± 0.550	13.26 <sup>c</sup> ± 0.77
Total Score (100)	96.78 <sup>a</sup> ± 0.361	92.14 <sup>b</sup> ± 0.448	89.23 <sup>c</sup> ± 1.371	67.45 <sup>d</sup> ± 1.238

Mean values in the same row which is not followed by the same letter are significantly different ( $p \leq 0.05$ ).

The results revealed that bread fortified with 10% and 15% red onion peel powder showed a non-significant difference in color and texture, while fortified bread with 20% red onion peel powder decreased the score of color and texture significantly ( $p \leq 0.05$ ), as compared to un-fortified bread. On the other hand, the data presented in this table revealed that, the mean score of taste, odor, and general acceptance in fortified bread decreased gradually with increasing levels of red onion peels. The highest score of the sensory evaluation was recorded for the control sample (un-fortified bread), followed by the bread fortified with 10%, 15%, and 20% red onion peels, respectively. Therefore, the biological part of this study was done to determine the effect of

fortified bread with 10% and 15% red onion peel powder on diabetic rats.

In this respect, Jung et al. (2011) reported that bread with onion peel and onion powder added is higher in nutritional value than normal bread because it contains active ingredients like quercetin and allyl sulphur compounds. On the other hand, Sara et al., (2020) revealed that the organoleptic characteristics of onion peel extract-supplemented bread were superior to those of plain white flour bread in terms of aroma, appearance, texture, and taste. Therefore, there is potential to testify to the use of onion peel in other types and forms of bread to drive the idea of food supplementation parallel to food innovation.

**Table (3):** Chemical Composition of Bread Fortified with 10% and 15% Red Onion Peel Powder (% Fresh Weight and Dry Weight Basis)

Components (g)	Unfortified Bread		Fortified Bread with Red Onion Peels Powdered			
	FW	DW	10%		15%	
			FW	DW	FW	DW
Moisture	35	6.05	34.73	5.92	34.50	5.75
Total Protein	9.73	14.96	9.66	14.80	9.42	14.38
Fat	2.44	3.75	2.21	3.38	2.12	3.23
Ash	1.62	2.49	1.50	2.29	1.40	2.14
Crude fiber	3.61	5.56	3.48	5.33	3.36	5.13
Carbohydrate*	47.60	67.19	48.42	68.28	49.2	69.37

Data are expressed as mean ± SD.  $p > 0.05$  = not significant.  $*p \leq 0.05$  = significant

The data in Table (3) showed the approximate chemical composition of unfortified and fortified bread with 10 and 15% red onion peels, respectively. The information in this table showed that the average amounts of moisture, total protein, fat, ash, crude fiber, and carbohydrates in 100 g of unfortified bread were 35, 9.73, 2.44, 1.62, 3.61, and 47.60 g,

respectively, and 6.05, 14.96, 3.75, 2.49, 5.56, and 67.19 g dry weight, respectively.

Table (3): Chemical Composition of Bread Fortified with 10% and 15% Red Onion Peel Powder (% Fresh Weight and Dry Weight Basis)



Each value represents the mean of two determinations. \* Total carbohydrates were calculated by differences

FW: Fresh weight DW: dry weight

On the other hand, fortified bread with 10% red onion peel powder showed changes in moisture, total protein, fat, ash, crude fiber, and carbohydrate, which were recorded (34.73, 9.66, 2.21, 1.50, 3.48, and 48.42 g/100 g fresh weight, respectively) and (5.92, 14.80, 3.38, 2.29, 5.33, and 68.28 g/100g dry weight, respectively). While these nutrients in fortified bread with 15% red onion peel powder were recorded (34.50, 9.42, 2.12, 1.40, 3.36, and 49.2g/100g fresh weight basis, respectively) and (5.75, 14.38, 3.23, 2.14, 5.13, and 69.37g/100g dry weight basis, respectively), the data in this table showed that the highest amounts of nutrients were presented in unfortified and fortified bread, with 10% and 15% red onion peels recorded for carbohydrates, followed by protein, crude fiber, fat, and ash, respectively.

Effect of Fortified Bread with Two Levels of Red Onion Peels and Also the Peels Used in Preparing This Bread on Feed Intake and Body Weight Gain% and Liver Weight/Body Weight% of Diabetic Rats.

Data in Table 4 showed the effect of fortified bread with two levels of red onion peels and also the peels used in preparing this bread on feed intake, and liver weight / body weight% body weight gain% of diabetic rats.

The mean value of feed intake (FI) of diabetic rats fed on a diet containing 250g / kg diet (the "positive control group") decreased significantly  $p \leq 0.05$  as compared to the negative control group fed on the same diet ( $15.466 \pm 0.503$  vs.  $17.600 \pm 0.655$  g / each rat), respectively. The same trend was observed when fed diabetic rats on a basal diet, as compared to healthy rats who were fed on a basal diet ( $15.200 \pm$

$0.458$  vs.  $16.766 \pm 0.665$  g / each rat), respectively. According to the results in this table, there were no statistically significant differences in the mean value of FI between any of the treated diabetic rat groups fed either a diet consisting of 250 g of bread fortified with 10% or 15% red onion peels or a basal diet consisting of the amounts of ROP used for preparing the fortified bread. On the other hand, the mean values of feed intake in all treated groups showed non-significant changes as compared to the positive control groups.

The data in this table showed that the mean value of body weight gain % (BWG%) in diabetic rats fed on a diet containing 250g of unfortified bread decreased significantly ( $p \leq 0.05$ ), as compared to healthy rats fed on the same diet ( $23.800 \pm 0.721$  vs.  $27.933 \pm 0.814$ ), respectively. Diabetic rats who were fed on a diet containing 250g fortified bread with 15% red onion peel ROP recorded a significant decrease ( $p \leq 0.05$ ) in BWG%, while diabetic rats fed on a diet containing the same amount of bread fortified with 10% ROP showed a non-significant change in BWG%, as compared to the positive control group fed on a diet containing 250g of unfortified bread.

Feeding diabetic rats on a basal diet led to a significant decrease ( $p \leq 0.05$ ) in BWG%, as compared to healthy rats fed on the same diet. On the other hand, feeding rats on a basal diet containing the amounts of ROP that were used in preparing fortified bread with 10% and 15% caused a significant decrease ( $p \leq 0.05$ ) in BWG% as compared to the positive control group fed on a basal diet. The highest decrease in BWG% was recorded for the group fed on a basal diet containing ROP that was used in preparing fortified bread with 15%, followed by the group fed on a diet containing 250g of fortified bread with 15% ROP, respectively.

**Table (4):** Effect of Fortified Bread with Two Levels of Red Onion Peels and Also the Peels Used in Preparing This Bread on Feed Intake and Body Weight Gain% of Diabetic Rats

Parameters		Feed intake g/day/each rat	Body weight gain %	Liver weight / body weight%	
Groups					
1	Control (-ve) fed on diet containing 250 g unfortified bread / kg diet	17.600 <sup>a</sup> ± 0.655	27.933 <sup>a</sup> ± 0.814	2.931 <sup>e</sup> ± 0.059	
2	Control (+ve) fed on diet containing 250 g unfortified bread / kg diet	15.466 <sup>b</sup> ± 0.503	23.800 <sup>c</sup> ± 0.721	3.796 <sup>a</sup> ± 0.100	
3	Diabetic rats fed on diet containing	250g fortified bread with 10% ROP / kg diet	15.200 <sup>b</sup> ± 0.458	22.866 <sup>cd</sup> ± 0.493	3.563 <sup>b</sup> ± 0.055
4		250g fortified bread with 15% ROP / kg diet	15.066 <sup>b</sup> ± 0.404	21.000 <sup>ef</sup> ± 0.519	3.294 <sup>d</sup> ± 0.038
5	Control (-ve) fed on basal diet (BD)	16.766 <sup>a</sup> ± 0.665	25.933 <sup>b</sup> ± 0.568	2.734 <sup>f</sup> ± 0.079	
6	Control (+ve) fed on (BD)	15.200 <sup>b</sup> ± 0.458	23.400 <sup>c</sup> ± 0.200	3.434 <sup>c</sup> ± 0.079	
7	Diabetic rats fed on BD containing	ROP which present in 250 g fortified bread with 10%	14.966 <sup>b</sup> ± 0.472	21.900 <sup>de</sup> ± 0.624	3.173 <sup>d</sup> ± 0.060
8		ROP which present in 250 g fortified bread with 15%	14.633 <sup>b</sup> ± 0.513	20.400 <sup>f</sup> ± 0.692	2.985 <sup>e</sup> ± 0.75

ROP: Red onion peel.

BD: Basal diet

Means in the same column with different letters are significantly different at ( $p \leq 0.05$ ).

Liver weight/body weight % of diabetic rats fed on a diet containing 250g of unfortified bread / kg of diet increased the mean values of this organ, as compared to normal rats fed on the same diet. Treating diabetic rats with diets containing 250 g of fortified bread with 10 and 15% ROP led to a significant decrease in liver weight/body weight %, as compared to the positive control group fed on a diet containing unfortified bread. On the other hand, the group of rats fed on a diet containing 250 g of fortified bread with 15% ROP recorded the highest decrease in liver weight/ body weight %, as compared to the group treated with 250g of fortified bread with 10%. The same trend was observed when using the basal diet, which contained ROP that was used in preparing fortified bread at 10% and 15%.

In this respect Jung et al., (2011) and Yang et al., (1996) reported that onion peels contain a higher density of quercetin-rich than the onion core. Supplementation with quercetin rich onion peel extract reportedly significantly lowered oral glucose tolerance and, combined with the rich dietary fiber in onion peels, was reported to be effective in the improvement of blood lipid levels and body weight gain. Ji Sook et al., (2016) reported that quercetin-rich onion peel extract (OPE) supplementation changed the body composition of overweight and obese subjects. The authors in this study suggest the beneficial role of the anti-obesity effect by using OPE in human subjects.

**Effect of Fortified Bread with Two Levels of Red Onion Peels and Also the Peels Used in Preparing This Bread on Serum Glucose of Diabetic Rats.**

The effect of fortified bread with two levels of red onion peels ("ROP") (10 and 15%) and also the peels used in preparing this bread on the serum glucose of diabetic rats is presented in Table (5). Injecting rats with Alloxan and feeding them a diet containing 250 g of unfortified bread/kg diet led to a significant increase ( $P \leq 0.05$ ) in serum glucose, as compared to the negative control group fed on the same diet. The mean value of serum glucose increased by about 103.435% in the positive control group compared to that of the negative control group.

Feeding diabetic rats on a diet containing 250 g of fortified bread with 10% and 15% ROP led to a significant decrease  $p \leq 0.05$  in serum glucose, as compared to the positive control group. On the other hand, treating diabetic rats with a diet that

contained fortified bread with 15% ROP recorded a significant decrease in the mean value of serum glucose, as compared to the rats treated with a diet containing fortified bread with 10% ROP. The mean value of serum glucose in the diabetic group fed on a diet containing fortified bread with 15% ROP decreased by about 36.723% compared to that of the control positive group.

On the other side, the data in the same table revealed that injected rats with Alloxan and fed on a basal diet significantly increased the mean value of serum glucose ( $P \leq 0.05$ ), as compared to non-injected rats. Diabetic rats which were fed on a basal diet containing the amounts of ROP that were used in preparing fortified bread with 10% and 15% showed a significant decrease ( $P \leq 0.05$ ), as compared to the positive control group fed on a basal diet.

From this table, it could be observed that the mean values of serum glucose in the control (-ve and +ve) groups that were fed on unfortified bread increased significantly as compared to the control (-ve and +ve) groups fed on a basal diet. Also, diabetic groups that were fed on a diet containing fortified bread with 10% and 15% ROP recorded a significant increase in the mean value of serum glucose as compared to the diabetic groups fed on a basal diet containing the amounts of ROP that were used in preparing the bread fortified with 10% and 15% ROP.

In this respect, an Alloxan-induced diabetic rat is one of the animal models of human diabetes mellitus. Diabetes arises from the irreversible destruction of pancreatic  $\beta$ -cells, causing degranulation and a reduction in insulin secretion (Zhang and Tan, 2000). Alloxan-induced diabetes is characterized by hyperglycemia and a severe loss in body weight (Chen and Ianuzzo, 1982). On the other hand, Lee et al., (2008) suggest that onion skin is effective in controlling hyperglycemia in animal models of type 2 diabetes mellitus, at least in part by inhibiting  $\alpha$ -glucosidase activity.

The peel of an onion, which is generally regarded as biowaste is rich in various phytonutrients. Although the management of diabetes with traditional plants has been a widespread practice for centuries (Kesari et al., 2005), only a few remedies have been assessed scientifically. Many researchers have demonstrated the antidiabetic, hypochlosterolemic, and antioxidant potential of onion peel and onion powder (Kang et al., 2010).

**Table (5):** Effect of Fortified Bread with Two Levels of Red Onion Peels and Also the Peels Used in Preparing This Bread on Serum Glucose of Diabetic Rats

Groups		Parameter	Glucose mg/dL
1	Control (-ve) fed on diet containing 250 g unfortified bread / kg diet		91.667 <sup>f</sup> ± 6.951
2	Control (+ve) fed on diet containing 250 g unfortified bread / kg diet		186.483 <sup>a</sup> ± 5.354
3	Diabetic rats fed on diet containing	250g fortified bread with 10% ROP / kg diet	131.000 <sup>c</sup> ± 6.557
4		250g fortified bread with 15% ROP / kg diet	118.000 <sup>d</sup> ± 9.165
5	Control (-ve) fed on basal diet (BD)		79.773 <sup>b</sup> ± 1.988
6	Control (+ve) fed on (BD)		169.673 <sup>b</sup> ± 5.816
7	Diabetic rats fed on BD containing	ROP which present in 250 g fortified bread with 10%	119.613 <sup>d</sup> ± 4.960
8		ROP which present in 250 g fortified bread with 15%	106.253 <sup>e</sup> ± 7.101

ROP: Red onion peel. BD: Basal diet

Means in the same column with different letters are significantly different at (p≤0.05).

Masood et al., (2021) reported that bread supplemented with 1% and 3% onion peel extract and 7% onion powder significantly reduced blood glucose levels and MDA in the treated rats compared with the control group of diabetic rats.

Red onion peels contain a high amount of quercetin. Researchers indicate that quercetin has good anti-diabetic effects. Quercetin may exert antidiabetic effects through various mechanisms, including promoting insulin secretion, improving insulin resistance, maintaining glucose homeostasis, and inhibiting inflammation, oxidative stress, and apoptosis (Huan et al., 2021). On the other hand, Carrasco et al., (2016) reported that quercetin could resist cholesterol-induced pancreatic  $\beta$  cell dysfunction, thereby maintaining glucose-stimulated insulin secretion and glycemic control. Jung et al., (2011) reported that phytochemicals such as quercetin and allyl-propyl disulfides found in onion peel and bulb might be responsible for the beneficial effect on blood glucose levels by up-regulating the expression of insulin receptors and glucose transporters, improving insulin sensitivity, and promoting glucose metabolism in peripheral tissues in diabetic rats.

Effect of Fortified Bread with Two Levels of Red Onion Peels and Also the Peels Used in Preparing This Bread on Lipid Profiles of Diabetic Rats.

The effect of fortified bread containing two levels of red onion peels ("ROP") (10 and 15%) as well as the amounts of peels used in making these breads on the serum lipid profile, including cholesterol, triglycerides, high density lipoprotein cholesterol HDL-c, low density lipoprotein cholesterol LDL-c,

and very low density lipoprotein cholesterol VLDL-c "mg/dl" of diabetic rats, is shown in Table (6).

Rats who were injected with 150 mg Alloxan /kg body weight and fed on a diet containing 250 g unfortified bread/kg diet showed a significant increase ( $P \leq 0.05$ ) in serum cholesterol and triglycerides as compared to the negative control group fed on the same diet. The mean values of serum cholesterol and triglycerides increased by about 78.08% and 106.89% in the positive control group compared to the negative control group, respectively. Feeding diabetic rats on a diet containing 250 g of fortified bread with 10% and 15% ROP led to a significant decrease  $p \leq 0.05$  in serum cholesterol and triglycerides, as compared to the positive control group. On the other hand, treating diabetic rats with a diet that contained fortified bread with 15% ROP recorded a significant decrease in the mean value of serum cholesterol and triglycerides, as compared to the rats treated with a diet containing fortified bread with 10% ROP.

On the other hand, injected rats with Alloxan to induce diabetes and fed on a basal diet significantly increased the mean values of serum cholesterol and triglycerides ( $P \leq 0.05$ ) as compared to non-injected rats fed on a basal diet. The data presented in this table showed that the mean values of serum cholesterol, and triglycerides increased in the positive control group that fed on a basal diet by about (168.704%, and 77.910%) respectively, compared to the negative control group that fed on a basal diet. Diabetic groups that were fed on a basal diet containing the amounts of ROP that were used in preparing fortified bread at 10% and 15% showed a

significant decrease in serum cholesterol and triglycerides ( $P \leq 0.05$ ), as compared to the positive control group fed on a basal diet.

Injected rats with Alloxan to induce diabetes, and fed on a diet containing 250 g unfortified bread/kg diet or basal diet showed a significant decrease ( $P \leq 0.05$ ) in serum high-density lipoprotein cholesterol HDL-c and increased low and very low density and very low-density lipoprotein-cholesterol "LDL-c and VLDL-c" significantly  $p \leq 0.05$ , as compared to the negative control groups who fed on the same diets.

Feeding diabetic rats on a diet containing 250 g of fortified bread with 10% and 15% ROP led to a significant increase ( $p \leq 0.05$ ) in serum HDL-c and decreased serum LDL-c and VLDL-c, as compared to the positive control group. On the other hand, treating diabetic rats with a diet containing fortified bread with 15% ROP led to a significant increase ( $p \leq 0.05$ ) in the mean value of serum HDL-c and decreased the mean values of serum LDL-c and VLDL-c, as compared to the rats treated with a diet containing fortified bread with 10% ROP. The same trend was observed when using the basal diet, which contained ROP that was used in preparing fortified bread at 10% and 15%.

Ofoelo et al., (2017) reported the high concentration of lipid profiles, except HDL-c, observed in diabetes-untreated rats compared to the normal rats group. Reitman and Frankel (1975), suggest that an elevated glucose level will occur upon induction of diabetes, and this would give rise to a corresponding increase in plasma lipid concentration. Hyperlipidemia is a factor in cardiovascular diseases associated with diabetes mellitus. It is often characterized by elevated cholesterol, triglycerides, phospholipids, and other lipoproteins (Klein et al., 2004).

Feeding diabetic groups on a diet containing fortified bread with two levels of red onion peels ("ROP") (10 and 15%) and also the amounts of the peels that were used in preparing breads improved their lipid profiles as compared to the positive control groups. In this respect, Kim et al., (2013) reported that the consumption of onion peel bread (OPB) and garlic peel bread (GPB) induced a significant improvement in the blood lipid profile through decreasing the TC and LDL by a ratio of 18.46 and 26.11%; 39.31 and 55.6 % respectively; the opposite direction was observed for the HDL levels. The authors of this research reported that onion peel extract significantly decreased blood triglycerides.

Onion peels contain a higher density of quercetin than the onion core. Recently, quercetin therapy has attracted attention for its efficacy in the improvement of hyperlipidemia and the prevention and improvement of obesity complications. Quercetin, which is extracted from vegetables such as apples and onions, has been known to be a flavonoid substance with bioactive activities (Ji Sook et al., 2016).

Kang et al., (2016) reported that after 12 weeks of onion peel extract (100 mg/kg body weight; 200 mg/kg body weight) supplementation along with a high-fat diet in a mouse model, a hypocholesterolemic effect was exhibited. The main mechanism involved was increasing mRNA expression levels of low-density lipoprotein receptor (LDL-R) and cholesterol 7- $\alpha$ -monooxygenase (CYP7A1) involved in hepatic cholesterol metabolism, reducing in serum and hepatic cholesterol, and excreting it via feces.

Histopathological examination of the liver:

Microscopically, the liver of rats from a control negative group fed on a diet containing 250g of unfortified bread/kg of diet showed the normal histological architecture of hepatic lobules with normal central veins and normal hepatocytes (Fig. 1). On the contrary, the liver of rats from the diabetic group (control positive group) fed on a diet containing 250g of unfortified bread/kg diet exhibited hepatocellular vacuolar degeneration (Figs. 2 & 3), congestion of hepatic sinusoids (Fig. 2), and portal edema with a few inflammatory cell infiltrations (Fig. 3). On the other hand, the liver of diabetic rats fed a diet containing 250g of fortified bread with 10% ROP / kg diet showed hepatocellular steatosis (Figs. 4 and 5). Meanwhile, some liver sections of diabetic rats fed on a diet containing 250g fortified bread with 15% ROP / kg diet revealed mild changes such as slight Kupffer cell activation (Figs. 6 and 7) and slight congestion of hepatic sinusoids (Fig. 7), whereas, others described no histopathological changes (Fig. 8). Liver sections of normal rats fed on a basal diet described the normal histological architecture (Fig. 9). Otherwise, sections from the diabetic group fed on a basal diet revealed hepatocellular vacuolar degeneration (Figs. 10 and 11), dilatation of hepatic sinusoids (Fig. 10), and portal edema with congestion of hepatoportal blood vessels (Fig. 11). Moreover, mild lesions were recorded in the liver of the diabetic group fed on a basal diet containing ROP, which is present in 250 g of fortified bread with 10%, as slight Kupffer cell activation (Fig. 12) and slight congestion of the hepatic sinusoids (Fig. 13). However, sections from the diabetic group fed on a basal diet containing ROP, which is present in 250 g fortified bread with 15%, exhibited Kupffer cell activation, congestion of hepatic sinusoids (Fig. 14), and sinusoidal leukocytosis (Fig. 15), although other sections showed the normal histological architecture of hepatic lobules (Fig. 16). In this respect, Kim et al., (2011) reported that onion extract can be an alternative therapeutic reference to improve the histopathological picture of the Alloxan-induced liver. Onion has high level phenolic phytochemical compounds. Phenolic and phytochemicals from onion have a blood glucose-lowering effect and high antioxidant activity in the Alloxan-induced diabetic rat.

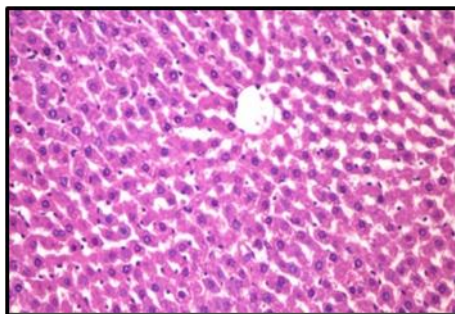


**Table (6):** The Effect of Red Onion Peels and Fortified Bread with These Peels on Serum Total Cholesterol (TC) and Triglycerides (TG) in Diabetic Rats

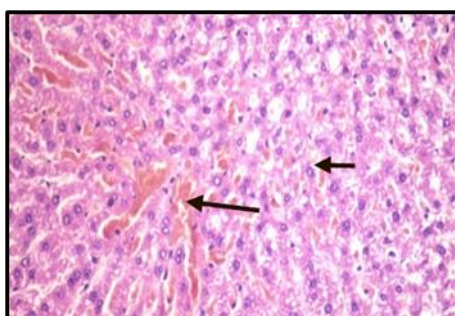
Parameters Groups		TC	TG	HDL-c	LDL-c	VLDL-c	
		(mg/dL)					
1	Control (-ve) fed on diet containing 250 g unfortified bread / kg diet	73.220 <sup>e</sup> ±1.598	38.066 <sup>e</sup> ±2.343	50.043 <sup>a</sup> ± 1.548	15.563 <sup>e</sup> ± 0.999	7.613 <sup>e</sup> ± 0.468	
2	Control (+ve) fed on diet containing 250 g unfortified bread / kg diet	130.393 <sup>a</sup> ±6.859	78.756 <sup>a</sup> ±3.154	29.650 <sup>e</sup> ± 2.348	84.992 <sup>a</sup> ± 3.898	15.751 <sup>a</sup> ± 0.630	
3	Diabetic rats fed on diet	containing 250g fortified bread with 10% ROP / kg diet	110.906 <sup>b</sup> ±2.419	65.076 <sup>b</sup> ±3.449	37.380 <sup>d</sup> ± 1.442	60.511 <sup>b</sup> ± 1.699	13.015 <sup>b</sup> ± 0.689
4		containing 250g fortified bread with 15% ROP / kg diet	93.880 <sup>d</sup> ±3.365	53.000 <sup>c,d</sup> ±4.249	41.789 <sup>c</sup> ± 1.670	41.490 <sup>d</sup> ± 2.098	10.600 <sup>c,d</sup> ±0.849
5	Control (-ve) fed on basal diet (BD)		70.800 <sup>e</sup> ±0.945	35.366 <sup>e</sup> ±2.525	49.037 <sup>a,b</sup> ± 1.840	14.689 <sup>e</sup> ± 1.572	7.073 <sup>e</sup> ± 0.505
6	Control (+ve) fed on BD		127.243 <sup>a</sup> ±2.475	62.920 <sup>b</sup> ±3.395	31.170 <sup>e</sup> ± 1.801	83.489 <sup>a</sup> ± 2.311	12.584 <sup>b</sup> ± 0.679
7	Diabetic rats fed on BD	containing ROP which present in 250 g fortified bread with 10%	103.000 <sup>c</sup> ±3.605	56.166 <sup>c</sup> ±3.323	42.613 <sup>c</sup> ± 2.771	49.153 <sup>c</sup> ± 1.332	11.233 <sup>c</sup> ± 0.664
8		containing ROP which present in 250 g fortified bread with 15%	95.680 <sup>d</sup> ±4.617	48.886 <sup>d</sup> ±3.618	45.666 <sup>b,c</sup> ± 3.335	40.236 <sup>d</sup> ± 0.568	9.777 <sup>d</sup> ± 0.723

ROP: Red onion peel. BD: Basal diet

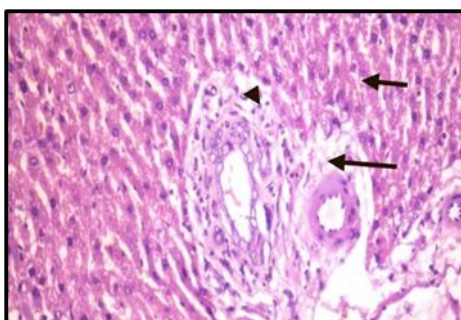
Means in the same column with different letters are significantly different at p≤0.05.



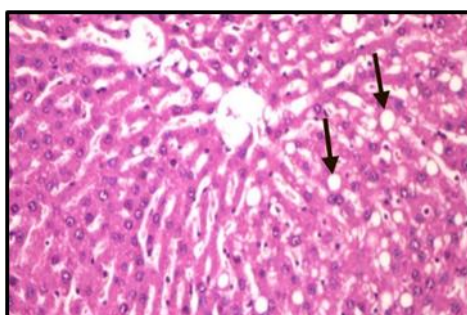
**Fig. (1):** Photomicrograph of liver of normal rat fed on a diet containing 250g unfortified bread/kg diet showing the normal histological architecture of hepatic lobule (H & E X 400).



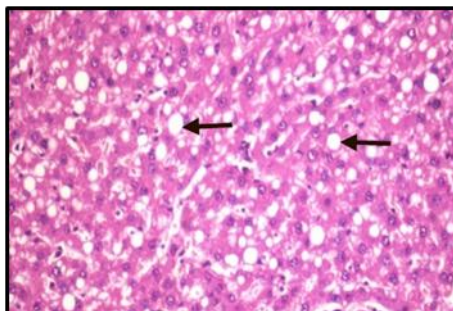
**Fig. (2):** Photomicrograph of liver of diabetic rat fed on a diet containing 250g unfortified bread/kg diet showing hepatocellular vacuolar degeneration and congestion of hepatic sinusoids (H & E X 400).



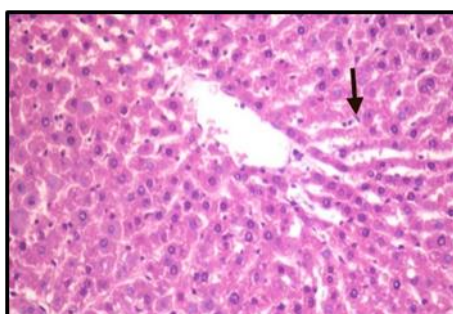
**Fig. (3):** Photomicrograph of liver of diabetic rat fed on a diet containing 250g unfortified bread/kg diet showing hepatocellular vacuolar degeneration, portal edema with few inflammatory cells infiltration (H & E X 400).



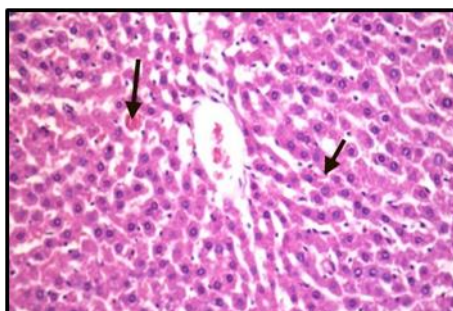
**Fig. (4):** Photomicrograph of liver of diabetic rats fed on diet containing 250g fortified bread with 10% ROP / kg diet showing hepatocellular steatosis (H & E X 400).



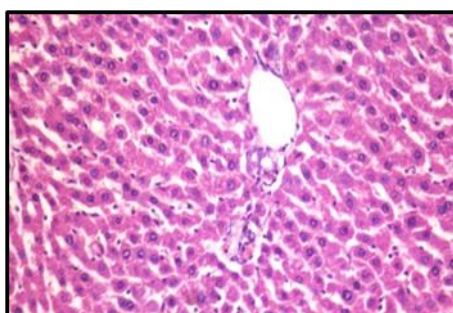
**Fig. (5):** Photomicrograph of liver of rat from diabetic rats fed on diet containing 250g fortified bread with 10% ROP / kg diet showing hepatocellular steatosis (H & E X 400).



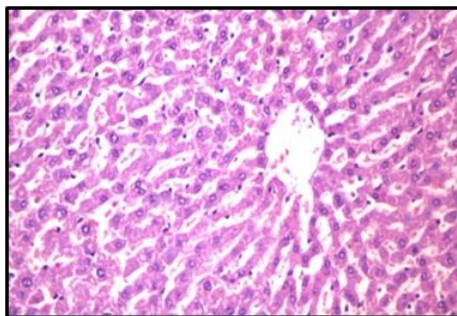
**Fig. (6):** Photomicrograph of liver of diabetic rats fed on diet containing 250g fortified bread with 15% ROP / kg diet showing slight Kupffer cells activation (H & E X 400).



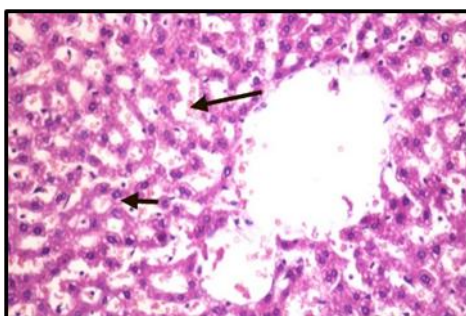
**Fig. (7):** Photomicrograph of liver of diabetic rats fed on diet containing 250g fortified bread with 15% ROP / kg diet showing slight Kupffer cells activation and slight congestion of hepatic sinusoids (H & E X 400).



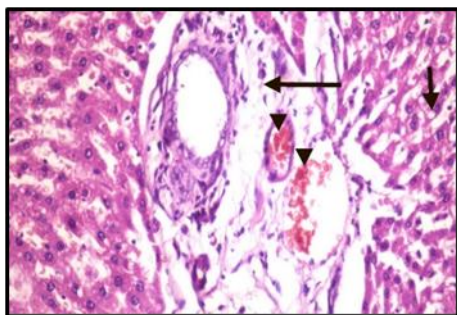
**Fig. (8):** Photomicrograph of liver of diabetic rats fed on diet containing 250g fortified bread with 15% ROP / kg diet showing no histopathological changes (H & E X 400).



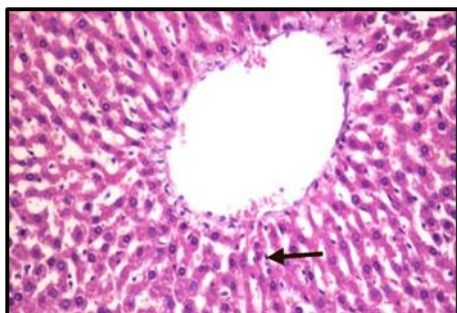
**Fig. (9):** Photomicrograph of liver normal rats fed on basal diet showing normal histological architecture (H & E X 400).



**Fig. (10):** Photomicrograph of liver of diabetic rats fed on basal diet showing hepatocellular vacuolar degeneration and dilatation of hepatic sinusoids (H & E X 400).

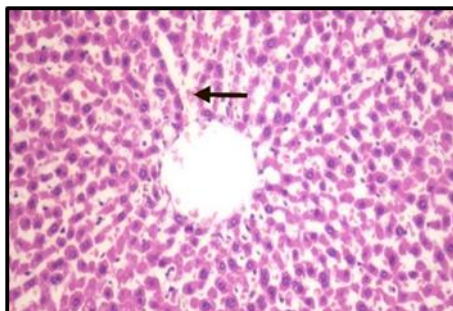


**Fig. (11):** Photomicrograph of liver of diabetic rats fed on basal diet showing hepatocellular vacuolar degeneration, portal edema with congestion of hepatoportal blood vessels (H & E X 400).

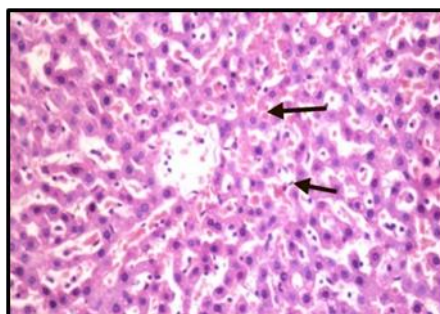


**Fig. (12):** Photomicrograph of liver of diabetic rats fed on basal diet containing ROP which present in 250 g fortified bread with 10% showing slight Kupffer cells activation (H & E X 400).

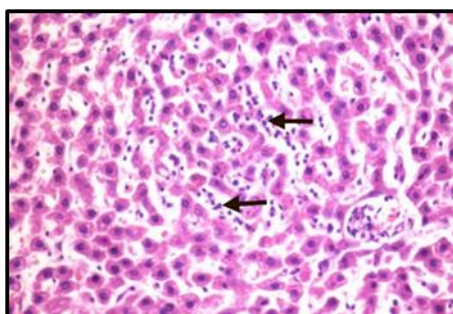




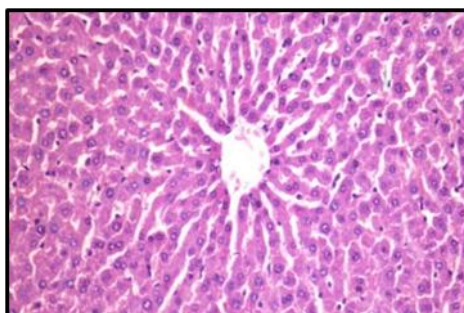
**Fig. (13):** Photomicrograph of liver of diabetic rats fed on basal diet containing ROP which present in 250 g fortified bread with 10% showing slight congestion of hepatic sinusoids (H & E X 400).



**Fig. (14):** Photomicrograph of liver of diabetic rats fed on basal diet containing ROP which present in 250 g fortified bread with 15% showing Kupffer cells activation and congestion of hepatic sinusoids (H & E X 400).



**Fig. (15):** Photomicrograph of liver of rat from diabetic group fed on basal diet containing ROP which present in 250 g fortified bread with 15% showing sinusoidal leukocytosis (H & E X 400).



**Fig. (16):** Photomicrograph of liver of normal rat fed on a diet containing 250g unfortified bread/kg diet showing the normal histological architecture of hepatic lobule (H & E X 400).

#### **4. REFERENCES**

**Abd El-latif, B.M. (1990):** Improvement of some bakery products. Thesis Ph.D. Food Tech. Agric. Moshtohor, Zagazig University.

**Allain, C.Z. and Poon, L. S. (1974):** Enzymatic determination of total serum cholesterol. Clin. Chem., 20:470:475

**Amerine, M.A.; Paglorn, R.M. and Roessler, E. B. (1965):** Principals of sensory evaluation of food. Academic Press, New York.



- A.O.A.C. (1990):** Official Methods of Analysis of the Association of Official Analytical Chemists. 15th ed. Washington, D. C.
- Asmah Rahmat; Choo Yenleng; Fazleen Izzany Abu Bakar, Mohd Fadzelly Abu Bakar (2018):** "Effect of red onion (*AlliumCepa*Var. *Aggregatum* G. Don) on serumric Acidlevel and total antioxidant status in normal and induced hyper uricemic rats," *Asian J. Pharm. Clin. Res.*, 11 (3): 178-183.
- Atef, M.; Al-Attar; Fawziah A. and Alsalmi (2019):** Influence of olive leaves extract on hepatorenal injury in streptozotocin diabetic rats. *Saudi J. Biolog.Sci.*; 1865–1874.
- Beatrice O. T. Ifesan (2017):** Chemical Composition of Onion Peel (*Allium cepa*) and its Ability to serve as a Preservative in Cooked Beef. *Human Journals*, 7 (4): 25-34.
- Buko, V.; Lukivskaya, O.; Tarasov, Y.; Zavodnik, L.; Borodassky, A. and Gundermann, K.J. (1996):** "Hepatic and pancreatic effect of polyenooyl phatidyl choline in rats with alloxan induce diabetes". *Cell. Biochem. Funct.*; 14(2):131-137.
- Burstein, M. (1970):** HDL cholesterol determination after separation high-density lipoprotein. *Lipid .Res.*, 11:58.
- Carrasco-Pozo; K. N. Tan; M. Reyes-Farias et al. (2016):** The deleterious effect of cholesterol and protection by quercetin on mitochondrial bioenergetics of pancreatic  $\beta$ -cells, glycemic control and inflammation: In vitro and in vivo studies," *Redox Biology*, 9: 229–243.
- Chen, V. and Ianuzzo C.D. (1982).** Dosage effect of Streptozotocin on rat tissue enzyme activities and glycogen concentration. *Can J Physiol Pharmacol*: 60: 1251–1256.
- Fossati, P. C. and Principle, L. (1982):** Enzymatic colorimetric determination of total serum triglyceride. *Clin. Chem*; 28:2077.
- Friedewald, W. T.; Leve, R.I. and Fredrickson, D. S. (1972):** Estimation of concentration of low-density lipoprotein separated by three different methods. *Clin. Chem.*, 18:499-502.
- Huan, Y.I.; Hengyang Peng; Xinyue Wu; Xinmei Xu; Tingting Kuang; Jing Zhang; Leilei Du ; and Gang Fan. (2021):** The Therapeutic Effects and Mechanisms of Quercetin on Metabolic Diseases: Pharmacological Data and Clinical Evidence, *Oxidative Medicine and Cellular Longevity*, 1-16.
- Ji Sook Lee, Yong-Jun Cha, Kyung-Hea Lee and Jung-Eun Yim (2016):** Onion peel extract reduces the percentage of body fat in overweight and obese subjects: a 12-week, randomized, double-blind, placebo-controlled study. *Nutrition Research and Practice*; 10 (2):175-181.
- Jung, Ji Young, Yeni Lim, Min Sun Moon, Ji Yeon Kim, and Oran Kwon. (2011):** "Onion Peel Extracts Ameliorate Hyperglycemia and Insulin Resistance in High Fat Diet/Streptozotocin-Induced Diabetic Rats." *Nutrition and Metabolism* 8:1–8.
- Kang, H.J.; Pichiah, P.B.T.; Abinaya, R.V.; Sohn, H.S.; Cha, Y.S. (2016):** Hypocholesterolemic effect of quercetin-rich onion peel extract in C57BL/6J mice fed with high cholesterol diet, *Food Sci. Biotechnol.* 25: 855–860.
- Kang, M.; Kim, J.H.; Choi, H.N.; Kim, M.J.; Han, J.H.; Lee, J.H. and Kim, J.I. (2010):** Hypoglycemic effects of welsh onion in an animal model of diabetes mellitus; 4(6):486–491.
- Kesari, A.N.; Gupta, R.K. and Watal, G. (2005).** Hypoglycemic effects of *Murraya koenigii* on normal and alloxan-diabetic rabbits. *J Ethnopharmacol*; 97(2):247–51.
- Klein, S.; Sheard, N.F.; Pi-Sunyer, X.; Daly, A. and Wylie-Rosett, J. (2004):** American diabetes association. North American association for the study of obesity: American society for clinical nutrition. Weight management through lifestyle modification for the prevention of type 2 diabetes: *Diabetes Care* 27: 2067-2073.
- Kim, J.; Cha, Y.; Lee, KH. And Park, E. (2013):** Effect of onion peel extract supplementation on the lipid profile and antioxidative status of healthy young women: a randomized, placebo-controlled, double-blind, crossover trial. *Nutr Res Pract.* 7(5): 373–379.
- Kim S-H; Jo S-H; Kwon Y-I and Hwang J-K. (2011)** Effects of Onion (*Allium cepa* L.) Extract Administration on Intestinal  $\alpha$ -Glucosidase Activities and Spikes in Postprandial Blood Glucose Levels in SD Rats Model. *Int. J. Mol. Sci.*, 12 (6), 3757-3769.
- Lee, S.-K.; Hwang, J.-Y. and Kang, M.-J. (2008):** Hypoglycemic effect of onion skin extract in animal models of diabetes mellitus. *Food Science and Biotechnology* 17 (1):130-134.
- Manoj, K.; Mrunal, D. Barbhai; Muzaffar, H.; Sneh, P.; Sangram, D. Radha; Nadeem, R.; Deepak, C. Pandiselvam; Anjineyulu, K. ; Maharishi, T.; Varsha, S.; Marisennayya, S. Anitha; Abhijit, D.; Ali A.S. Sayed; Farouk, G.; Ryszard, A. and Mohamed, M. (2022):** Onion (*Allium cepa* L.) peels: A review on bioactive compounds

- and biomedical activities, *Biomedicine & Pharmacotherapy* 146, 112498.
- Mariana Gois Ruivo da Silva; Mihaela Skrt; Drazenka Komes; Natasa Poklar Ulrich and Lea Poga cnik. (2020):** Enhanced Yield of Bioactivities from Onion (*Allium cepa* L.) Skin and Their Antioxidant and Anti- $\alpha$ -Amylase Activities, *Int J Mol Sci.* Apr 21; 21(8):2909.
- Masood Sara; Rehman Attiq ur; Bashir Shahid; Mohamed El Shazly; Muhammad Imran; Palwasha Khalil; Faiza Ifthikar; Hafiza Madiha Jaffar & Tara Khursheed (2021):** Investigation of the anti-hyperglycemic and antioxidant effects of wheat bread supplemented with onion peel extract and onion powder in diabetic rats. *Journal of Diabetes & Metabolic Disorders* 20:485–495.
- Mona Verma; Saroj, S.; Jeet Singh and M.R. Neelam, (2018):** Phytochemical screening of onion skin (*Allium cepa*) dye extract, *Journal of Pharmacognosy and Phytochemistry* 2018; 7(6): 1414-1417.
- Ofoelo, L.I.; Okpashi, V.E.; Nwodo, O.F.C. and Adaora, N. (2017):** Assessment of lipid profile indices of alloxan-induced diabetic rats using *irvingia gabonensis* seeds extracts. *Translational Biomedicine*, 8 (4): 1-4.
- Packia Lekshmi, N.C; Viveka S.; Viswanathan, M.B.; Shobi, T.M.; Jeeva S. and Brindha, J.R. (2015):** High performance thin layer chromatography profile of quercetin in three cultivars of *Allium cepa* and its antimicrobial activity against bacterial cultures. *Asian J Pharm Clin Res*, 8 (3): 213-218.
- Reeves, P.; Nielsen, F. and. Ahmy, G. (1993):** Report of the American Institute of Nutrition; committee on the reformulation of the AIN76, A rodent diet. *J. Nutrition*, 123:1939-51.
- Reitman, S. and Frankel, S.A. (1975):** colorimetric method for the determination of serum glutamate, oxaloacetate and pyruvate transaminase. *Am J Clinical Pathol* 28: 56-63.
- Sara, M.; Attiq, U.R.; Shahid, B.; Muhammad, I.; Palwasha, K.; Tara, K.; Faiza, I.; Hafiza, M. J.; Sana, F.; Bahisht, R. and Nida, J. (2020):** Proximate and Sensory Analysis of Wheat Bread Supplemented with Onion Powder and Onion Peel Extract. *Bioscience Research*, 17(4): 4071-4078.
- SAS, (1996):** "Statistical Analysis System" SAS User's Guide: Statistics. SAS Institute Inc. Editors, Cary, NC.
- Sheehan, D. and Harpachak, B. (1980):** Phory and bractec histotechnology. 2nd Ed. Battle-Press; Ohio.
- Su Jin Yang; Pradeep Paudel; Srijan Shrestha; Su Hui Seong; Hyun Ah Jung and Jae Sue Choi. (2018):** In vitro protein tyrosine phosphatase 1B inhibition and antioxidant property of different onion peel cultivars: A comparative study, *Food Sci Nutr.* 2018; 1–11.
- Suganya; N .S. Dornadula; S. Chatterjee, and R. K. Mohanram, (2018):** Quercetin improves endothelial function in diabetic rats through inhibition of endoplasmic reticulum stress mediated oxidative stress," *European Journal of Pharmacology*, 819: 80–88.
- Trinder, P. J. (1959):** Determination of blood glucose using 4-Aminophenazone. *J. Clin. Path.*, 22:246.
- Yang, J.L.; Suh, M.J. and Song, Y.S. (1996):** Effects of dietary fibers on cholesterol metabolism in cholesterol-fed rats. *J. Korean Soc. Food Nutri*; 1; 25: 392-8.
- Zhang, X.F. and Tan, B.K. (2000).** Antihyperglycemic and anti-oxidant properties of *Andrographis paniculata* in normal and diabetic rats *Clin Exp Pharmacol Physiol*, 27: 358–363.