



PROSTHETIC REHABILITATION OF A COMPLETELY EDENTULOUS PATIENT WITH IMPLANT-SUPPORTED ALL ON FOUR PROSTHESES: A CASE REPORT

**Dr. Prashant Bajantri¹, Dr. Shubham Prince², Dr. Shobha Rodrigues^{3*},
Dr. Thilak Shetty⁴, Dr. Sharon Saldanha⁵, Dr Mahesh M⁶,
Dr. Umesh Pai⁷, Dr Tanay Chawda⁸**

Article History: Received: 19.02.2023

Revised: 07.04.2023

Accepted: 23.05.2023

Abstract

The “all-on-four” design was created to make the most of the remaining bone in atrophic jaws and to permit the fabrication of dental prostheses with up to twelve teeth, to increase masticatory efficiency. This case report highlights the prosthetic rehabilitation of a completely edentulous patient using this concept

Keywords: Implants, All on four, implant, rehabilitation

¹Assistant Professor, Department Of Prosthodontics, Manipal College of Dental Sciences, Mangalore, Manipal Academy of Higher Education, Manipal, Karnataka India

²postgraduate, Department of Prosthodontics, Kothiwal Dental College and Research Center, Moradabad, Uttar Pradesh, India

^{3*}Professor, Department of Prosthodontics, Manipal College of Dental Sciences, Mangalore, Manipal Academy of Higher Education, Manipal, Karnataka India

⁴Professor & Head, Department of Prosthodontics, Manipal College of Dental Sciences, Mangalore, Manipal Academy of Higher Education, Manipal, Karnataka India

^{5,6,7}Associate Professors, Department Of Prosthodontics, Manipal College of Dental Sciences, Mangalore, Manipal Academy of Higher Education, Manipal, Karnataka India

⁸Postgraduate student, Department of Prosthodontics, Manipal College of Dental Sciences, Mangalore, Manipal Academy of Higher Education, Manipal, Karnataka India

Corresponding Author:

Dr. Shobha Rodrigues^{3*},

^{3*}Professor, Department of Prosthodontics, Manipal College of Dental Sciences, MAHE Mangalore 575001 India

Email: ^{3*}shobha.j@manipal.edu

DOI: 10.31838/ecb/2023.12.s3.380

1. Introduction

The “All-on-4” concept and technique was originally advocated by Branemark et al in 1977. In this technique they placed four implants in the anterior region of the mandible and anterior to the sinus in maxillary edentulous area^{1, 2, 3}. The “all-on-four” design was created to make the most of the remaining bone in atrophic jaws and to permit the fabrication of dental prostheses with up to twelve teeth, to increase masticatory efficiency.^{4, 5} Paulo Malo et al. (2003) found “all -on-4” concept to be a great strategy and urged upon its development.^{6,7} The concept was based on the results from load analysis which have demonstrated that 4 implants are an advantageous number. The two distal most implants are angulated distally by maximum 45° to create a more advantageous antero-posterior implant distribution, hence reducing cantilever extensions that might endanger distal implant Osseointegration.⁸

Case report

A 54-year male old patient visited the Department of Prosthodontics with the chief complaint of loose lower denture and wanted a new fixed dental prosthesis. The old dentures were fabricated 3 years prior. Patient was a diabetic which was under control since 10 years. Clinical examination revealed completely edentulous upper and lower arches. Patient’s existing dentures were examined and the existing vertical dimension was found to be adequate.

A CBCT was taken which showed that enough bone was present in height and width for the placement of implants (Fig 1). Bleeding and clotting times were assessed which showed no abnormalities.

A treatment plan was formulated to rehabilitate the upper arch using a conventional complete denture and to place implants in the lower arch using the “All-on-Four” implant concept (Dentium) and to rehabilitate it using a hybrid implant supported prosthesis with immediate loading protocol.

Patient was instructed to take Tab Amoxicillin 500mg, thrice daily, after meals for 5 days, beginning one day before the planned surgical day and extending till completion of the course.

On the day of the surgery, Betadine paint was applied over the patient’s face, followed by administration of Inferior Alveolar, Long Buccal and Lingual nerve blocks of Lignocaine 1:1,00,000 local anesthesia.

From the right first molar area to the left first molar region, a full thickness crestal incision was performed.

To assist flap reflection and detect the left mental nerve emergence, a midline releasing incision was made. an osteotomy of 2 mm diameter was created in the midline position, followed by placement of an [all-on-four guide] (Fig.2). The implant sites were prepared in the right location using the vertical lines on the guide as a reference, with angulations not surpassing 45°. All implant locations were prepared using the manufacturer’s instructions, under constant sterile saline irrigation.

Two straight implants were placed the lateral incisor regions of size 3.6mmx1 mm (Super line, Dentium, Korea) the other two implants with 17-degree angulation of size 3.6mmx12mm (Superline, Dentium, Korea) were placed in the first premolar region mesial to the mental foramen. Primary stability of 35 Ncm was achieved.

0-degree multiunit abutments were secured over the anterior 2 implants and multiunit abutments were secured over the posterior 2 implants. Comfort caps were then secured on these multiunit abutments. Vicryl 3-0 resorbable sutures were placed to obtain closure of the surgical site. Comfort caps were then used to obtain the impression of the implant positions on the intaglio surface of the dentures and holes were made in the denture base at these locations. The comfort caps were then removed from the implants and replaced with temporary cylinders with 10Ncm torque.

Four holes were cut in a rubber dam corresponding to the location of the temporary cylinders and the rubber dam was then placed over the mucosa of the mandible to prevent the flow of acrylic over the multiunit abutments and soft tissues of the mandible.

The denture was placed back into the oral cavity with the help of the holes made into the denture which corresponded to the location temporary cylinders. Auto-polymerizing resin was used to fill the space between the denture and the temporary cylinders, which was then allowed to set.

The temporary cylinders were loosened and the denture along with temporary cylinders was removed. The excess length of the temporary cylinder was removed along with facial and lingual flanges of the denture. The denture was then finished and polished before re-inserting and tightening (10 Ncm) into the patient’s oral cavity. (Fig. 3)

The patient was recalled after 4 months for fabrication of the final prosthesis.

The mandibular interim denture was removed, and the oral mucosa was re-examined.

Impression copings were attached to the multi-unit abutments and dental floss was secured to the impression copings. This was then stabilized by using pattern resin. An OPG was made to verify the fit of the impression copings over the multi-unit abutments. An open tray polyether impression was then made over this assembly.

Implant analogues were attached over the impression copings and a gingival mask was added.

The impression was then poured in dental stone (Gypsum type 3) and a master cast was obtained.

Implant analogues were attached to the multi-unit abutments and a denture base with occlusal rims was fabricated on the master cast for upper and lower arches.

Tentative jaw relation was then performed followed by facebow record and transfer. Centric relation was then recorded and transferred to the articulator followed by teeth arrangement. Denture try in was done followed by investing, dewaxing and curing to obtain the definitive PMMA dentures.

The dentures were inserted into the patient's mouth and evaluated for occlusal interferences. (Fig 4). The lower dentures were then secured to the angulated abutments with 35 Ncm torque. The access channel was covered with PTFE (Polytetrafluoroethylene) tape and sealed using flowable composite material.

2. Discussion

In three aspects, the all-on-four approach is biomechanically advantageous: 1) mandibular integrity is preserved; 2) implant length can be increased; and 3) the V-shape is biomechanically stable.¹¹ The goal of "all-on-four" was to maximize the use of available atrophic bone (particularly in the posterior regions) to permit for immediate functional loading and prevent the need for regenerative treatments (grafts, expansion, etc.) that raise not only the cost of treatment but also the morbidity of tissues and dental implants. The smallest number of implants necessary to sustain a fixed prosthesis, on the other hand, was evaluated for cost savings.

Capelli et al studied the management of edentulous arches using implant-supported fixed prostheses that were loaded immediately and presented distal extensions with straight and leaning implants.⁹ In the mandible two implants were inserted in the interforaminal area and two leaning implants were positioned distally (25-30 degrees). 6 implants were inserted in the maxillary arch, with the posterior implant placed 3 to 4 mm anterior to the maxillary sinus's anterior boundary. An angle of 30 to 35 degrees was used for these implants. Two implants were placed parallel to the midline in the anterior region, and two more implants were placed between them. The authors discovered that maxillary implants had a success rate of 97.59 percent and mandibular implants had a success rate of 100 percent.

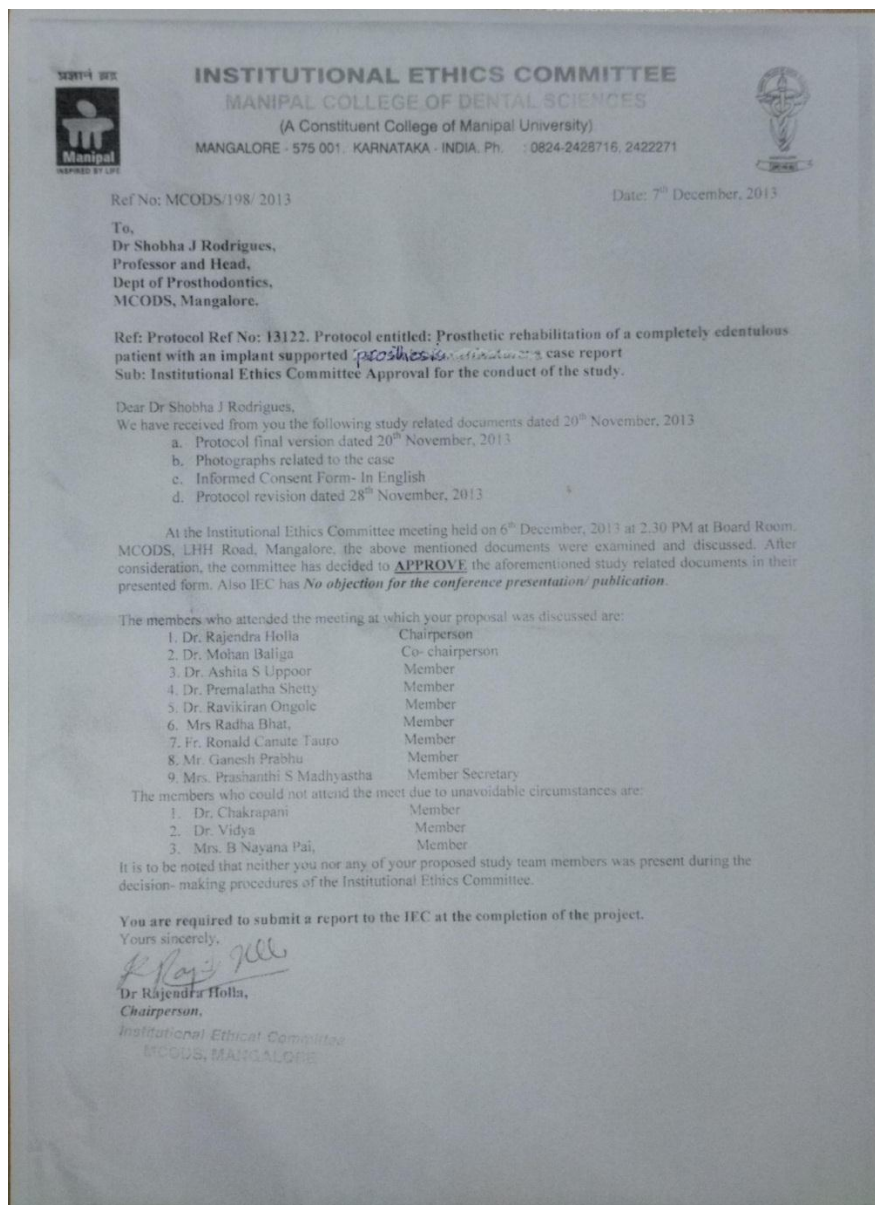
Because of the biomechanical advantage, leaning implants may achieve similar results as straight implants. The use of two leaning implants in the posterior area in conjunction with straight implants in the anterior region increases prosthesis support and shortens the cantilever. Furthermore, the lower implant count enhances passivity.

3. Conclusion

In patients who do not want to undergo regenerative therapies, which enhance morbidity and treatment costs, the all-on-four treatment approach provides a predictable strategy to rehabilitate the atrophic jaw. The findings show a 99.8% survival percentage for implants for more than 24 months. To provide superior primary stability and avoid countersink in cortical bone, the implant bed was under-prepared. To improve accuracy and assure correct placement and angle of distal implants, this procedure can be conducted by guided surgery employing an open flap technique with a metallic surgical guide. Designing the final prosthesis in acrylic resin with or without strengthened titanium or metal framework was preferred.

Conflict of Interest: Nil

Funding Source: Nil



4. References

Misch CE. Dental Implant Prosthetics, Ed 2. St. Louis: Elsevier Mosby, 2015:263, 604, 885.

Turkylmaz I, Company AM, McGlumphy EA. Should edentulous patients be Constrained to removable complete dentures? The use of dental implants to improve the Quality of life for edentulous patients. Gerodontology 2010; 27:3-10.

Silva GC, Mendonca JA, Lopes LR, Landre J Jr. Stress patterns on implants in prostheses supported by four or six implants: A three dimensional finite

element analysis. Int J Oral Maxillofac Implants 2010;25 :239-246.

Malo P, Rangert B, Nobre M. "All-on-Four" immediate-function concept with Branemark System implants for completely edentulous mandibles: a retrospective clinical study. Clin Implant Dent Relat Res. 2003;5:2-9.

Malo P, Friberg B, Polizzi G, Gualini F, Vighagen T, Rangert B. Immediate and early function of Branemark System implants placed in the esthetic zone: a 1-year prospective clinical multicenter study. Clin Implant Dent Relat Res. 2003;5:37-46.

Maló P, Rangert B, Nobre M. All-on-4 Immediate-Function Concept with Brånemark System® Implants for Completely Edentulous Maxillae: A 1-Year Retrospective Clinical Study. *Clin Implant Dent Relat Res.* 2005;7:88-94.

Malo P, De Araujo Nobre M, Lopes A, et al. "All-on-4" immediate function concept for completely edentulous maxillae: a clinical report on the medium (3 years) and long-term (5 years) outcomes. *Clin Implant Dent Relat Res* 2011;14(Suppl 1):139-50.

Horita S, Sugiura T, Yamamoto K, Murakami K, Imai Y, Kirita T. Biomechanical analysis of immediately loaded implants according to the "Allon-Four" concept. *J Prosthodont Res* 2017;61:123-132.

Capelli M, Zuffetti F, Del Fabbro M, et al. Immediate rehabilitation of the completely edentulous jaw with fixed prostheses supported by either upright or tilted implants: a multicenter clinical study. *Int J Oral Maxillofac Implants* 2007;22:639-644

Legends:

1. Figure 1: CBCT image of the patient
2. Figure 2: All on four Guide
3. Figure 3: Temporary denture placed after implant placement
4. Figure 4: Intaglio surface of the finished denture

Fig 1 :CBCT image of the patient

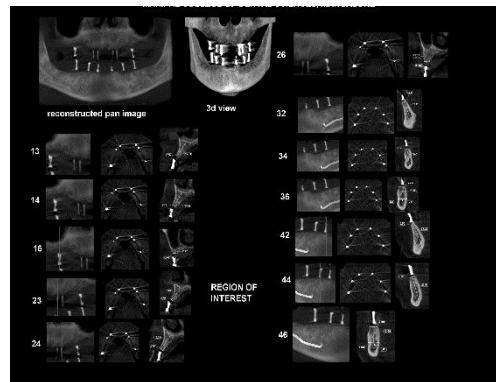


Fig 2 : All on Four Guide

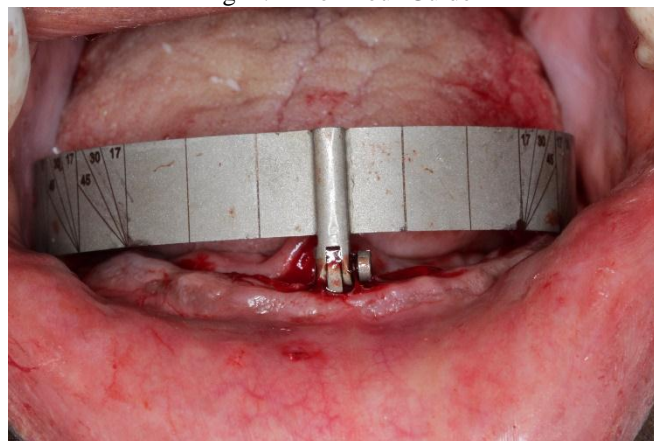


Fig 3 Temporary denture in place after implant placement

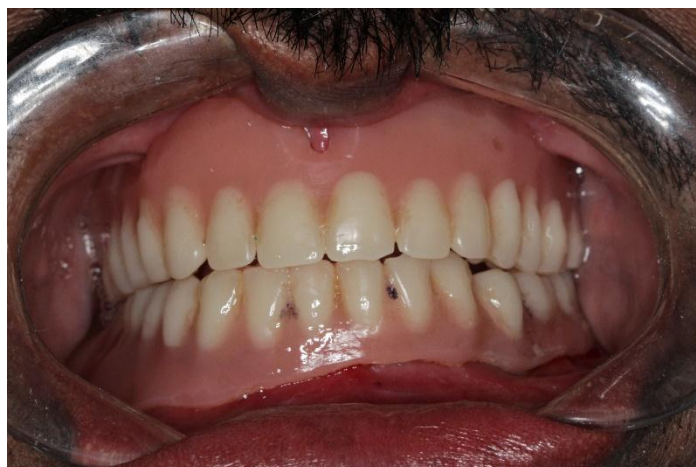

Fig 4: both upper and lower complete denture wax up and trial, Intaglio surface of the denture , upper removable complete and lower fixed implant supported denture insertion

