



# Use of Fractal Dimension analysis as a computational method in the diagnosis of Oral Squamous Cell Carcinoma.

Dr. Ramkumar R<sup>1</sup>, Dr. Nagarathinam AE<sup>2</sup>, Dr Rajkumar K<sup>3</sup>

<sup>1</sup>Post-graduate Student, Department of Oral Pathology, SRM Dental College, Ramapuram, Chennai, Tamil Nadu, India.

<sup>2</sup>Senior Lecturer, Department of Oral Pathology, SRM Dental College, Chennai, Tamil Nadu, India

<sup>3</sup>Professor & Head, Department of Oral Pathology, SRM Dental College, Chennai, Tamil Nadu, India

Corresponding author: **Dr. Nagarathinam AE**, Department of Oral Pathology, SRM Dental College, Ramapuram, Chennai, Tamil Nadu, India ([drnagarathinamae@gmail.com](mailto:drnagarathinamae@gmail.com))

## Abstract:

Fractal Analysis is a method by which geometrical pattern analysis can be done to analyse the pattern seen in any structure. Histopathological diagnosis is the gold-standard diagnosis of most malignancies, including oral squamous cell carcinoma (OSCC), whose incidence and outcome are burdensome for the quality of life of patients. Lack of access to histopathological diagnostic facilities and availability of oral pathologists in rural areas adds to the lacunae of delayed diagnosis and is followed by a poorer outcome of the disease. Developing an AI-image based tool to aid in the diagnosis of oral squamous cell carcinoma will help to overcome several hurdles towards early diagnosis. In our study, we applied the same pattern based analysis in differentiating between normal mucosa and oral squamous cell carcinoma. Our study aimed to evaluate the use of fractal analysis in the diagnosis of oral squamous cell carcinoma (OSCC). Significant differences were observed between the normal and OSCC group, hence fractal count analysis can be used as a computational method in the diagnosis of Oral Squamous Cell Carcinoma.

**Keywords:** Fractal analysis, oral cancer, diagnosis, artificial intelligence, OSCC

## 1. Introduction

In 1975, Mandelbrot introduced the term "fractal" to describe geometric self repeating patterns. Fractal analysis (FA) is a method applied to study these complex geometric structures. Fractal analysis can also be seen as a mathematical model that can be used to analyse any fractal like geometry. Fractal theory offers methods for describing the complexity and irregularity of anatomic structures that comprise organs, tissues, and cells considered to be fractal objects. Fractal objects have properties that include self-similarity, scale independence, complexity, and infinite length or detail. Based on this concept, it is possible to identify the shape and structure of an object that are expressed numerically using fractal dimension (FD).<sup>1</sup> It has been found that many structures of the human body, such as the vessels of the retina, the air channels of the lungs, and the arterial tree of the kidneys, can be regarded as fractal objects. Moreover, fractal geometry is applied in many fields of medicine: in cardiology for heart rate estimation; in neurology for the analysis of changing

patterns in electroencephalograms, in radiology for radiographic analysis and the analysis of mammographic lesions and tomographies.<sup>2</sup> Fractal geometry has found applications in histopathology and cytology, where it has been used for the estimation of the fractal dimensions of several neoplasms, such as carcinomas of the gallbladder, lung, uterus, breast, and larynx.<sup>2</sup>

Oral squamous cell carcinoma(OSCC) is defined as malignant neoplasia of the oral cavity and includes subsites buccal mucosa, floor of mouth, anterior tongue, alveolar ridges, retromolar trigone, hard palate, and inner part of lips . More than 90% of OSCC originates from the squamous tissues, hence widely known as oral cavity squamous cell carcinoma (OCSCC).<sup>3</sup> Histopathological diagnosis is the gold-standard diagnosis of most malignancies, including oral squamous cell carcinoma (OSCC), whose incidence and outcome are burdensome for the quality of life of patients. Lack of access to histopathological diagnostic facilities and availability of oral pathologists in rural areas adds to the lacunae of delayed diagnosis and is followed by a poorer outcome of the disease.<sup>3</sup>

Considering the possibility of interobserver differences when diagnosing malignancies, attempts to automate or employ algorithms to aid diagnosis gain attention. Computer-aided diagnosis, thus, aims at maximizing the reliability of the histopathological assessment (Chan and Tuszynski 2016). The ability to either fully diagnose or allow excluding images with specific features may be of great interest to improve the final diagnosis made by the pathology professional. In this scenario, the identification of parameters that could successfully differentiate cancer images and, thus, aid in the diagnosis are of great interest (Chan and Tuszynski 2016; Angel Arul Jothi and Mary Anita Rajam 2017). Fractal count obtained from processed histopathological images can serve vital in employing a mathematical model for the diagnosis of Oral Squamous cell carcinoma. The fractal dimension (FD) has been employed in several initial works as a possible manner of differentiating malignant tissue in microscopy images.<sup>4</sup>

Although fractal analysis involves a complex concept, we aim here to provide a user-friendly computational protocol able to assess the presence of malignancies in oral cavity tissue slides. The underlying theory of the present work is that the tissue architecture is sufficiently altered during carcinogenesis to be detected by fractal analysis; and can be differentiated from normal mucosa, as the complexity of the tissue is quantifiable with this technique.

## 2. Materials and methods:

**2.1 Sample size and Study Design:** In this retrospective study, histopathological data of diagnosed cases of Oral Squamous cell carcinoma(n=50) and normal mucosa(n=10) that were reported in the Department of Oral Pathology, SRM Dental College, Ramapuram were included for the study. Table 1 shows Demographic Data of OSCC group. The cases included for the study reported from the period 2019-2021. Blocks of the cases were obtained and fresh sections were prepared and slides were stained using haematoxylin and eosin staining method<sup>5</sup>. Fresh staining was done so as to avoid any variability of imaging that will be used for the analysis. The cases were included into the study based on criterias mentioned in Table 2.

<b>Table 1. Demographic Data of OSCC group</b>
--

S.No	Age	Gender	Site	Stage	Type
1	45	Male	Right lateral border of the tongue	T1N0M0	Incisional biopsy
2	54	Male	Left lateral border of tongue	T2N0M0	Excisional biopsy
3	50	Male	Buccal mucosa	T2N1M0	Incisional biopsy
4	40	Male	Right buccal mucosa	T1N0M0	Incisional biopsy
5	84	Female	Left lateral border of tongue	T2N1M0	Incisional biopsy
6	76	Male	Left buccal mucosa	T1N1M0	Incisional biopsy
7	55	Male	Right buccal mucosa	T1N0M0	Excisional biopsy
8	59	Female	Left pterygomandibular raphe	T1N0M0	Incisional biopsy
9	46	Male	Right buccal mucosa	T1N0M0	Incisional biopsy
10	71	Female	Alveolus in relation to left body of the mandible	T3N1M0	Incisional biopsy
11	46	Male	Left cheek region	T1N0M0	Incisional biopsy
12	85	Male	Lingual vestibular mucosa in relation to 38 region	T2N0M0	Excisional biopsy
13	63	Female	Right lateral border of the tongue	T1N0M0	Incisional biopsy
14	65	Female	Floor of the mouth	T2N0M0	Incisional biopsy
15	62	Male	From retromolar region to commisure of lip	T2N0M0	Incisional biopsy
16	75	Male	Left alveolus and buccal mucosa	T2N0M0	Incisional biopsy
17	75	Male	Left alveolar region with buccal vestibule	T1N0M0	Incisional biopsy
18	41	Male	Right lateral border of the tongue	T1N0M0	Incisional biopsy
19	59	Male	Buccal mucosa	T2N0M0	Incisional biopsy
20	60	Male	Left buccal mucosa	T1N0M0	Incisional biopsy
21	56	Male	Tongue	T2N0M0	Incisional biopsy
22	56	Male	Right vestibule and buccal mucosa	T1N1M0	Incisional biopsy
23	48	Male	Left buccal mucosa	T2N0M0	Incisional biopsy
24	62	Female	Right buccal mucosa	T2N1M0	Excisional biopsy
25	64	Male	Left buccal mucosa	T1N1M0	Excisional biopsy
26	55	Female	Left buccal mucosa	T1N0M0	Incisional biopsy
27	59	Male	Right retromolar region	T1N0M0	Excisional biopsy
28	50	Male	Right buccal mucosa	T1N0M0	Incisional biopsy
29	81	Female	Left lateral border of tongue	T2N0M0	Incisional biopsy
30	76	Male	Left buccal mucosa and alveolar ridge	T2N1M0	Incisional biopsy
31	60	Male	Left buccal and lingual vestibule	T1N0M0	Incisional biopsy
32	50	Female	Submental lymph nodes	T1N0M0	Excisional biopsy
33	64	Male	Dorsum of the tongue	T1N0M0	Incisional biopsy
34	40	Male	Left buccal mucosa	T1N0M0	Incisional biopsy
35	72	Male	Right buccal mucosa	T2N0M0	Excisional biopsy
36	67	Male	Lower lip	T1N0M0	Excisional biopsy

37	61	Male	Left side dorsolateral aspect of tongue	T1N0M0	Incisional biopsy
38	35	Female	Right lateral border of the tongue	T1N0M0	Incisional biopsy
39	52	Male	Mandibular molar region involving buccal mucosa	T1N1M0	Incisional biopsy
40	43	Male	Left buccal mucosa	T1N0M0	Excisional biopsy
41	64	Male	Lower buccal mucosa	T1N0M0	Incisional biopsy
42	64	Male	Left buccal mucosa	T1N1M0	Incisional biopsy
43	38	Male	Left buccal vestibule	T1N0M0	Incisional biopsy
44	46	Male	Right border of tongue	T1N0M0	Incisional biopsy
45	45	Male	Right buccal mucosa	T2N0M0	Incisional biopsy
46	54	Male	Left lateral border of tongue	T1N0M0	Incisional biopsy
47	49	Male	Left buccal mucosa	T1N0M0	Incisional biopsy
48	40	Male	Right border of the tongue	T1N0M0	Incisional biopsy
49	86	Female	Labial mucosa in relation to 41 to 37	T2N1M0	Incisional biopsy
50	66	Male	Buccal mucosa	T1N1M0	Incisional biopsy

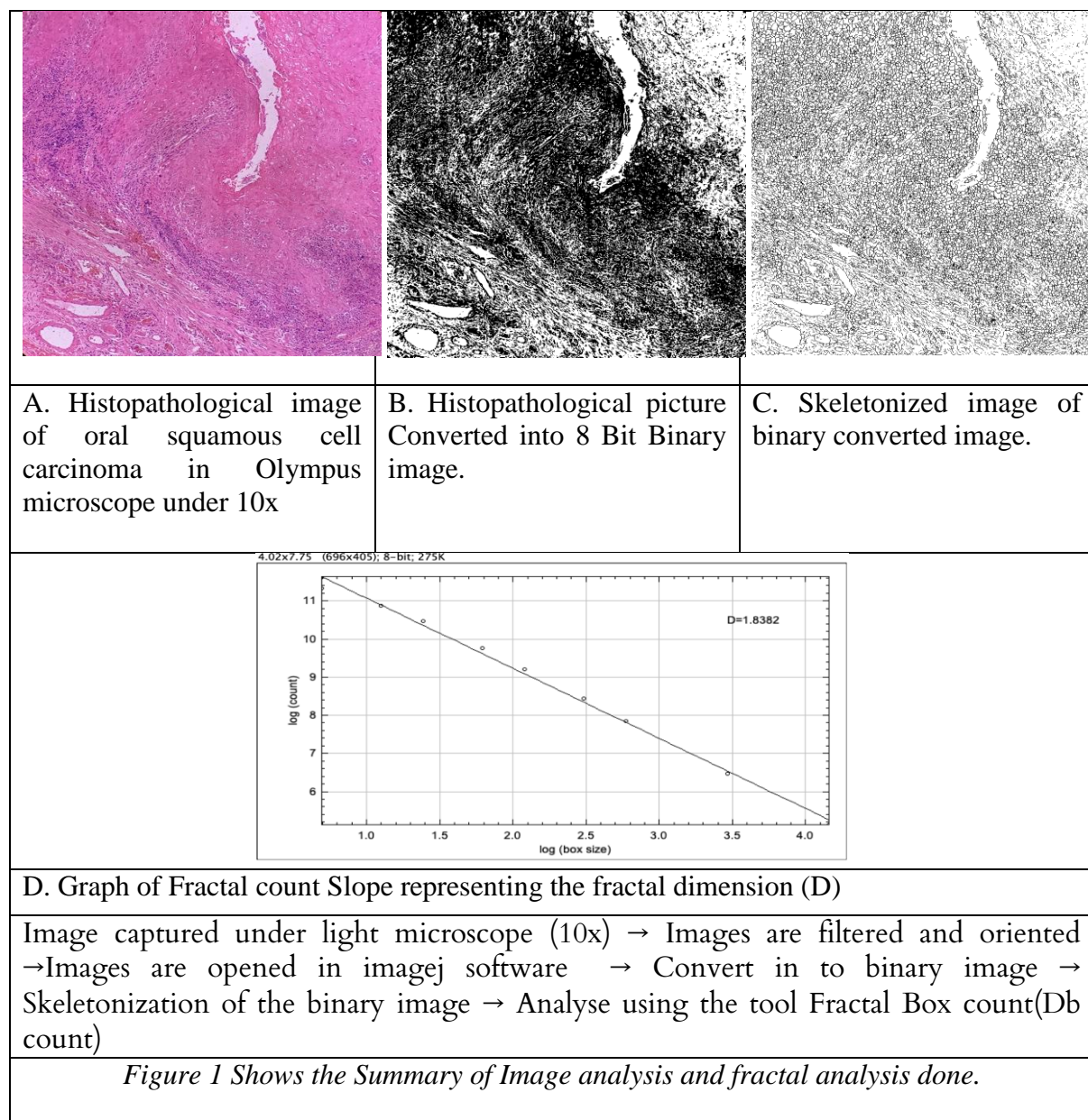
**Table 2. Inclusion and exclusion criteria**

Normal mucosa		Squamous cell carcinoma	
Inclusion	Exclusion	Inclusion	Exclusion
Normal oral ortho or Para keratinized epithelium with connective tissue Without any malignant or dysplastic change	Patients not willing for biopsy procedure. Patients who deny or refuse on informed consent Malignant or dysplastic change Epithelial or connective tissue lesion	Clinically diagnosed and histopathologically confirmed cases as Oral squamous cell carcinoma.	Recurrent cases of Oral squamous cell carcinoma Patients not willing for biopsy procedure. Patients who deny or refuse informed consent.

## 2.2 Image analysis and fractal analysis:

Diagnosis of the cases were confirmed by two observers and the images of the representative field of both OSCC and Normal mucosa were taken in 10x magnification (Olympus Light Microscope) using an Iphone 14 Pro camera. The software used to analyse fractal dimension is imagej (Wayne Rasband and contributors, National Institutes of Health, USA), Java 13.0.6 (64-bit) 4958K of 3000MB (<1%), which was downloaded from the official website '<http://imagej.nih.gov/ij>'. Image processing and filtering were done using ImageJ software. Images were filtered, oriented and then the consent pixels were fixed by uploading into imageJ software. Then the images were converted into 8 Bit Binary images individually, later skeletonized using imageJ software. Finally, the fractal count method in ImageJ software was applied to measure fractal dimension values. Refer Figure 1.





### 3. RESULT:

Statistical Analysis was done using SPSS V22 IBM. Descriptive analysis was done and Student T test was done between the normal and OSCC group. Refer Table 3. The mean Db count in the OSCC (1.762 ±0.032) group was higher than the control group (1.441 ± 0.082) and was found to be statistically significant at p < 0.05.

	<b>OSCC group (n=50)</b>	<b>Normal Group (n=10)</b>
<b>Mean (D -Db count)</b>	1.762	1.441
<b>Median</b>	1.766	1.418
<b>Mode</b>	1.788	1.628

<b>Std. Deviation</b>	0.032	0.082
<b>T-Value</b>	-20.97235	
<b>P value- t test</b>	.000* significant p < .05	

#### 4. Discussion & Conclusion:

Oral cancers were four-fold higher incidence in chewers, two-fold in smokers, and four-fold higher incidence in chewers and smokers both, major risk factors like tobacco, alcohol, and betel quid, several emerging risk factors namely heredity and familial risk, marijuana (cannabis) smoking, khat chewing, medicinal nicotine use, HIV infection, and alcohol containing mouthwashes are likely to be associated with oral cancer.<sup>6</sup> clinical and histological factors have helped in predicting survival in patients with OSCC, there has been need for more specialized diagnostic and prognostic factors. The research has focused on discovering biologic markers, as well as factors related to the morphology of the neoplastic cells and tissues, which can be studied through computer-aided image analysis.<sup>2</sup> Here we used Fractal Dimension analysis as a computational method in the diagnosis of Oral Squamous Cell Carcinoma. In our study we used haematoxylin and eosin stained normal epithelium and oral squamous cell carcinoma tissue for the analysis of fractal dimension.

Fractal analysis is a type of geometrical analysis which can be applied for usage in studying biological patterns as well. Hence, we applied the usage to see if it can be used to differentiate between normal histological tissues and oral squamous cell carcinoma histological tissue. In this study, we measured the DB count of the converted images as mentioned in the methodology; it was observed that the mean DB count of the Oral squamous cell carcinoma was found to be significantly higher than the normal tissues. Although there are several studies that have used fractal analysis in the diagnosis of several pathologies; the same data has not been standardized with a large sample size, image location, quality of the image etc. The database of images generated will also be useful in developing an Artificial Intelligence (AI) based tool for automated diagnosis of Oral squamous cell carcinoma. Iqbal et al revealed that the morphology and complexity of leukoplakia is important in the diagnosis of malignancy potential. This complexity can be effectively determined by Fractal Dimension(FD) analysis. Therefore, it was suggested that FD analysis could be used as a noninvasive, cost effective diagnostic tool for the early detection of malignant conversion. FD values of leukoplakia among participants consuming smoke tobacco also showed higher value in smokers' case than nonsmokers. Studies also implied that fractal geometry could give insights into tumor morphology and could become an useful tool for analyzing irregular tumor growth patterns. Fractal Geometry was proved to be an independent prognostic factor of survival in oral cancer patients. In addition this study provides evidence that there are several statistically significant correlations between fractal geometry and other morphometric characteristics or clinicopathologic factors in oral squamous cell carcinomas. It can be concluded that the FD of Oral Leukoplakia lesions is different in relation to Normal oral mucosa, especially at the level of the epithelium, achieving high diagnostic sensitivity as a diagnostic test. These differences are more pronounced in those lesions with a high degree of dysplasia. In relation to the degree of dysplasia, low-grade dysplasia yields values similar to that of normal oral mucosa.<sup>(6-10)</sup>

The limitations of our study are that hyperplasia and dysplasia cases are not included and need to be evaluated in the future studies and need for further research to address these challenges and improve the accuracy of fractal analysis for Oral squamous cell carcinoma(OSCC). The challenges of the study were the need for higher resolution images and the potential for variability in the results and improved image processing algorithms or machine learning techniques. All the images taken should be oriented and pixelated similarly and should cover similar sites like a part of epithelium and connective tissue. Considering the output obtained, it is possible to hypothesize that Fractal analysis can be used to differentiate

between normal and oral squamous cell carcinoma. It concluded that Fractal analysis can be used for diagnosis of Oral Squamous cell carcinoma. Further, fractal image analysis and artificial intelligence can be combined together to validate the use of automating diagnosis of oral squamous cell carcinoma.

## References

1. Pandey PB, Kandakurti S, Saxena VS, Tripathi P, Pamula R, Yadav M. Fractal analysis in oral leukoplakia. *Journal of Indian Academy of Oral Medicine and Radiology*. 2015 Jul 1;27(3):354.
2. Goutzanis L, Papadogeorgakis N, Pavlopoulos PM, Katti K, Petsinis V, Plochoras I, Pantelidaki C, Kavantzias N, Patsouris E, Alexandridis C. Nuclear fractal dimension as a prognostic factor in oral squamous cell carcinoma. *Oral Oncology*. 2008 Apr 1;44(4):345-53.
3. Chamoli A, Gosavi AS, Shirwadkar UP, Wangdale KV, Behera SK, Kurrey NK, Kalia K, Mandoli A. Overview of oral cavity squamous cell carcinoma: Risk factors, mechanisms, and diagnostics. *Oral Oncology*. 2021 Oct 1;121:105451.
4. Da Silva LG, da Silva Monteiro WR, de Aguiar Moreira TM, Rabelo MA, de Assis EA, de Souza GT. Fractal dimension analysis as an easy computational approach to improve breast cancer histopathological diagnosis. *Applied Microscopy*. 2021 Dec;51(1):1-9.
5. Sheno SR, Peshwani P, Garg A, Moharil R. A study of complexity of oral mucosa using fractal geometry. *Indian Journal of Dental Research*. 2017 Jul 1;28(4):362.
6. Lin WJ, Jiang RS, Wu SH, Chen FJ, Liu SA. Smoking, alcohol, and betel quid and oral cancer: a prospective cohort study. *J Oncol*. 2011;2011:525976. Doi: 10.1155/2011/525976. Epub 2011 Mar 17. PMID: 21547265; PMCID: PMC3087410.
7. Iqbal J, Patil R, Khanna V, Tripathi A, Singh V, Munshi MAI, Tiwari R. Role of fractal analysis in detection of dysplasia in potentially malignant disorders. *J Family Med Prim Care*. 2020 May 31;9(5):2448-2453.
8. Mincione G, Di Nicola M, Di Marcantonio MC, Muraro R, Piattelli A, Rubini C, Penitente E, Piccirilli M, Aprile G, Perrotti V, Artese L. Nuclear fractal dimension in oral squamous cell carcinoma: a novel method for the evaluation of grading, staging, and survival. *J Oral Pathol Med*. 2015 Oct;44(9):680-4
9. Goutzanis L, Papadogeorgakis N, Pavlopoulos PM, Katti K, Petsinis V, Plochoras I, Pantelidaki C, Kavantzias N, Patsouris E, Alexandridis C. Nuclear fractal dimension as a prognostic factor in oral squamous cell carcinoma. *Oral Oncol*. 2008 Apr;44(4):345-53.
10. Guerrero-Sánchez Y, Gómez García F, Chamorro-Petronacci CM, Suárez-Peñaranda JM, Pérez-Sayáns M. Use of the Fractal Dimension to Differentiate Epithelium and Connective Tissue in Oral Leukoplakias. *Cancers (Basel)*. 2022 May 30;14(11):2697.