



CESAREAN SECTION SCAR DEFECT (NICHE): ETIOLOGY, CLASSIFICATION, DIAGNOSIS AND MANAGEMENT

Dahlia El-Haieg¹, Eman Elgindy², Soha Galal³, Rana Attia^{4*}

Article History: Received: 26.06.2023

Revised: 04.07.2023

Accepted: 24.07.2023

Abstract

Increasing cesarean section rates have led to an increased awareness of associated complications such as the formation of cesarean scar niche, defined as an indentation at the site of the cesarean scar with a depth of at least 2 mm, diagnosed by ultrasound or magnetic resonance imaging. The precise prevalence of cesarean scar niche is unclear. The cause of a cesarean scar niche appears to be multifactorial and likely a combination of technical factors (low incision location), anatomical factors (uterine retroflexion), and patient factors, which might impair healing (body mass index, smoking, maternal age). Most patients with cesarean scar niche are asymptomatic; however, women can present with postmenstrual bleeding, pelvic pain, and subfertility. In pregnancy, cesarean scar niches have been associated with placenta accreta spectrum disorder and uterine rupture. Treatment should be reserved for symptomatic women. Hormonal treatment using either the combined oral contraceptive pill or a progesterone-containing intrauterine device may address irregular vaginal bleeding. Surgical management should be reserved for those in whom hormonal manipulation has failed or is contraindicated. The aim of this review was to summarize current literature pertaining to the cause, prevalence, diagnosis, and symptoms of cesarean scar niche and to make recommendations for managing this relatively new condition.

Keywords: Cesarean section, scar defect, Niche.

^{1,2,3,4}Obstetrics & Gynecology Department, Faculty of Medicine, Zagazig University

***Corresponding Author:** Rana Nabil Mohammed Attia

*Obstetrics & Gynecology Department, Faculty of Medicine, Zagazig University,

Email: Rananabil51@gmail.com

DOI: 10.53555/ecb/2023.12.1046

Introduction.

A Cesarean section scar niche is defined as “an indentation at the site of the uterine cesarean scar with a depth of at least 2 mm on ultrasound” (1). The term ‘niche’ describes the presence of a hypoechoic area within the myometrium of the lower uterine segment, reflecting the discontinuation of the myometrium at the site of a previous CS (2)

Cesarean section rates are rising worldwide. The rise is due to an increase in the primary Caesarean section. Cesarean section maternal requests have increased (3). CS is a safe procedure that can be lifesaving for both mother and fetus, but the increasing rate leads to an increase in the cesarean section niche in 56–84% of women after one or more CSs (4).

Etiology of Cesarean Scar Niche:

There have been many theories about the possible etiologies of niche development, such as:

1- Ischemia and Mal-Apposition Hypothesis for CS Niche:

It has been suggested that ischemia is a cornerstone factor in the development of niches, so any surgical maneuver that may induce ischemia would lead to niche development. (5). Using locking, ischemic hemostatic sutures like transverse mattress, single layer instead of a double layer of closure, and decidual sparing technique, all these factors may induce ischemia and consequently cause niche development (6).

Another factor of niche development is the maloposition of the myometrium. for example, eversion of the edges especially in first-time cesarean section, or using a second layer in the uterus after full thickness closure of the hysterotomy incision using inverting lambert sutures 1cm in the healthy myometrium to cover the first layer of incision with moderate tension. (7)

2- non-closure of deeper myometrial layers:

The second hypothesis is that partial closure of the uterine wall during CS, due to the omission of closing the deeper muscular layer, may subsequently lead to disrupted myometrium and thus niche development. Potential causes include superficial closure due to non-perpendicular (tangential) sutures and endometrial-saving techniques (6).

3- Single vs double layer closure of the hysterotomy incision

A systematic review and meta-analysis of the uterine closure technique were published,

concluding a beneficial effect of double-layer non-locking uterine sutures in the prevention of the cesarean niche (8).

4- Hypothesis of Cervical Location of Cesarean Incision Leading to Niche:

The Hypothesis of the scar's cervical location was built upon the observation of a mucoid-filled niche by hysteroscopy and laparoscopy. This means that a low incision reaches down to the cervix as in cases of bladder flap formation and incision behind the scar and upon observation that large niche is usually a low niche. (9) So it is recommended by NICE guidelines not to create a bladder flap and to open 2 finger breadths above the bladder reflection to avoid low incision. (10).

5- Hypothesis of Dense Adhesions Following Some Surgical Techniques:

It has been noticed that during laparoscopic repair of the niche, there are many cases where there was dense adhesion between the bladder and niche and between the niche and the abdominal wall which may exert traction on the scar causing the scar to expand to form a niche. Also, they noticed that in a considerable number of cases the uterus is retroflexed but whether the retroflexion exerts tension on the scar leading to niche formation or weak scar with niche leading the uterus to retroflex is not known (11).

6- Patient-Specific Factors Impairing Uterine Wound Healing:

A study of 371 cases showed that there are many independent risk factors for niche development such as advanced maternal age, BMI, a history of GDM, an increasing number of cesarean deliveries, emergency Cesarean section, longer duration of active labor, and Peripartum infections (12)

Obstetric Sequelae Associated with Cesarean Scar Niche:

Although a Cesarean section is sometimes a lifesaving intervention, it is important to investigate its further influence on women's health. A spectrum of disorders starts with cesarean scar (CS) ectopic pregnancy, increased incidence of placenta previa, and placenta accreta associated with significant maternal morbidity and even mortality (13).

A Cesarean scar pregnancy is a pregnancy located at the site of a niche, outside the uterine cavity, and is surrounded by myometrium or fibrous tissue of the scar (14). It can lead to uterine scar rupture and life-threatening hemorrhage; in

particular, if a vacuum curettage is performed in case it is misdiagnosed as a miscarriage in progress (15). Niche also may be a result or a cause of abnormal placentation leading to placenta previa and accreta (16).

Uterine scar dehiscence may present as an acute event in the antenatal or intrapartum period, leading to significant fetal and maternal morbidity. The frequency of uterine rupture is estimated at 0.2–3.8% and that of uterine dehiscence is between 0.6 and 3.8%. (17).

The presence of a niche alone should not be considered a risk factor for uterine rupture during a future pregnancy. The residual myometrium thickness is the most useful discriminating measurement in the evaluation of isthmocele. Some authors have proposed a cutoff of residual myometrium for the risk of uterine rupture, varying between 2.5 mm and 3 mm. (18).

Gynecological Sequelae Associated with Cesarean Scar Niche:

The presence of a niche is associated with multiple symptoms: abnormal uterine bleeding (AUB), e.g., prolonged menstruation and postmenstrual spotting, is present in 30% of women with a niche (4). Other symptoms include dysmenorrhea and chronic pelvic pain (19). Furthermore, the retention of blood, mucus, and fluid in the niche, cervix, and uterus are hypothesized to be a cause of secondary subfertility, due to unsuccessful sperm cell penetration or embryo implantation (6).

a) Postmenstrual spotting

The most common symptom in women with cesarean niche is postmenstrual spotting or prolonged menstruation, due to retention of menstrual debris in the niche cavity. Postmenstrual spotting and bleeding are defined by FIGO as any bleeding or spotting after 8 days of menses for at least 1 day while intermenstrual bleeding is defined as spontaneous bleeding that occurs between two menstrual periods which may be cyclic or random. (20)

b) Dyspareunia /chronic pelvic pain

Niche-related pain and dyspareunia have also been reported. The size of the niche is important with larger niches being more likely to present with pain and more likely to be complicated by anterior adhesions to the bladder and abdominal wall. (21). Lymphocytic infiltration (65%) and distortion of the lower uterine segment (75%) could contribute to chronic pelvic pain and dyspareunia. (22).

c) Sub/infertility:

Cesarean sections may lead to reduced fertility. A population cohort study reported that women who underwent a Caesarean section had a lower pregnancy rate (4–19%) compared to women who had a vaginal delivery (23).

Various explanations have been proposed, ranging from placental bed disruption or pelvic adhesions (24). Women with a higher maternal age have a higher risk of having a Caesarean delivery than younger women (25). From the pathophysiological point of view, it seems reasonable that the fluid accumulation in the isthmocele is the result of poor contractility of the fibrotic tissue and of the surrounding uterine muscular tissue in the CS scar region (26).

Mechanisms of CS niche-related impaired fertility:

1- Accumulation of intrauterine fluid impairing implantation:

It is hypothesized that the accumulation of intracavitary fluid related to the niche may impair embryo implantation, which is in line with the known negative effect of intrauterine fluid in women with hydrosalpinx (27). Accumulation of fluid is seen in approximately 42% of patients with a large niche. This may impair pregnancy outcomes due to reduced implantation yet may also be embryotoxic (28).

2- Altered immunobiology and/or increased inflammation:

A study assessing immunology using histology found changes and noted that the most significant alterations at the scar site were fewer leucocytes and less vascularization than in the endometrium of the unscarred uterus (29).

3- Distorted contractility of the uterus:

Contractile waves from the fundus to the cervix are seen in the follicular phase and they disappear after ovulation or hCG administration. The pattern is reversed in the luteal phase. It recurs similarly from cycle to cycle (30).

An observational prospective study reported a significant decrease in muscular density in the myometrium covering the defect compared with the adjacent myometrium on histological exams after laparoscopic repair; it is possible that in women with a niche, normal wave patterns are disturbed by uncoordinated or impaired uterine contractions during the menstrual cycle, which could lead to a lower implantation rate. (31).

4- Accumulation of mucus and old blood in the niche:

Mucous and altered blood is accumulated in the cesarean scar defect which impairs penetration of sperms and thus embryo implantation. The presence of blood in the cervix may cause impaired sperm-mucus interaction for immunological reasons. This cervical hostility was defined in terms of an abnormal or negative postcoital test (32)

5- Strongly retroflexed uterus impairs accessibility for embryo transfer:

Sometimes a niche in combination with a strongly retroflexed uterus and/or a complex niche may hamper the insertion of an insemination or embryo transfer catheter. In rare cases, even under ultrasound guidance, it is impossible to enter the uterine cavity. In such cases, a laparoscopic niche resection to restore the anatomy for embryo transfer could be considered (11).

6- Gynecological symptoms may interfere with sexual intercourse:

Some studies report a negative association between abnormal uterine bleeding or spotting and the sexual behavior of both men and women. The presence of vaginal bleeding or spotting is associated with a decrease in genital sexual behaviors (33).

Classification and Diagnosis:

1) Ultrasound

➤ Transvaginal ultrasound

TVS can detect cesarean niche in 50% of women with previous cesarean section but has limitations in being operator dependent, with variable endometrial appearances at various times of the menstrual cycle, as well as during hormone therapy. (34). Cesarean niche is best demonstrated using contrast-enhanced ultrasound, with higher detection rates compared with TVS. (35).

Although there is no standardized guideline for the examination of CS scar nice measurement, or description. A niche can be examined using two- (2D) or three- (3D) dimensional transvaginal sonography (TVS), with or without saline or gel contrast, magnetic resonance imaging, and hysteroscopy (36).

In 2019, 15 cesarean niche experts from the European Niche Taskforce participated in the Delphi procedure to make a standardized method of defining and measuring a niche, with a focus on clinical relevance. (1).

Most (83%) experts agreed that a niche is **an indentation at the site of the CS scar with a depth of at least 2 mm**. A niche can be sub-classified into:

- (1) Simple niche
- (2) Simple niche with one branch
- (3) Complex niche (with more than one branch)(1).

Methods of measurement:

- In the sagittal plane, the niche length and depth, residual, and adjacent myometrial thicknesses are measured. The depth of the niche is measured, starting from the uterine cavity to the apex of the niche. The residual myometrium is measured from the apex of the niche to the serosa, and this is crucial in planning surgery. In the transverse plane, the width of the niche is measured, and any branches can be assessed. If branches are present, these should also be investigated with additional measurements.
- Clinically relevant measurements of the niche include length, depth, residual myometrial thickness (RMT), width, AMT, the distance between the niche and the vesicovaginal (VV) fold, and the distance between the niche and the external os. 100% of the experts agreed that length, depth, and RMT should be measured in the sagittal plane.
- Measurement of the adjacent myometrial thickness (AMT) was agreed to be relevant in clinical practice (92% agreement).
- For simple niches, all measurements can be done in a single plane, while, for complex niches, more than one plane may be necessary.
- It is useful to vary pressure with the transvaginal probe to achieve the best plane for niche measurement. The use of Doppler imaging is not mandatory in standard niche measurement. Contrast sonography has added value in patients with uterine niche. There is no preference for either gel or saline. There is no preference for a catheter used in contrast sonography. (1). (fig 1)

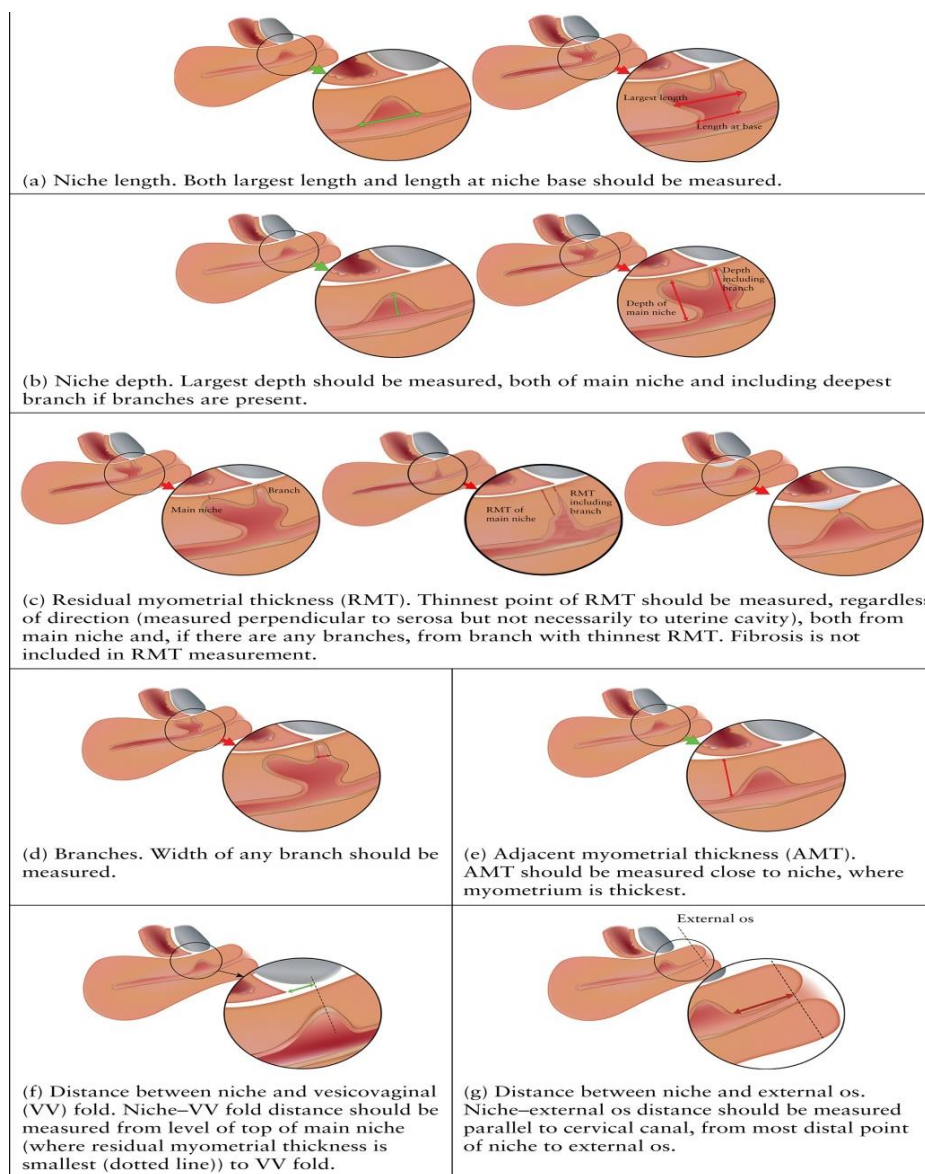


Figure (1) Position of calipers for different sonographic measurements of uterine niche in the sagittal plane (1)

➤ **Sonohysterography:**

Since saline infusion SHG was first described it has been widely used to assess the uterine cavity in patients with suspected endometrial or intracavitary disease for whom the TVUS might not give a defined diagnosis. Moreover, SHG increases the sensitivity and specificity for the detection of CS scars by enhancing the defect(37). The prevalence of cesarean scar defects is higher in SHG compared with TVUS (56–84% versus 24–70%), and the defect is deeper or larger in the SHG. The increased prevalence and scar size, when using SHG, is due to an exaggeration of the size of the defect caused by the increased intrauterine pressure (38).

GIS is the gold standard for assessing a niche, but, in the presence of fluid in the niche on ultrasound, this was not needed. It was recognized that since fluid is commonly seen during the mid-follicular phase, niche evaluation should be done between

days 7 and 14 of the cycle. This would obviate the need for additional gel or saline instillation (1).

➤ **Other imaging:**

Isthmocele may also be diagnosed by hysterosalpingography as an extension of contrast into the myometrial defect at the site of a previous cesarean hysterotomy. (21)

Magnetic resonance imaging is useful to evaluate the thickness of the lower uterine segment, the depth of the isthmocele, and the content of the endometrial and defect cavities(38).

2) Endoscopy:

A cesarean niche can be identified under direct vision in hysteroscopy and laparoscopy. A variety of hysteroscopic appearances of the niche have been described, including concavities in the isthmus with a prominent distal ridge, lateral branches, the presence of abnormal vascular

patterns, and the presence of cyst-like or polypoid structures. (39).

Laparoscopy shows ballooning of the lower segment often associated with dense adhesions to the bladder or anterior abdominal wall. Recognizing such pattern is important for proper documentation of defects in women being investigated for gynecological symptoms. (11).

Management of cesarean niche-related symptoms:

Different methods have been implemented to treat niche-related problems. Although niche-related symptoms are not life-threatening consequences after CS, they can cause long-term morbidity and might therefore have a serious impact on quality of life (QoL). (39).

I. Medical Treatment

Oral contraceptive pills might represent a valid option for symptomatic women who do not want to get pregnant and prefer conservative therapy (40).

II. Hysteroscopy

The essential parameter to perform hysteroscopy is the residual myometrial thickness. Whereas with the hysteroscopic approach, there is a risk of bladder injury and uterine perforation if the myometrium thickness at the site of the defect is < 3 mm. There is a good outcome regarding symptoms including postmenstrual spotting (41). Good outcomes were also found regarding infertility patients, most of them conceived spontaneously between 12 and 24 months after the isthmoplasty (42).

III. Vaginal Repair

Isthmocele transvaginal repair is comparably effective to laparoscopic repair, but the surgical time is significantly shorter, and the hospitalization expenses are lower in transvaginal repair. However vaginal surgery on undescended uterus needs special surgical skills and good instrumentation (43).

IV. Laparotomy

Laparotomy correction was successful in relieving postmenstrual spotting and abdominal pain, also the pregnancy rate increased to 71% following the laparotomy procedure. (44)

V. Laparoscopy

Laparoscopy is a technique that has to be preferred especially if the residual myometrial thickness is < 3 mm (39) A skilled laparoscopic surgeon can use conventional laparoscopy or

robotic-assisted surgery to correct the isthmocele. (38)

Surgical correction of niche for the management of secondary infertility:

Niche as a reason for secondary infertility has attracted the attention of many clinicians as many cases presented with secondary infertility are associated with niche, however, whether to treat or not before IVF is still a debatable issue that so many trials are ongoing or study niche and its effect on IVF outcome (28).

Early reports on fertility outcomes following niche surgery appear promising. but there is a statistically significant improvement in menstrual symptoms resulting from more favorable niche characteristics after surgery, it could be presumed to improve niche-related subfertility as well (45).

Surgical repair of an isthmocele may be indicated for patients who wish to conceive or who are symptomatic, but to date, no technique has been proven to be superior and the patient should be counseled pre-operatively regarding all treatment options (46).

Systematic reviews to date have found insufficient evidence to recommend surgery for the management of secondary infertility as the sole symptom of an isthmocele (47). Based on the available data, surgical correction of a cesarean scar defect, particularly through hysteroscopy when the RMT is adequate, appears to be appropriate for the treatment of isolated secondary infertility (48).

References

1. **Jordans IPM, de Leeuw RA, Stegwee SI, et al.** Sonographic examination of uterine niche in non-pregnant women: a modified Delphi procedure. *Ultrasound Obstet Gynecol.* 2019; 53: 107-115.
2. **Naji O, Abdallah Y, Bij De Vaate AJ, Smith A, Pexsters A, Stalder C, McIndoe A, Ghaem-Maghani S, Lees C, Brolmann HA, Huirne JA, Timmerman D, Bourne T.** Standardized approach for imaging and measuring Cesarean section scars using ultrasonography. *Ultrasound Obstet Gynecol* 2012; 39: 252–259.
3. **Mylonas I, Friese K.** Indications for and risks of elective cesarean section. *Dtsch Arztebl Int* 2015; 112: 489–495.
4. **Bij de Vaate, A. J., van der Voet, L. F., Naji, O., Witmer, M., Veersema, S., Brolmann, H. A., et al.** Prevalence, potential risk factors for development and symptoms related to the

- presence of uterine niches following Cesarean section: Systematic review. *Ultrasound in Obstetrics and Gynecology*, 2014. 43(4), 372–382.
5. **Sholapurkar SL.** Etiology of Cesarean Uterine Scar Defect (Niche): Detailed Critical Analysis of Hypotheses and Prevention Strategies and Peritoneal Closure Debate. *J Clin Med Res.* 2018 Mar;10(3):166-173.
 6. **Vervoort AJ, Uittenbogaard LB, Hehenkamp WJ et al.** Why do niches develop in caesarean uterine scars? Hypotheses on the etiology of niche development. *Hum Reprod* 2015; 30:2695–2702.
 7. **Sholapurkar SL.** Surgical techniques at caesarean might modify placenta accreta risk. *BJOG.* 2015;122(1):143.
 8. **Stegwee SI, Jordans I, van der Voet LF, et al.,** Uterine caesarean closure techniques affect ultrasound findings and maternal outcomes: a systematic review and meta-analysis. *BJOG.* (2018). Aug;125(9):1097-1108
 9. **Osser OV, Jokubkiene L, Valentin L.** Cesarean section scar defects: agreement between transvaginal sonographic findings with and without saline contrast enhancement. *Ultrasound Obstet Gynecol* 2010; 35:75–83.
 10. **NICE guideline [NG192], 2021.** Cesarean birth, Published: 31 March
 11. **Vervoort A, Vissers J, Hehenkamp W, Brolmann H, Huirne J.** The effect of laparoscopic resection of large niches in the uterine Caesarean scar on symptoms, ultrasound findings and quality of life: a prospective cohort study. *BJOG* 2018b; 125:317–325.
 12. **Antila-Langsjo RM, Maenpaa JU, Huhtala HS, Tomas EI, Staff SM.** Cesarean scar defect: a prospective study on risk factors. *Am J Obstet Gynecol* 2018; **219:458.** e1–458. e.
 13. **Sholapurkar SL.** Etiology of Cesarean Uterine Scar Defect (Niche): Detailed Critical Analysis of Hypotheses and Prevention Strategies and Peritoneal Closure Debate. *J Clin Med Res.* 2018 Mar;10(3):166-173.
 14. **Mahgoub S, Gabriele V, Faller E et al.** Cesarean scar ectopic pregnancy. Laparoscopic resection and total scar dehiscence repair. A case report. *J Minim Invasive Gynecol.* 2018; 25: 297-298.
 15. **Litwicka K, Greco E.** Cesarean scar pregnancy: a review of management options. *Curr Opin Obstet Gynecol* 2013; 25:456–461.
 16. **Mascarello KC, Horta BL, Silveira MF.** Maternal complications and cesarean section without indication: systematic review and meta-analysis. *Rev Saude Publica.* 2017. ;51:105.
 17. **Khan, F.K., Khurshid, S., Zafar, S., Zanaib, S., Zakria, M. and Asif, S.,** Scar Dehiscence in Patients Presenting with Scar Tenderness Due to Previous One Cesarean Section. *Journal of the Society of Obstetrics and Gynecologists of Pakistan,* 2019. 9(4), pp.243-246.
 18. **Swift, B.E., Shah, P.S. and Farine, D.,** Sonographic lower uterine segment thickness after prior cesarean section to predict uterine rupture: A systematic review and meta-analysis. *Acta obstetrica et gynecologica Scandinavica,* 2019. 98(7), pp.830-841.
 19. **Wang CB, Chiu WW, Lee CY, Sun YL, Lin YH, Tseng CJ.** Cesarean scar defect: correlation between cesarean section number, defect size, clinical symptoms, and uterine position. *Ultrasound Obstet Gynecol* 2009; **34:85–89.**
 20. **MUNRO, M.G.,** Abnormal uterine bleeding 24. *Reconstructive and Reproductive Surgery in Gynecology: 2018.* Two Volume Set, p.341.
 21. **Tulandi T, Cohen A.** Emerging manifestations of cesarean scar defect in reproductive-aged women. *J Minim Invasive Gynecol* 2016; 23: 893– 902.v
 22. **Alshiemy, R.I., Eid, S.M. and El Karef, A.A.,** Assessment of Cesarean Section Niche Histopathologically after Hysterectomy in Symptomatic Patients. *Life Science Journal,* 2014. 11(10).
 23. **Gurol-Urganci I, Cromwell DA, Mahmood TA, van der Meulen JH, Templeton A.** A population-based cohort study of the effect of Caesarean section on subsequent fertility. *Hum Reprod* 2014; 29:1320–1326.
 24. **Murphy DJ, Stirrat GM, Heron J.** The relationship between caesarean section and subfertility in a population-based sample of 14 541 pregnancies. *Hum Reprod* 2002; 17:1914–1917.
 25. **Khalil, A., Syngelaki, A., Maiz, N., Zinevich, Y., & Nicolaides, K. H. (2013).** Maternal age and adverse pregnancy outcome: a cohort study. *Ultrasound in Obstetrics & Gynecology,* 42(6), 634-643.
 26. **Fabres C, Arriagada P, Fern'andez C, Mackenna A, Zegers F, Fern'andez E.** Surgical treatment, and follow-up of women with intermenstrual bleeding due to cesarean section scar defect. *J Minim Invasive Gynecol* 2005; **12:25–28.**
 27. **Akman MA, Erden HF, Bahceci M.** Endometrial fluid visualized through ultrasonography during ovarian stimulation in

- IVF cycles impairs the outcome in tubal factor, but not PCOS, patients. *Hum. Reprod*; **2005**. 20:906–909.
28. **Vissers J, Sluckin TC, van Driel-Delprat CCR, Schats R, Groot CJM, Lambalk CB, Twisk JWR, Huirne JAF.** Reduced pregnancy and live birth rates after in vitro fertilization in women with previous caesarean section: a retrospective cohort study. *Hum Reprod*. 2020;35(3):595–604.
 29. **Ben-Nagi J, Walker A, Jurkovic D, Yazbek J, Aplin JD.** Effect of cesarean delivery on the endometrium. *Int J Gynaecol Obstet* 2009; 106:30–34.
 30. **Sammali F, Kuijsters NPM, Huang Y, Blank C, Rabotti C, Schoot BC, Mischi M.** Dedicated ultrasound speckle tracking for quantitative analysis of uterine motion outside pregnancy. *IEEE Trans Ultrasound Ferroelectr Freq Control* 2019; 66:581–590.
 31. **Donnez O, Donnez J, Orellana R, Dolmans MM.** Gynecological and obstetrical outcomes after laparoscopic repair of a cesarean scar defect in a series of 38 women. *Fertil Steril* 2017; 107:289–296.e2.
 32. **Steures P, van der Steeg JW, Hompes PG, Bossuyt PM, Habbema JD, Eijkemans MJ, Koks CA, Boudrez P, van der Veen F, Mol BW.** The additional value of ovarian hyperstimulation in intrauterine insemination for couples with an abnormal postcoital test and a poor prognosis: a randomized clinical trial. *Fertil Steril* 2007;88: 1618–1624.
 33. **Davis AR, Nowygrod S, Shabsigh R, Westhoff C.** The influence of vaginal bleeding on the sexual behavior of urban, Hispanic women and men. *Contraception* 2002; 65:351–355.
 34. **Bij de Vaate AJM, Br olmann HAM, van der Voet LF, van der Slikke JW, Veersema S, Huirne JAF.** Ultrasound evaluation of the Cesarean scar: relation between a niche and postmenstrual spotting. *Ultrasound Obstet Gynecol* 2011; 37:93–9.
 35. **van der Voet LF, Jordans IPM, Brolmann HAM, Veersema S, Huirne JAF.** Changes in the uterine scar during the first year after a Caesarean section: a prospective longitudinal study. *Gynecol Obstet Invest* 2018; 83: 164–170.
 36. **Baranov A, Gunnarsson G, Salvesen KA, Isberg PE, Vikhareva O.** Assessment of Cesarean hysterotomy scar in non-pregnant women: reliability of transvaginal sonography with and without contrast enhancement. *Ultrasound Obstet Gynecol* 2016; 47: 499–505.
 37. **Tower AM, Frishman GN.** Cesarean scar defects: an underrecognized cause of abnormal uterine bleeding and other gynecologic complications. *J Minim Invasive Gynecol* 2013; 20:562–72.
 38. **Setubal A, Alves J, Os rio F, et al.** Treatment for uterine isthmocele, a pouch-like defect at the site of cesarean section scar. *J Minim Invasive Gynecol* 2018;25(01):38–46 Doi: 10.1016/j.jmig.2017.09.022
 39. **Vervoort, A, van der Voet, LF, Hehenkamp, W, Thurkow, AL, van Kesteren, PJ, Quartero, H, et al.** Hysteroscopic resection of a uterine caesarean scar defect (niche) in women with postmenstrual spotting: a randomized controlled trial. *BJOG* 2018; 125:326–34.
 40. **Iannone, Piergiorgio, Giulia Nencini, Gloria Bonaccorsi, Ruby Martinello, Giovanni Pontrelli, Marco Scioscia, Luigi Nappi, Pantaleo Greco, and Gennaro Scutiero.** "Isthmocele: from risk factors to management." *Revista Brasileira de Ginecologia e Obstetr cia* 41 (2019): 44-52.
 41. **Abacjew-Chmylko A, Wydra DG, Olszewska H.** Hysteroscopy in the treatment of uterine cesarean section scar diverticulum: A systematic review. *Adv Med Sci*; **2017**. 62(02):230–239
 42. **Gubbini G, Casadio P, Marra E.** Resectoscopic correction of the "isthmocele" in women with postmenstrual abnormal uterine bleeding and secondary infertility. *J Minim Invasive Gynecol* 2008;15(02):172–175 Doi: 10.1016/j.jmig.2007.10.004.
 43. **Zhang X, Yang M, Wang Q, Chen J, Ding J, Hua K.** Prospective evaluation of five methods used to treat cesarean scar defects. *Int J Gynaecol Obstet* 2016;134(03):336–339
 44. **Jeremy B, Bonneau C, Guillo E, et al.** [Uterine isthmique transmural hernia: results of its repair on symptoms and fertility]. *Gyn col Obst t Fertil* 2013;41(10):588–596
 45. **van der Voet LF, Vervoort AJ, Veersema S, BijdeVaate AJ, Br olmann HA, Huirne JA.** Minimally invasive therapy for gynecological symptoms related to a niche in the caesarean scar: a systematic review. *BJOG*. 2014; 121:145–156.
 46. **Candiani M, Ferrari SM, Marotta E, Tandoi I, Ottolina J, Salvatore S.** Mini-invasive transvaginal repair of isthmocele: a video case report. *Fertil Steril* 2019; 111:828–830.
 47. **Vitale SG, Ludwin A, Vilos GA, et al.** From hysteroscopy to laparoendoscopic surgery: what is the best surgical approach for

symptomatic isthmocele? A systematic review and meta-analysis. *Arch Gynecol Obstet.* 2020; 301:33–52.

48. **Harjee R, Khinda J, Bedaiwy MA.** Reproductive outcomes following surgical management for Isthmoceles: a systematic review. *J Minim Invasive Gynecol.* 2021; 28 (e2): 1291-1302