



## DISTAL TIBIA FRACTURES TREATED WITH POSTERIOR PLATING THROUGH POSTEROLATERAL APPROACH:

Dr. Anirudh Reddy PM<sup>1\*</sup>, Dr. Sasikumar<sup>2\*\*</sup>

### Abstract

**Purpose of The Study:** Fractures of the distal tibia are challenging to cure. There are several therapy techniques available. The purpose of this study is to evaluate the effectiveness and safety of posterior plating for distal tibial fractures in middle-aged and elderly patients as well as those with anteromedial type 1 and type 2 compound injuries using a posterolateral approach.

**Study Design and Material:** Thirteen distal tibial fracture patients who visited our hospital were chosen for posterior plating using the posterolateral technique. Of them, six had open fractures and seven had closed fractures (Gustillo Anderson type I). Other factors such complications, blood loss, fracture healing time, varus and valgus deformity, and wound healing time were taken into account while evaluating the treatment.

**Observation and Results:** During the 75-minute surgery, 40 ml of blood was lost on average. All thirteen patients had full surgical recoveries. An average of 20 weeks were spent on the union. There was no neurovascular injury, varus or valgus deformity, limb length difference, non-union, malunion, or non-union. Therefore, our research showed that posterior plating applied via the posterolateral route is a secure and reliable method of treating distal tibial fractures.

---

<sup>1\*</sup>PG resident, II year MS (Orthopaedics) Sree balaji medical college and hospital, Bharath University, Chennai.

<sup>2\*\*</sup> Assistant Professor, MS (Orthopaedics) Sree Balaji medical College and hospital, Bharath University

**\*Corresponding Author:-** Dr. Anirudh Reddy PM

<sup>\*</sup>PG resident, II year MS (Orthopaedics) Sree balaji medical college and hospital, Bharath University, Chennai.

**\*\* Author:-** Dr. Sasikumar

<sup>\*\*</sup>Assistant Professor, MS (Orthopaedics) Sree Balaji medical College and hospital, Bharath University

**DOI:** 10.48047/ecb/2023.12.si10.00181

## INTRODUCTION

A distal tibia fracture frequently coexists with varying degrees of vascular and soft tissue damage. Treatment for anterior soft tissue injuries in fractures might be challenging. Between anterior soft tissue damage and its precise fracture repair, there are difficulties. For medial and lateral plates to be securely secured, anterior soft tissue is required. Distal tibia fractures with anterior skin loss can also be treated with external fixators. However, all of these techniques have it's challenging to treat 6-8,10 due to the high rate of pin tract infection, malunion, and nonunion. The effectiveness of modified intramedullary nailing in treating distal tibia fractures is debatable. The best course of action for treating distal tibial fractures accompanied by anterior soft tissue injuries might be challenging.

For the purpose of fixing distal tibial fractures, tibial locking compression plates were employed. Our goals were to avoid damaging the wounded anterior soft tissues and to provide correct anatomical fixation.

## INCLUSION AND EXCLUSION CRITERIA:

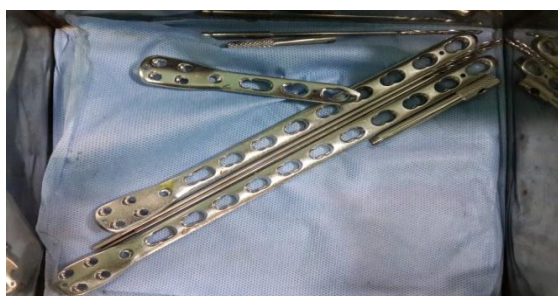1. Gustilo Anderson categorization of types I and II distal tibial fracture.
2. No involvement of the posterior soft tissues.
3. There is no intraarticular involvement.
4. With or without fractures of the fibula.
5. Patients with surgical contraindications, pathologic fractures, autoimmune illnesses, blood disorders, severe multiple trauma, and other conditions were disqualified.

## INVESTIGATIONS

In all patients, lateral and anteroposterior (AP) radiographs of the leg, including the ankle joint, were collected. MRI and CT scans are also performed as necessary.

## Materials and Methods:

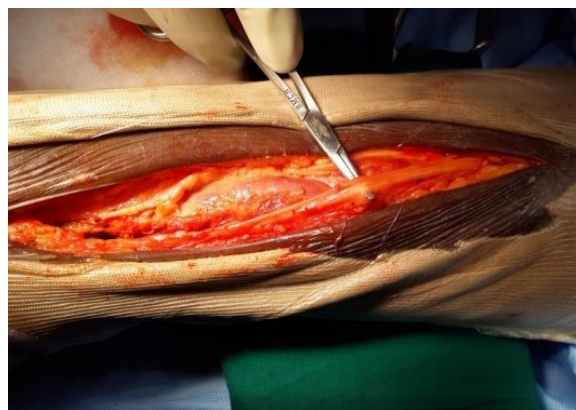There were 13 instances of lower tibia fractures that were discovered. Compression plates with locking mechanisms are employed.



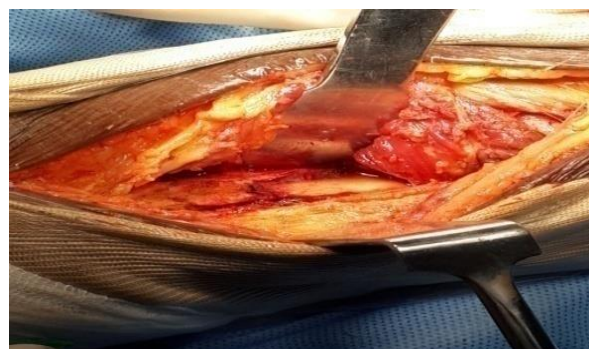**Figure 1:** locking compression plates

Patient in prone posture with epidural or general anaesthesia.

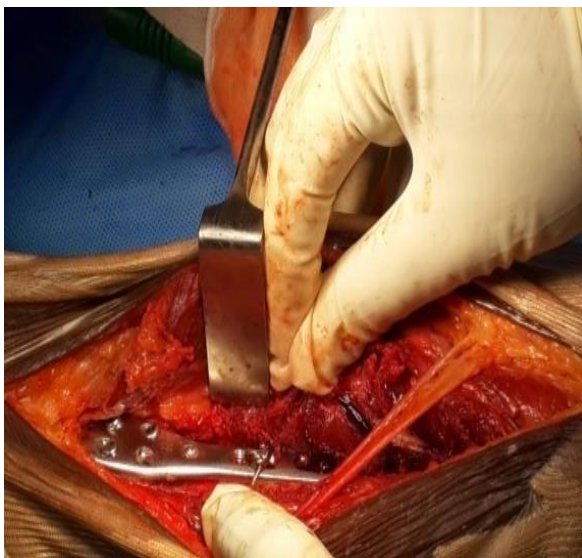A skin incision is created along the fibula's posteromedial border, and it might go as far proximally as necessary. It should never extend farther medial than the Achilles tendon's lateral border. The sural nerve runs from the middle of the calf proximally to immediately posterior to the fibula distally, and it is crucial to understand its route. Recognize the sural nerve under the superficial fascial layer, and often incorporate it in the lateral flap. It could be essential to operate on either side of this nerve if the dissection is prolonged further proximally. A superficial dissection should be performed all the way to the peroneal fascia's attachment point on the posterolateral fibula border. Retract the peroneals medially while cutting the fascia. The tibia is accessible via a distinct plane that has grown on the posteromedial boundary of the peroneal muscles. These have now lateral retractions. By developing the space between the flexor hallucis longus (FHL) medially and the peroneal tendons and muscles laterally, the posterior side of the tibia can be exposed. reached the fracture site, reduced it, and lengthened the tibia. Locking compression plates were positioned and fastened posteriorly.



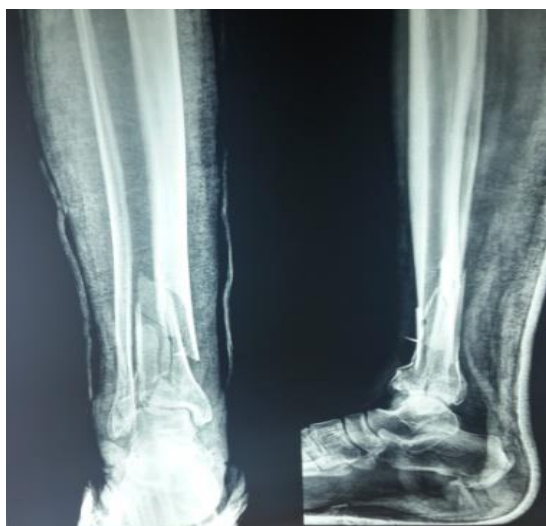**Figure 2:** shows the line of incision and the sural nerve



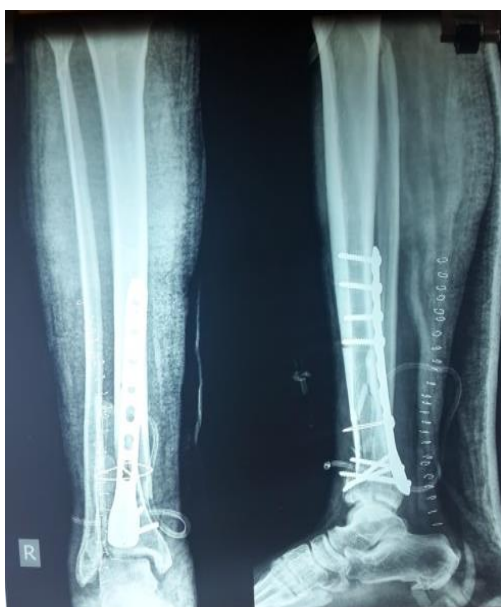**Figure 3:** shows the fracture site



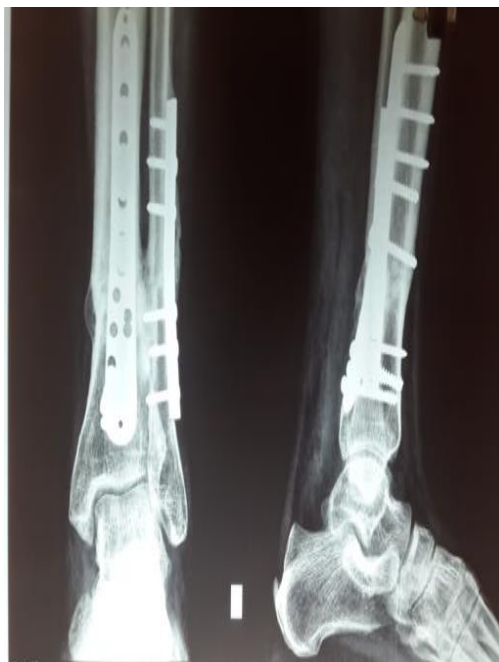**Figure 4:** shows the sural nerve and the lcp used



**Figure 5:** anteroposterior and lateral view radiograph shows distal tibia fracture



**Figure 6:** post operative AP and lateral radiograph shows hardware insitu.



**Figure 7:** post operative follow up radiograph which shows good callus formation.

#### POSTOPERATIVE MANAGEMENT:

Following surgery, antibiotic therapy was administered. Skin sensitivity and peripheral circulation were evaluated. Exercises for the knee and ankle joints got underway right away. The weight-bearing walking time was calculated based on the fracture type, fixation strength, age, and callus development. Partial weight bearing after 6 to 8 weeks and Full weight bearing was permitted after 10 to 12 weeks.

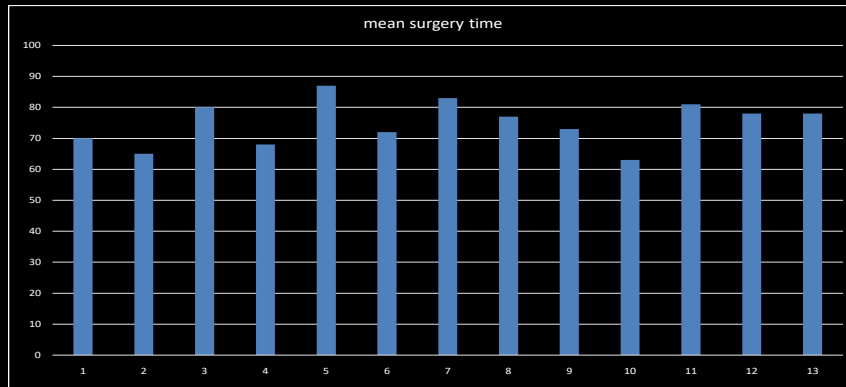
The following complications rates should be observed:

Malunion of fracture assessment: Johnson angle of the ankle joint was assessed on the most recent AP and lateral radiographs of the lower leg in its entirety. If the AP angle, varus, or both were more than  $5^\circ$ , was proof of malunion. Limb-shortening deformity: a limb shortening of more than 1 cm. Infection of the anterior skin wound and surgical incisions, skin necrosis, unsuccessful internal fixation, and neurovascular injury are all examples of fractures that do not heal.

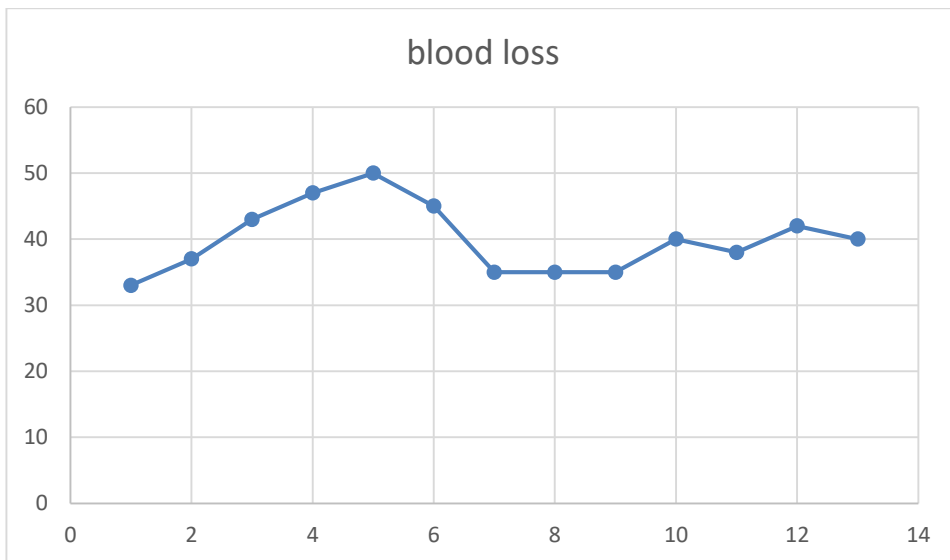
#### Observation and results

An average of 90 ml of blood was lost throughout the 75-minute procedure. All thirteen patients had successful post-operative recovery. The union took place after an average of 20 weeks. No cases of non-union, malunion, limb length disparity, or neurovascular damage were reported. As a result, our research shown that posterior plating is a successful and efficient strategy for treating distal tibial fractures.

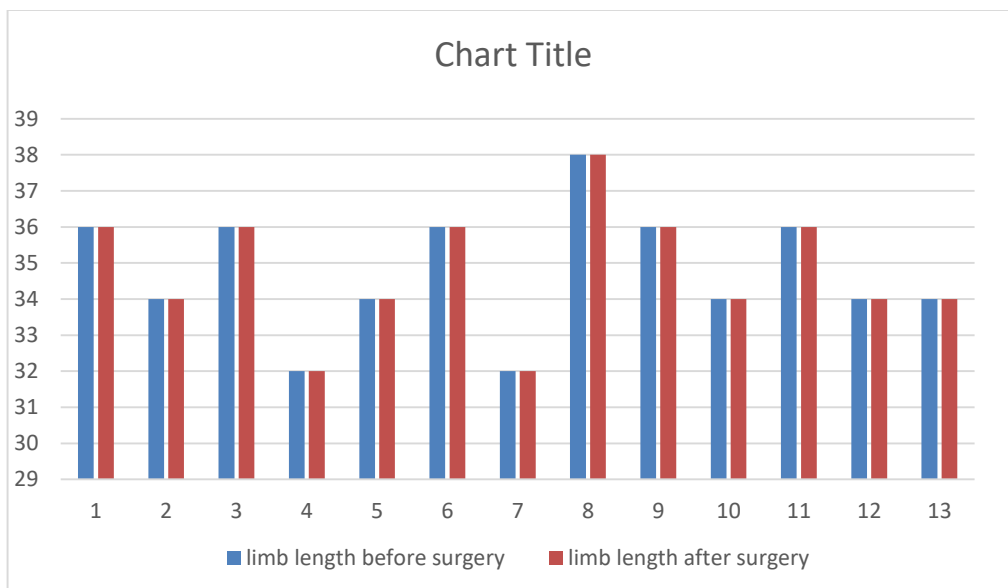
# RESULTS



Mean surgical time is 75 min +/- 10 min.

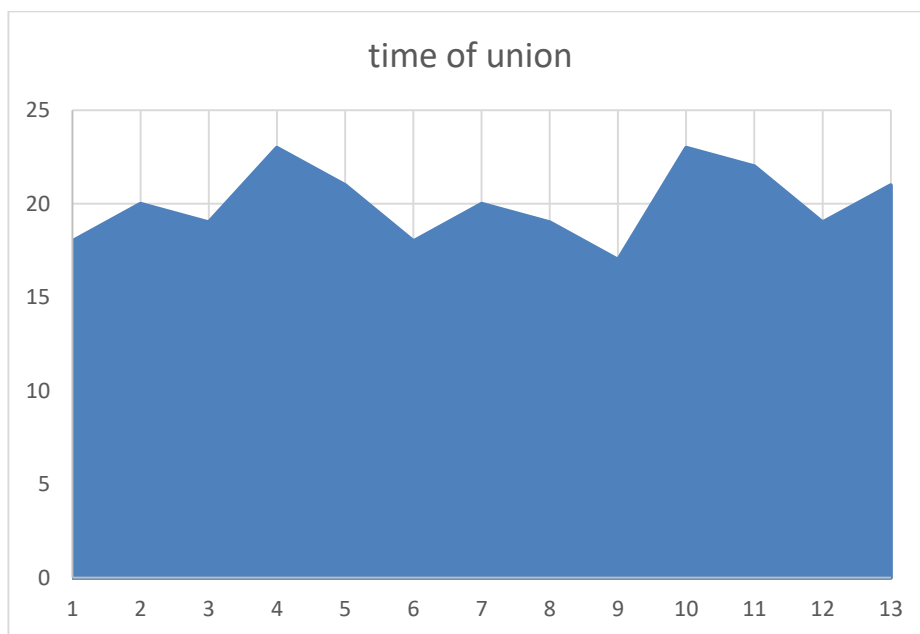


Mean blood loss 40ml +/- 10ml

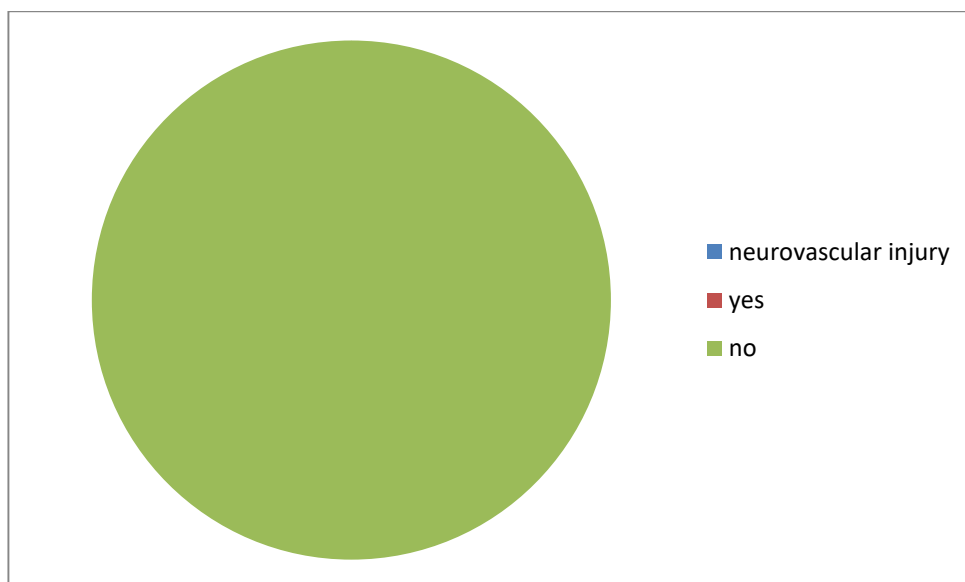


Limb length discrepancy: no limb length discrepancy





Mean Time of fracture union 20 weeks +/- 5 weeks



Neurovascular injury: no neurovascular injury

**Discussion:**

Our decision on therapy is complicated by the existence of soft tissue damage. The preferred therapy for injuries involving severe soft tissue is the use of an external fixator since it may stabilise the fracture without compromising the patient's health. However, this approach is not without drawbacks, such as malunion, pintract infections, and inconvenience. External fixation can thus be employed as an emergency technique.

These fractures can also be fixed with the use of nailing and plating.

These fractures' anatomy precluded earlier nailing from being employed on them.

However, the newest nails have fixed these issues. However, they are most affected by issues like nonunion, infection, malunion, and the like in open

and community fractures as a result of severe traumas.

Currently, medial and lateral plate fixation are the preferred therapeutic modalities. However, there is a larger risk of skin infection when an anterior skin incision is made in situations where soft tissue damage have occurred.

Thus, it has been discovered that the therapeutic choices are influenced by the consistency of the anterior soft tissue. Fracture fixation using an anterior medial incision was observed to need longer healing times, according to Krackhardt et al. The skin gets damaged by this method even if the blood flow is not compromised.

Sometimes split or flap skin grafting techniques are needed to treat these skin injuries.

Our research thus focused on coming up with a better answer to this issue. As a result, we used locking compression plates in a single stage posterolateral technique to treat the fracture without engaging the anterior soft tissues.

Our primary goal was to prevent anterior skin injury. The main idea behind the posterolateral technique is to treat the fracture without touching the anterior soft tissue that has been injured. Clinical evidence supporting the posterolateral method to distal tibia fracture repair, which has an average recovery period of 20 weeks, was previously provided by Sheerin et al. They also discovered that a single incision may be used to repair both the fibula and the tibia. The Achilles tendon typically obscures our view of the distal Tibia, therefore this method does have some exposure challenges.

### Conclusion:

For the treatment of distal Tibial fractures with accompanying anterior soft tissue damage, a locking compression plate using a posterolateral approach can be employed, and it did not lead to major complications such sural nerve injury, malunion, or non-union. The distal tibia's blood supply is likewise safeguarded using this technique.

### References

1. Marsh JL, Saltzman CL. Ankle fractures. In: Bucholz RW, Heckman JD, Court-Brown C, eds. *Rockwood & Green's Fractures in Adults*. 6th ed. Philadelphia, PA: Lippincott Williams & Wilkins; 2006:2147–2247.
2. Zelle BA, Bhandari M, Espiritu M, et al. Treatment of distal tibia fractures without articular involvement: a systematic review of 1125 fractures. *J Orthop Trauma*. 2006; 20(1):76–79. doi: 10.1097/01.bot.0000202997.45274.a1
3. Babis GC, Kontovazenitis P, Evangelopoulos DS, et al. Distal tibial fractures treated with hybrid external fixation. *Injury*. 2010; 41(3):253–258. doi: 10.1016/j.injury.2009.09.014
4. Joveniaux P, Ohl X, Harisboure A, et al. Distal tibia fractures: management and complications of 101 cases [published online ahead of print June 25, 2009]. *Int Orthop*. 2010; 34(4):583–588. doi: 10.1007/s00264-009-0832-z
5. Sheerin DV, Turen CH, Nascone JW. Reconstruction of distal tibia fractures using a posterolateral approach and a blade plate. *J Orthop Trauma*. 2006; 20(4):247–252. doi: 10.1097/00005131-200604000-00003
6. Krackhardt T, Dilger J, Flesch I, Höntzsch D, Eingartner C, Weise K. Fractures of the distal tibia treated with closed reduction and minimally invasive plating [published online ahead of print February 10, 2005]. *Arch Orthop Trauma Surg*. 2005; 125(2):87–94. doi: 10.1007/s00402-004-0778-y
7. Ronga M, Longo UG, Maffulli N. Minimally invasive locked plating of distal tibia fractures is safe and effective [published online ahead of print July 30, 2009]. *Clin Orthop Relat Res*. 2010; 468(4):975–982. doi: 10.1007/s11999-009-0991-7
8. Gao H, Zhang CQ, Luo CF, Zhou ZB, Zeng BF. Fractures of the distal tibia treated with polyaxial locking plating [published online ahead of print August 22, 2008]. *Clin Orthop Relat Res*. 2009; 467(3):831–837. doi: 10.1007/s11999-008-0459-1
9. Ristiniemi J, Flinkkilä T, Hyvönen P, et al. Two-ring hybrid external fixation of distal tibial fractures: a review of 47 cases. *J Trauma*. 2007; 62(1):174–183. doi: 10.1097/01.ta.0000215424.00039.3b
10. Collinge C, Protzman R. Outcomes of minimally invasive plate osteosynthesis for metaphyseal distal tibia fractures. *J Orthop Trauma*. 2010; 24(1):24–29. doi: 10.1097/BOT.0b013e3181ac3426
11. Keating JF, O'Brien PJ, Blachut PA, Meek RN, Broekhuysen HM. Locking intramedullary nailing with and without reaming for open fractures of the tibial shaft. A prospective, randomized study. *J Bone Joint Surg Am*. 1997; 79(3):334–341.
12. Mohammed A, Saravanan R, Zammit J, King R. Intramedullary tibial nailing in distal third tibial fractures: distal locking screws and fracture non-union [published online ahead of print April 5, 2007]. *Int Orthop*. 2008; 32(4):547–549. doi: 10.1007/s00264-007-0356-3
13. Gustilo RB, Anderson JT. Prevention of infection in the treatment of one thousand and twenty-five open fractures of long bones: retrospective and prospective analyses. *J Bone Joint Surg Am*. 1976; 58(4):453–458.
14. Oestern HJ, Tschernke H. Pathophysiology and classification of soft tissue injuries associated with fractures. In: Tschernke H, Gotzen L, eds. *Fractures With Soft Tissue Injuries*. Berlin, Germany: Springer-Verlag; 1984:1–9.
15. Marsh JL, Slongo TF, Agel J, et al. Fracture and dislocation classification compendium—2007: Orthopaedic Trauma Association classification, database and outcomes committee. *J Orthop Trauma*. 2007; 21(10 Suppl):S1–S133. doi: 10.1097/00005131-200711101-00001

16. Faschingbauer M, Kienast B, Schulz AP, Vukelic R, Meiners J. Treatment of distal lower leg fractures: results with fixed-angle plate osteosynthesis. *Eur J Trauma Emerg Surg.* 2009; 35(6):513–519. doi: 10.1007/s00068-009-9176-z
17. Lee YS, Chen SW, Chen SH, Chen WC, Lau MJ, Hsu TL. Stabilisation of the fractured fibula plays an important role in the treatment of pilon fractures: a retrospective comparison of fibular fixation methods [published online ahead of print October 18, 2008]. *Int Orthop.* 2009; 33(3):695–699. doi: 10.1007/s00264-008-0654-4
18. Varsalona R, Liu GT. Distal tibial metaphyseal fractures: the role of fibular fixation. *Strat Traum Limb Recon.* 2006; 1(1):42–50. doi: 10.1007/s11751-006-0005-1
19. Blick SS, Brumback RJ, Lakatos R, Poka A, Burgess AR. Early prophylactic bone grafting of high-energy tibial fractures. *Clin Orthop Relat Res.* 1989; (240):21–41.
20. Kitaoka HB, Alexander IJ, Adelaar RS, Nunley JA, Myerson MS, Sanders M. Clinical rating systems for the ankle-hindfoot, mid-foot, hallux, and lesser toes. *Foot Ankle Int.* 1994; 15(7):349–353.
21. Krettek C, Schandelmaier P, Lobenhoffer P, Tscherne H. Complex trauma of the knee joint. Diagnosis–management–therapeutic principles [in German]. *Unfallchirurg.* 1996; 99(9):616–627. doi: 10.1007/s001130050034
22. Möller T. Untere Extremitäten. In: Möller T, ed. *Röntgennormalbefunde.* Stuttgart, Germany: Thieme; 2003:131–133.
23. Haidukewych GJ. Temporary external fixation for the management of complex intra-and periarticular fractures of the lower extremity. *J Orthop Trauma.* 2002; 16(9):678–685. doi: 10.1097/00005131-200210000-00012
24. Vallier HA, Le TT, Bedi A. Radiographic and clinical comparisons of distal tibia shaft fractures (4 to 11 cm proximal to the plafond): plating versus intramedullary nailing. *J Orthop Trauma.* 2008; 22(5):307–311. doi: 10.1097/BOT.0b013e31816ed974
25. Court-Brown CM, McQueen MM, Quaba AA, Christie J. Locked intramedullary nailing of open tibial fractures. *J Bone Joint Surg Br.* 1991; 73(6):959–964.
26. Gupta RK, Rohilla RK, Sangwan K, Singh V, Walia S. Locking plate fixation in distal metaphyseal tibial fractures: series of 79 patients [published online ahead of print October 10, 2009]. *Int Orthop.* 2010; 34(8):1285–1290. doi: 10.1007/s00264-009-0880-4
27. Manninen MJ, Lindahl J, Kankare J, Hirvensalo E. Lateral approach for fixation of the fractures of the distal tibia. Outcome of 20 patients. Technical note [published online ahead of print February 28, 2007]. *Arch Orthop Trauma Surg.* 2007; 127(5):349–353. doi: 10.1007/s00402-006-0278-3
28. Lau TW, Leung F, Chan CF, Chow SP. Wound complication of minimally invasive plate osteosynthesis in distal tibia fractures [published online ahead of print June 16, 2007]. *Int Orthop.* 2008; 32(5):697–703. doi: 10.1007/s00264-007-0384-z
29. Collinge C, Kuper M, Larson K, Protzman R. Minimally invasive plating of high-energy metaphyseal distal tibia fractures. *J Orthop Trauma.* 2007; 21(6):355–361. doi: 10.1097/BOT.0b013e3180ca83c7
30. Im GI, Tae SK. Distal metaphyseal fractures of tibia: a prospective randomized trial of closed reduction and intramedullary nail versus open reduction and plate and screws fixation. *J Trauma.* 2005; 59(5):1219–1223. doi: 10.1097/01.ta.0000188936.79798.4e
31. Ozgur A, Aksoy C, Tokgözoğlu AM. Posteromedial approach and posterior plating of the tibia. *J Trauma.* 2002; 53(4):722–724. doi: 10.1097/00005373-200210000-00017