



## Evaluation of wound healing and anti-inflammatory potential of *Daucus Carota* ethanolic Extract in laboratory animals.

Padmaja Kore<sup>1\*</sup>, Mansi Sewatkar<sup>1</sup>, Vaishnavi Inde<sup>1</sup>, Abhishek Nemmaniwar<sup>1</sup>, Anuradha More<sup>2</sup>, Minal Harde<sup>3</sup>, Sakshi Khandagale<sup>1</sup>, Tanvi Mande<sup>1</sup>, Shivani Harne<sup>1</sup>, Neha Dhumal<sup>1</sup>, Pooja Chavan<sup>1</sup>

<sup>\*1</sup> Department of Pharmacology, Progressive Education Society's Modern College of Pharmacy, Yamunanagar, Nigdi, Pune-44.

<sup>2</sup> Department of Pharmaceutics, Progressive Education Society's Modern College of Pharmacy, Yamunanagar, Nigdi, Pune-44.

<sup>3</sup> Department of Pharmaceutical Analysis, Progressive Education Society's Modern College of Pharmacy, Yamunanagar, Nigdi, Pune-44.

**\*Corresponding Author:**

Dr. Padmaja Santosh Kore

Email address: [padmaja.kalshetti@gmail.com](mailto:padmaja.kalshetti@gmail.com)

Progressive Education Society's Modern College of Pharmacy,  
Yamunanagar, Nigdi, Pune-44.

---

### Abstract

**Background:** Wild carrot, also known as Queen Anne's Lace, was introduced to North America from Europe as a medicinal herb., *Daucus Carota* is sanctified with a wide variety of qualities which are mainly indicated in Ayurveda to be used for Mehahara (treats urinary tract disorders), Deepana (enhances stomach fire), Pachana (helps in digestion), Rochana (stimulates appetite) The ethanol extract of the leaves of *D. Carota* (DCEE) was investigated for its healing efficiency in a rat excision wound model.

**Methods:** We divided the three groups of eight rats into excision wounds. The rate of wound contraction in skin wound sites in rats treated with 10% (w/w) betadine ointment or the reference standard medication, 5%, 10%, or 15% (w/w) DCEE ointment, was used to measure healing. Estimates were made of how DCEE affected the amounts of hydroxyproline and hexosamine during the healing process. Also evaluated was DCEE's antibacterial efficacy towards microbes. To comprehend the mechanism of wound healing, the in vivo anti-inflammatory activity of DCEE was examined.

**Results:** Significant antibacterial action was shown by DCEE against microorganisms. The wound contraction in the excision wound model demonstrated the powerful wound healing capacity of the ointment formulation made with 5%, 10%, and 15% (w/w) DCEE. Hexosamine and hydroxyproline concentrations were also connected to the pattern of healing that was seen. These results were corroborated by the histological features of sections of healed wounds, which showed that the DCEE ointment-treated groups had better tissue regeneration, more

fibroblasts, and angiogenesis. The findings also showed that DCEE has strong anti-inflammatory properties since it increased the production of cytokines that prevent the synthesis of pro-inflammatory cytokines.

**Conclusions:** The findings imply that DCEE's antibacterial and anti-inflammatory properties work together to hasten wound healing.

**Key words:** Excision wounds, anti-inflammatory properties, TNF- $\alpha$

---

## Introduction

Skin is the most superficial part and is a natural protective barrier of the body, that plays an important role in defense against foreign bodies and pathogens <sup>[1]</sup>. In maintaining the physiological homeostasis of the human body the integrity of the healthy skin plays a crucial role <sup>[2]</sup>. One of the most common diseases in developing countries is wound infection due to poor hygiene <sup>[3]</sup>. Dynamic reciprocity between cytokine cells and extracellular matrix is involved in the repairing of the burn wound. The repairing process takes place in three steps, the inflammation phase, the proliferation phase, and the tissue remodeling phase <sup>[4]</sup>. It is necessary to apply a proper wound dressing as a temporary substitute for damaged skin to re-establish the skin's barrier function. The wound healing process, that is, restoration of structure and function of injured tissue is studied with the help of a herbal drug named *Daucus carota* as this plant plays an indispensable role to treat various ailments.

The present study provides a scientific evaluation of wound healing potential of the crude extract of *Daucus carota* leaves <sup>[5]</sup>. One of the most common causes of skin injuries is burns wounds which are defined as tissue damage by heat or corrosive chemicals <sup>[6]</sup>. Various phytochemicals are used for wound healing in traditional medicines which also facilitate wound healing process via anti-inflammatory, antimicrobial and antioxidant activity. The treatment of skin needs the use of several drugs administered separately or combined after burn damage and it is a painful and complex process <sup>[7]</sup>. Those wounds with severe burns need to be treated as soon as possible; because the delay in treatment may lead to infection and postpone the healing process <sup>[8]</sup>. *Daucus carota* belongs to the Umbelliferae (Apiaceae) plant family and is one of the valuable vegetables which is being greatly cultivated in Iran. It is a native plant of Europe, North Africa, and most importantly southwestern Asia. Its common name is carrot which is a well-known vegetable consumed in daily meals. The plant is also known as Queen Anne's lace and the leaves are reported for antioxidants and free radical scavenging activities. There are no current studies on the impact of such herbs on healing. *Daucus Carota's* high anti-inflammatory and ethnopharmacological capabilities make it an excellent source of novel therapeutic targets for wound healing. Consequently, the present study evaluated the consequences of *Daucus Carota's* ethnobotanical use on various characteristics and phases of healing the wounds.

## Materials and Methods:

### Plant collection

The fresh plant of *Daucus Carota* was collected from Saswad region of Pune district. The plant material was taxonomically identified and authenticated by the Botanical Survey of India (BSI) and voucher number was SHDC1. The ethanol extract of the leaves of *Daucus Carota* was investigated for its healing efficiency in a rat excision wound model.

### Plant Extraction

To obtain powdered samples, the aerial portions of *Daucus Carota* were air-dried, ground into a coarse powder using a mechanical grinder, and then passed through a 40-mesh screen. To create the ethanol extracts, 2 kg of powdered materials were extracted three times at room temperature using 5 L of 95% ethanol for 48 hours on an orbital shaker. The *Daucus Carota* ethanolic extract (DCEE) was lyophilized after being evaporated to dryness to remove all traces of alcohol, producing about 127 g of dry residue (w/w yield: 6.36%). Distilled water was used to suspend DCEE. Following an HPLC protocol, analysis of the samples for the presence of chlorogenic acid content was conducted.

### Phytochemical analysis <sup>[9]</sup>

The phytochemical analysis was performed as per the reported procedure.

### Chlorogenic acid content analysis by HPLC <sup>[10]</sup>

A Waters HPLC 600 with a UV-detector and a flow rate of 1 mL/min was used to quantify the analysis at a detection wavelength of 320 nm. Utilizing a cosmosil C18 column (5 m, 2504.6 mm), the separation was achieved. The column was kept at a constant 30 C. The separation was done using a gradient elution technique with solvents A (methanol) and B (acetic acid in water at a concentration of 0.5% (v/v). 0min 10% A in B, 28.6min 60% A in B, and 30min 10% A in B comprised the elution profile. Before use, the mobile phase was passed through a 0.45-μm membrane filter whilst under vacuum. The injection volume was 10 mL, and the flow rate was 1 ml/min. At 320 nm, absorption was detected. UV spectrum and standard chlorogenic acid's retention time were used to validate the presence of chlorogenic acid (Standard values of purity). Chlorogenic acid, batch number Yucca/CHA/2021/04/04, purity 98.0%, Yucca Enterprises, Mumbai, Maharashtra, India. A standard calibration curve was produced using a concentration range of 15 to 50 g/ml. Compound retention time was discovered to be 15.7. The peak regions were utilised to estimate the concentration of chlorogenic acid. The extract's chlorogenic acid content was quantified in μg/g. Three copies of each sample reading were taken.

### Antimicrobial activity <sup>[11]</sup>

The antimicrobial activity was evaluated by using the agar diffusion method. The microorganisms used for the study of antimicrobial activity were *Escherichia coli* (ATCC 8739), *Staphylococcus aureus* (ATCC 6538P), *Pseudomonas aeruginosa* (ATCC 9027), *Bacillus subtilis* (ATCC 6633) and *Candida Albicans* (ATCC 10321). These organisms were procured and identified by National Chemical Laboratory (NCL). Bacteria were cultured at 37°C overnight in Mueller Hinton Broth (Oxoid) while fungi were cultured in Potato Dextrose Broth (Oxoid) at 28°C for 72 hours. The final inoculum contained 100 μl and inocula consisting of suspensions that contained 1×10<sup>4</sup> spore/ml fungi and 1×10<sup>8</sup> CFU/ml bacteria were spread evenly on Potato Dextrose Agar and Mueller Hinton Agar respectively. A disc of 6 mm in diameter was impregnated using 10μl of 100 mg/ml (1mg/disc) extract of *Daucus carota*. Gentamicin (10μg/disc) was used as a positive control for bacteria. Test plates were incubated

at 28°C for fungi (72 hours) and at 37°C (24 hours), depending on the time needed for visible growth. We also looked at the Minimum Inhibitory Concentration (MIC) values for bacteria that showed sensitivity to a *Daucus Carota* extract in a disc diffusion experiment. Sterilized filter paper discs with a 6 mm diameter and 2.5–1000 g of all components per disc were placed on the medium's surface. The term "Minimum Inhibitory Concentration" (MIC) refers to the lowest amount of extract that might stop observable growth on agar. <sup>[12]</sup>

### **Experimental Animals**

Wistar rats (only male) weighing 200-250 gm and 6 to 8 weeks old were obtained from the National Institute of Biosciences and maintained at a controlled temperature of 25± 1°C in the animal house. After procurement, they were acclimatized to the laboratory conditions for 7-days. The light-dark cycle was kept as 12:12. The rats were allowed free access to food and water. They were weighed periodically before and after the experimental procedures. The protocol was approved by Institutional Animal Ethical Committee (IAEC) of Progressive Education Society's Modern College of Pharmacy, Yamunanagar, Nigdi, Pune-44.

### **Excision wound model<sup>[12]</sup>**

The rats were randomized in to 5-groups containing 6-animals/group. The animals were anesthetized using the open mask procedure by the anaesthetic ether, and the rat's dorsal sides were depilated. One excision wound was created by removing a 400 mm<sup>2</sup> portion of full-thickness skin from a predefined region. The wound was left undressed with open environment. Group-1 rats were treated with simple ointment composed of hydrophilic ointment base composed of White petroleum 25% (w/w), Stearyl alcohol 25% (w/w), Propylene glycol 10% (w/w), Sodium lauryl sulphate 1% (w/w), Propyl paraben 0.015% (w/w), Methyl paraben 0.025% (w/w), Purified water q.s. Group-II was treated with standard ointment (Povidone-iodine ointment (10%, w/w, Win-Medicare PVT LTD New Delhi, India), Group-III, IV and V were treated with 5%, 10% and 15% ointment. Wound healing was monitored by taking photographs on days 1,4,7,10,13 and 15 after wounding. Wounds were considered closed (completely healed) if moist granulation tissue was no longer apparent and the wound was covered with new epithelium.

### **Estimation of pro-inflammatory and anti-inflammatory cytokine induction<sup>[10]</sup>**

Blood samples were collected from all animals of each group on days 1 and 9 after wounding. The levels of pro-inflammatory (TNF $\alpha$  and IL-6) and anti-inflammatory cytokines (IL-10) were estimated by performing enzyme linked immunosorbent assays (ELISAs) using commercial kits. The entire estimation was performed at Sciore Research Pvt. Ltd., Bhosari, Pune. Assays were performed according to the manufacturer's instructions. The cytokine concentrations were determined in pg/ml by plotting the graph for the standard. All experiments were performed in triplicate to ensure the accuracy of the observations.

### **Estimation of hydroxyproline and hexosamine<sup>[10]</sup>**

A sample of skin from the healed wound area was taken on days 3, 9, and 15 following wounding and its levels of hydroxyproline, the main building block of collagen, were measured. The tissues were then hydrolysed in 6 N HCl at 130°C for 4 hours in sealed tubes

after being dried to an equivalent weight in a hot air oven at 60–70°C. With 0.1N KOH, the hydrolysate was brought to pH 7.0 before 20 minutes of chloramine-T oxidation. By adding 0.4 M perchloric acid, the reaction was stopped. Color was then produced using the Ehrlich reagent at 60°C and detected at 557 nm with a UV/Vis spectrophotometer (Shimadzu) [12]. The weighted granulation tissues were hydrolyzed in 6 N HCl for 8 hours at 98°C, neutralised to pH 7 with 4 N NaOH, and diluted with Milli-Q water to quantify the amounts of hexosamine. Minor alterations were made to the estimation of the hexosamine content of the granulation tissues [13]. A mixture of the diluted solution and acetylacetone solution was heated for 40 minutes at 96°C. The mixture was chilled before 96% ethanol and r-dimethylamino-benzaldehyde solution (Ehrlich's reagent) was added. A double-beam UV/Vis spectrophotometer was used to measure the absorbance at 530 nm after the solution had been completely mixed and left to stand at room temperature for one hour (Shimadzu). By comparing results with a standard curve, the concentration of hexosamine was calculated.

### Histopathological studies<sup>[10]</sup>

On the fifteenth day following wounding, a sample was taken from each set of rats for histopathological analysis. Until the tissues hardened, skin specimens were promptly fixed in 10% (v/v) neutral-buffered formalin, with the fixative solution being changed every two days. Each specimen was embedded in a paraffin block, and thin sections (3 m) were prepared and stained with Hematoxylin and Eosin (H&E) and Masson's trichrome (to identify collagen fibres). Slides were qualitatively inspected under a light microscope for collagen formation, fibroblast proliferation, angiogenesis, epithelization, and granulation tissue formation.

### Statistical analysis

Data are expressed as the mean  $\pm$  SEM for each group of animals and analyzed by one-way analysis of variance. Dunnett's post hoc test was used to determine the source of significant differences where appropriate. Data were analyzed using Graph pad prism (Version 8.4.3). P value  $< 0.05$  was considered statistically significant.

## Results

Phytochemical analysis showed the presence of following phytochemicals.

Phytochemicals	Ethanolic
Carbohydrates	+
Tannins	+
Saponins	+
Flavonoids	+
Steroids	+
Proteins	+
Alkaloids	-
Glycosides	+
Phenols	+

### Quantitative analysis:

The calibration equation of peak area against the concentration of chlorogenic acid was  $y = 7286.7x + 124.6$  ( $R^2 = 0.9998$ ). The chromatogram of the sample solution is shown in Figure 1. The chlorogenic acid content in DCEE was  $800 \pm 0.18 \mu\text{g/g}$  of the dry extract.

### Antimicrobial activity

DCEE inhibited the growth of all organisms tested, but the efficiency of its inhibition was organism-specific. The zone of inhibition of DCEE ranged from 8.25 to 15.67 mm. *Staphylococcus aureus* ( $15.67 \pm 0.08$  mm) was the most sensitive to DCEE, followed by *Pseudomonas aeruginosa* ( $13.55 \pm 0.12$  mm), *Candida Albicans* ( $10.87 \pm 0.06$  mm), *Escherichia coli* ( $9.44 \pm 0.10$  mm) and *Bacillus subtilis* ( $8.25 \pm 0.14$  mm). The MICs of DCEE ranged from 100 to 300  $\mu\text{g/disc}$ , with the lowest MIC observed for *Staphylococcus aureus*.

### Effect of DCEE on wound contraction

The contraction in the wound area in the group receiving 15% (w/w) DC ointment was evaluated every other day, and was found that the contraction in the wound area significantly increased from 31.94% on day-4 to 46.04, 75.25 and 86.14% on day 7, 10 and 13 respectively. and the wound was completely healed on day 15. Rats treated with Betadine ointment (10% w/w) showed similar results. On the other hand the group receiving simple ointment showed 12.88, 27.98, 45.3, 60.4 and 80.7% contraction on day 4, 7, 10, 13 and 15 respectively. Figure illustrates the macroscopic alterations at the wound site between days 1 and 15.

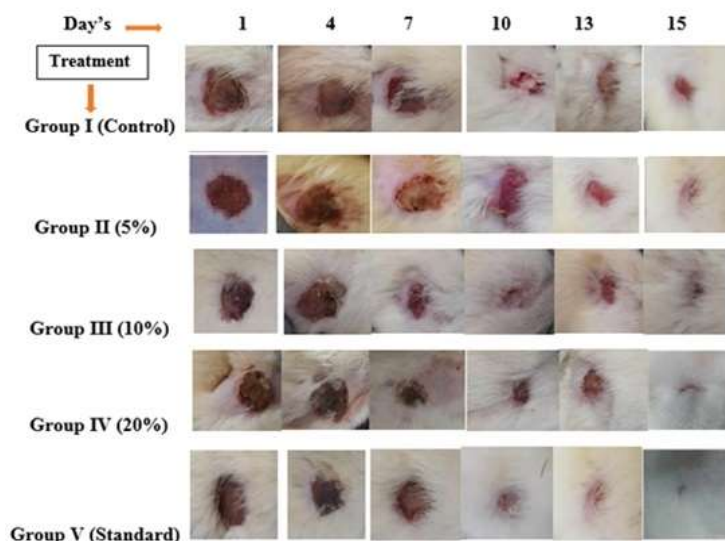


Figure-1: Wound contraction area in different treatment group

Table-1: Effect of treatments on wound contraction

	Simple Ointment	Betadine (10%)-Standard	DCEE-5% Ointment	DCEE-10% Ointment	DCEE-15% Ointment
Day-1	$396.67 \pm 6.67$	$406.17 \pm 4.25$	$396.67 \pm 6.67$	$400.83 \pm 5.83$	$404.33 \pm 3.64$
Day-4	$352.33 \pm 8.17$	$221.67 \pm 7.92^*$	$292.33 \pm 26.76^*$	$329.00 \pm 8.47^*$	$275.00 \pm 7.64^{**}$



<b>Day-7</b>	291.33 ± 4.05	162.83 ± 6.48**	230.00 ± 28.50*	291.67 ± 4.77**	218.33 ± 11.38**
<b>Day-10</b>	221.67 ± 7.92	108.50 ± 7.35**	164.17 ± 21.07**	218.33 ± 11.38***	99.83 ± 3.40***
<b>Day-13</b>	159.50 ± 9.14	80.83 ± 3.41***	129.33 ± 12.49***	108.50 ± 2.91***	55.50 ± 3.45***
<b>Day-15</b>	77.83 ± 4.28	26.00 ± 3.12***	101.67 ± 4.77***	62.50 ± 5.12***	18.67 ± 2.60***

Values are expressed by Mean ± SEM. Data was analyzed by two way ANOVA followed by multiple comparison. The \*P<0.05, \*\*P<0.01, \*\*\*P<0.001 as compared to control group.

#### **TNF- $\alpha$**

TNF- $\alpha$  level in the group receiving simple ointment (day 1: 241. ± 4.16 pg/ml; day 9: 209.83 ± 5.13 pg/ml) was significantly greater than that in the group receiving 10% (w/w) Betadine ointment (day 1: 191.17 ± 2.21; day 9: 135.83 ± 1.87 pg/ml). TNF- $\alpha$  level in the 15% (w/w) DC ointment-treated group were 222.0 ± 2.24 pg/ml on day 1 following wound induction, which was comparable to the levels in the simple ointment-treated group. On day 9 following wounding, the TNF- $\alpha$  level in the group receiving 15% (w/w) DC ointment (139.5 ± 4.39 pg/ml) was significantly (P<0.05) lower than that in the group receiving simple ointment. (Figure-2)

#### **IL-6**

At 24 hours after wounding, the IL-6 level in the 15% DC ointment treated rats (86.0 ± 1.0 pg/ml) was marginally lower than that in the simple ointment-treated group (106.67 ± 1.15 pg/ml), but on day 9 after wounding, the IL-6 level in the 15% DC ointment-treated group was significantly (\*\*\*P<0.001) reduced to 83.5 ± 1.57 pg/ml. On the other hand, basic ointment-treated rats showed a high IL-6 level on day 9 after wounding (89.67± 1.05 pg/ml). On the first day following wounding, the IL-6 level in the 10% (w/w) Betadine ointment-treated group (74.33 ± 1.36 pg/ml) was significantly (\*\*P<0.01) lower than that in the simple ointment-treated group. (Figure-2).

#### **IL-10:**

The IL-10 level following wounding was significantly (\*\*P<0.01) lower in the 10% (w/w) Betadine ointment-treated group (day 1: 807.66 ± 4.07 pg/ml; day 9: 1106.0 ± 27.57 pg/ml) than in the simple ointment-treated group (day 1: 416.83 ± 7.26 pg/ml; day 9: 542.5 ± 2.43 pg/ml (Table-1). On days 1 and 9 following wounding, the IL-10 level in the 15% (w/w) DC ointment treated group was noticeably raised, reaching 752.66 ± 15.29 and 1012.66 ± 6.43 pg/ml, respectively (Figure-2).

#### **Effect on hydroxyproline content:**

Hydroxyproline content in Simple ointment treatment group on day-3 was found to be 20.83 ± 0.75 mg/g of tissue. There was significant (\*P<0.05, \*p<0.05) increase in the hydroxyproline on day-9 and day-15 respectively and the content was found to be 31.83 ± 0.65 and 40.83 ± 1.25 mg/g of tissue. On day-3, treatment with betadine (10%) showed hydroxyproline content as 40.2 ± 0.7 mg/g of tissue. There was significant (\*P<0.05, \*\*p<0.001) increase in hydroxyproline content on day-9 and day-15 respectively and the content was found to be 60 ± 0.65 and 80.2 ± 0.8 mg/g of tissue. Treatment with 5% DCEE ointment on day-3 showed hydroxyproline content 37.67 ± 0.92 mg/g of tissue. There was significant (\*P<0.05, \*\*\*P<0.001) increase in hydroxyproline content on day-9 and day-15 and the increase was

found to be  $52.67 \pm 0.71$  and  $68.50 \pm 0.76$  mg/g of tissue. On day-3, treatment with 10% DCEE showed hydroxyproline content as  $41.17 \pm 0.98$  mg/g of tissue. There was significant (\* $P < 0.05$ , \*\* $P < 0.001$ ) increase in hydroxyproline content on day 9 and day 15 and the values were found to be  $57.83 \pm 0.83$  and  $87.67 \pm 0.92$  respectively. Treatment with 15% ointment on day-3 was found to be  $44.83 \pm 1.99$  mg/g of tissue. There was significant (\* $P < 0.05$ , \*\* $P < 0.001$ ) increase in the hydroxyproline content on day 9 and day 15 and the values were found to be  $63.33 \pm 3.80$  and  $107.83 \pm 3.94$  respectively. (Figure-2)

**Effect on Hexosamine content:**

Hexosamine content in simple ointment group on day-3 was found to be 0.19 mg/100 gms of tissue. There was significant (\* $p < 0.05$ , \*\* $P < 0.001$ ) increase in the hexosamine content on day-9 and day 15 and the values were found to be  $0.46 \pm 0.01$  and  $0.68 \pm 0.01$  respectively. In Betadine (10%) treated group, the hexosamine content on day 3 was found to be  $0.41 \pm 0.01$  mg/100 gms of tissue. The content was found to be significantly ( $P < 0.05$ ,  $P < 0.01$ ) increased on day 9 and day 15 to  $0.79 \pm 0.01$  and  $0.89$  mg/100 gms of tissue respectively. In case of treatment with 5% ointment, there was significant (\* $P < 0.05$ , \*\* $P < 0.001$ ) increase in the hexosamine content on day 9 and day 15 respectively and the content was found to be  $0.64 \pm 0.02$ , and  $0.79 \pm 0.01$  mg/100 gms of tissue respectively. Ointment in 10% showed the Hexosamine content on day-3 as  $0.51 \pm 0.01$  mg/100 gms of tissue. There was significant (\* $P < 0.05$ , \*\* $P < 0.01$ ) increase in hexosamine content on day 9 and day 15 and the content was found to be  $0.80 \pm 0.01$  and  $0.89 \pm 0.01$  mg/100 gms of tissue respectively. In 15% ointment group, the hexosamine content on day 3 was found to be  $0.46 \pm 0.02$  mg/100 gms of tissue. On day 9 and day 15, the hexosamine content was found to be significantly (\* $P < 0.05$ , \*\* $P < 0.001$ ) increased and the values were found to be  $0.84 \pm 0.03$  and  $0.93 \pm 0.01$  mg/100 gms of tissue. (Figure-2).



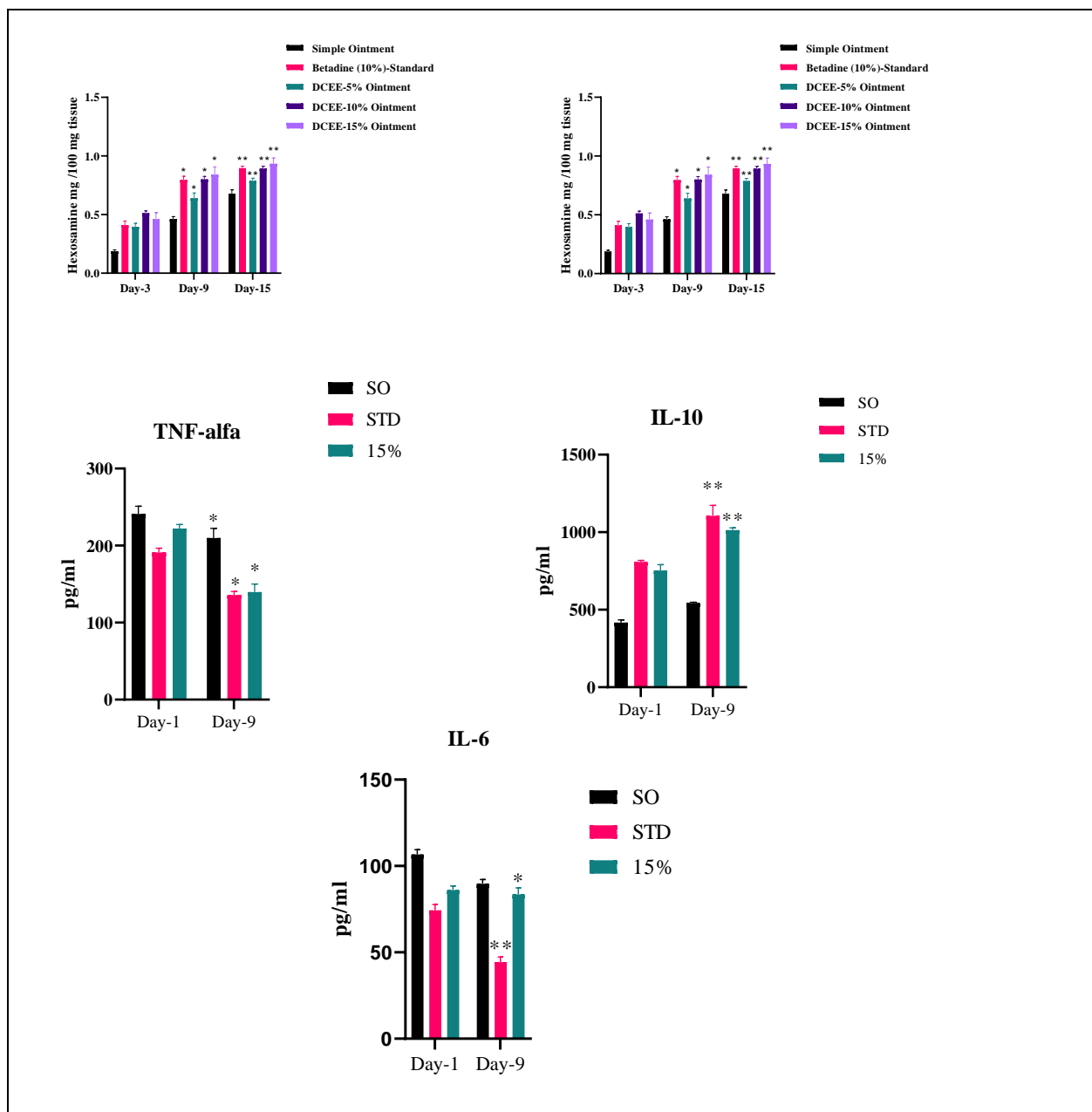
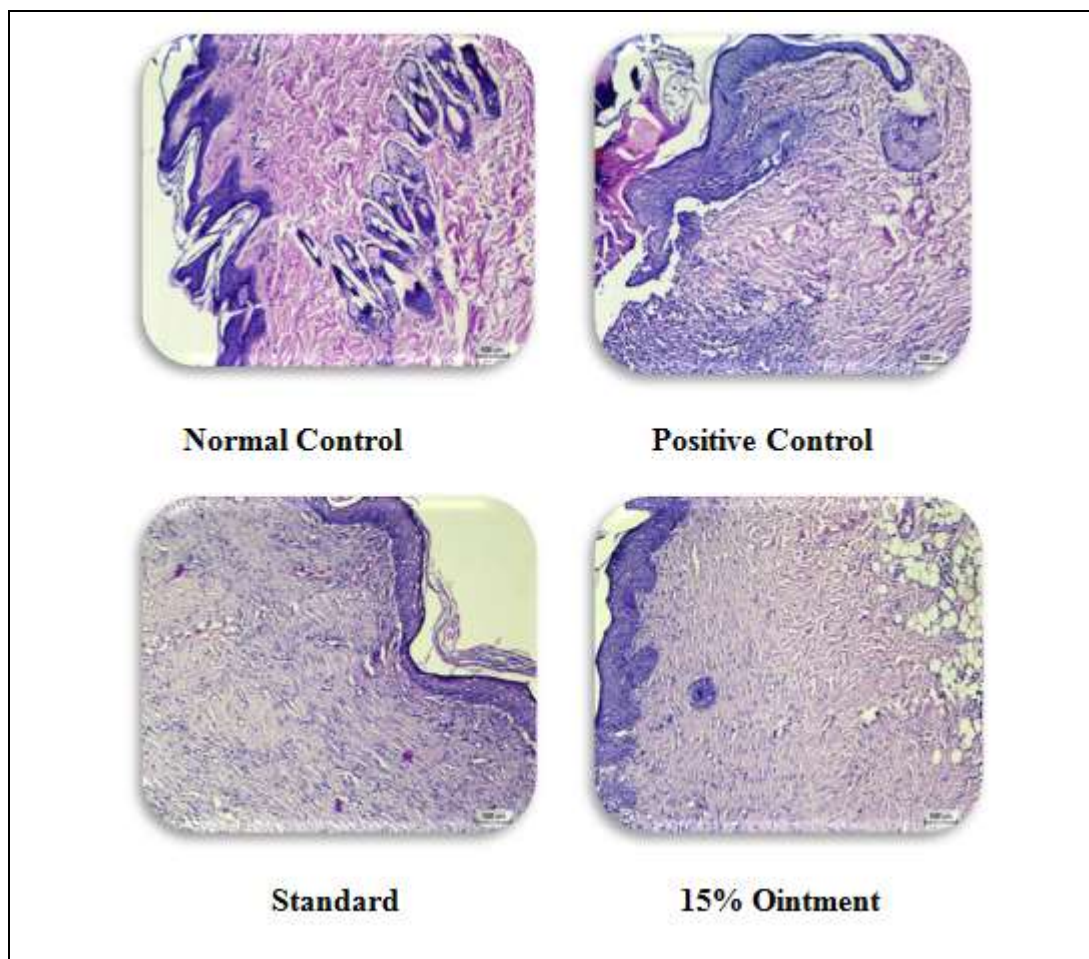


Figure:2 Effect on pro and anti-inflammatory parameters. The values are represented as Mean  $\pm$  SEM (n=6). The data was analysed by two way ANOVA followed by multiple comparison test. \*P<0.05, \*\*P<0.01, \*\*\*P<0.001 as compared to control group.

**Histopathological findings:**



**Figure 3: Histopathological Examination**

**Discussion**

The histopathological results of increased epithelization activity, angiogenesis, granulation tissue formation, and ultimately remodelling of the extracellular matrix were correlated with the significant reduction in wound size following DCEE ointment treatment. In addition to giving the tissue matrix strength and integrity, collagen is crucial for homeostasis and epithelialization in the later phases of wound healing.<sup>[13]</sup> A rare amino acid called hydroxyproline can be found in the collagen fibres of granulation tissues. After using DCEE ointment, biochemical study showed increased hydroxyproline content, a sign of increased cellular proliferation and consequently increased collagen synthesis. Higher electrostatic and ionic interactions stabilize collagen molecules, which are reflected by the increased hexosamine concentration.<sup>[14]</sup> Therefore, strengthened hydroxyproline and hexosamine synthesis gives restored tissue strength and promotes healing. After applying DCEE ointment, significant increases in hydroxyproline and hexosamine content were seen in the wounds; these results were corroborated by the histopathological data. Thus, the ethnotherapeutics assertion has been proven true thanks to DCEE's potent wound-healing properties, which are

demonstrated by the wound contracting and rising levels of biochemical parameters in healing tissue. Open wounds are especially vulnerable to infection, notably from bacteria, and they serve as a point of entry for organics that spread systemic infections. Infected lesions recover more slowly, and it frequently causes unpleasant exudates, the production of toxins, and the death of regenerating cells all at once.<sup>[15]</sup> Various antibiotics are presently being used to treat wound infections in humans.<sup>[16]</sup> However, due to their side effects and the presence of antibiotic resistant organisms, researchers are currently studying extracts with bioactive compounds isolated from plants used in herbal medicines.<sup>[17]</sup> The use of DCEE to treat various skin infections was demonstrated by this work because DCEE showed commendable activity against all organisms tested. Topical applications of DCEE to wounds prevent microorganisms from invading the wound through, thereby protecting the wound from infection by various organs. Strong induction of TNF- $\alpha$  and IL-6 after skin injury has been observed within 12 to 24 hours of injury. These components play an important role in the inflammatory phase of wound healing by enhancing angiogenesis.<sup>[18]</sup> Our study showed that, TNF-  $\alpha$  and IL-6 levels were slightly lower 24 hours after injury in animals treated with DCEE ointment. Therefore, it is clear that, DCEE ointment does not interfere with macrophage-derived pro-inflammatory cytokines during the early phase of wound healing. However, DCEE ointment treatment increased IL-10 levels by days 1 and 9 after injury. IL-10 is an anti-inflammatory cytokine produced by various cells including macrophages and T-cells. IL-10 appears to affect the healing environment by reducing the expression of pro-inflammatory/pro-fibrotic mediators. Thereby reducing the recruitment of inflammatory cells to the wound.<sup>[19]</sup> Treatment with DCEE ointment increased serum IL-10 concentration while down regulating the expression of TNF-  $\alpha$  and IL-6, particularly at day 9 post injury. TNF- $\alpha$  has been reported to inhibit the formation of collagen and the production of hydroxyproline is essential for the later stages of proliferative phase of wound healing.<sup>[20]</sup> The results suggests that, DCEE modulates the anti-inflammatory and pro-inflammatory cytokines and ultimately, the systemic immune pathways associated with them, leading to cell proliferation.

#### **Conclusion:**

The plant has potential anti-inflammatory and wound healing properties.

#### **Competing interests**

The authors declare that they have no competing interests.

#### **References:**

1. Singer AJ, Clark RA. Cutaneous wound healing. *New England journal of medicine*. 1999 Sep 2;341(10):738-46.
2. Ibrahim AA, Bagherani N, Smoller B, Reyes-Barron C, Bagherani N. Functions of the skin. In *Atlas of Dermatology, Dermatopathology and Venereology: Cutaneous Anatomy, Biology and Inherited Disorders and General Dermatologic Concepts 2021* Oct 7 (pp. 133-143). Cham: Springer International Publishing.
3. Healing Societies (WUWHS). Wound infection in clinical practice: an international consensus.
4. Wallace HA, Basehore BM, Zito PM. Wound healing phases.

5. Arun M, Satish S, Anima P. Evaluation of wound healing, antioxidant and antimicrobial efficacy of *Jasminum auriculatum* Vahl. leaves. *Avicenna journal of phytomedicine*. 2016 May;6(3):295.
6. Tiwari VK. Burn wound: How it differs from other wounds?. *Indian journal of plastic surgery*. 2012 May;45(02):364-73.
7. Rowan MP, Cancio LC, Elster EA, Burmeister DM, Rose LF, Natesan S, Chan RK, Christy RJ, Chung KK. Burn wound healing and treatment: review and advancements. *Critical care*. 2015 Dec;19:1-2.
8. Kumarasamy Y, Nahar L, Byres M, Delazar A, Sarker SD. The assessment of biological activities associated with the major constituents of the methanol extract of 'wild carrot' (*Daucus carota* L.) seeds. *Journal of herbal pharmacotherapy*. 2005 Jan 1;5(1):61-72.
9. Banu KS, Cathrine L. General techniques involved in phytochemical analysis. *International journal of advanced research in chemical science*. 2015 Apr;2(4):25-32.
10. Chen WC, Liou SS, Tzeng TF, Lee SL, Liu IM. Wound repair and anti-inflammatory potential of *Lonicera japonica* in excision wound-induced rats. *BMC Complementary and Alternative Medicine*. 2012 Dec;12(1):1-9.
11. Koduru S, Grierson DS, Afolayan AJ. Antimicrobial Activity of *Solanum aculeastrum*. *Pharmaceutical biology*. 2006 Jan 1;44(4):283-6.
12. Ahanger AA, Leo MD, Gopal A, Kant V, Tandan SK, Kumar D. Pro-healing effects of bilirubin in open excision wound model in rats. *International wound journal*. 2016 Jun;13(3):398-402.
13. Landsman A, Taft D, Riemer K. The role of collagen bioscaffolds, foamed collagen, and living skin equivalents in wound healing. *Clinics in podiatric medicine and surgery*. 2009 Oct 1;26(4):525-33.
14. Ricard-Blum S, Ruggiero F. The collagen superfamily: from the extracellular matrix to the cell membrane. *Pathologie Biologie*. 2005 Sep 1;53(7):430-42.
15. Black CE, Costerton JW. Current concepts regarding the effect of wound microbial ecology and biofilms on wound healing. *Surgical Clinics*. 2010 Dec 1;90(6):1147-60.
16. Atiyeh BS, Dibo SA, Hayek SN. Wound cleansing, topical antiseptics and wound healing. *International wound journal*. 2009 Dec;6(6):420-30.
17. Miyasaki Y, Nichols WS, Morgan MA, Kwan JA, Van Benschoten MM, Kittell PE, Hardy WD. Screening of herbal extracts against multi-drug resistant *Acinetobacter baumannii*. *Phytotherapy Research*. 2010 Aug;24(8):1202-6.
18. Daley JM, Brancato SK, Thomay AA, Reichner JS, Albina JE. The phenotype of murine wound macrophages. *Journal of leukocyte biology*. 2010 Jan;87(1):59-67.
19. Sato Y, Ohshima T, Kondo T. Regulatory role of endogenous interleukin-10 in cutaneous inflammatory response of murine wound healing. *Biochemical and biophysical research communications*. 1999 Nov 11;265(1):194-9.
20. Siqueira MF, Li J, Chehab L, Desta T, Chino T, Krothpali N, Behl Y, Alikhani M, Yang J, Braasch C, Graves DT. Impaired wound healing in mouse models of diabetes is

mediated by TNF- $\alpha$  dysregulation and associated with enhanced activation of forkhead box O1 (FOXO1). *Diabetologia*. 2010 Feb;53:378-88.