



## MORPHOLOGICAL CONDYLAR CHANGES FOLLOWING FIXED FUNCTIONAL APPLIANCE THERAPY

Satnam singh<sup>1</sup>, Rahul Khullar<sup>2</sup>, Sudhir Munjal<sup>3</sup>, Harmeet Singh<sup>4</sup>, Eknor Kaur<sup>5</sup>,  
Sonali Batta<sup>6</sup>

<sup>1</sup>Professor, <sup>2,5,6</sup>Post Graduate Student (Final Year), <sup>3</sup>Professor & Head, <sup>4</sup>Associate Professor, Department of Orthodontics & Dentofacial Orthopaedics, Dasmesh Institute of Research & Dental Sciences, Faridkot (Punjab), India

Corresponding author- Satnam Singh, Professor, Department of Orthodontics & Dentofacial Orthopedics, Dasmesh Institute of Research & Dental Sciences, Faridkot (Punjab), India, Mob no. 9780408546

---

### ABSTRACT

Morphological changes of the condyle are a sequel of orthodontic treatment which can be noted radiographically. Morphological changes can be either in the form of condylar remodelling or resorption.

**OBJECTIVES:** The purpose of this study was to evaluate condylar remodeling, condylar resorption and difference in height to width ratio of condyle after fixed functional appliance therapy.

**MATERIAL AND METHOD:** Twenty patients of fixed functional appliance therapy were selected for the study. Pre-treatment and post-treatment orthopantomograms of these 20 patients were taken and compared for evaluating condylar remodeling or resorption. The condyles were categorized based on modified Krajenbrink classification of TMJ. **RESULTS:** The results revealed that there was no significant change in the height to width ratio of condyle after fixed functional appliance therapy revealing no condylar resorption. Except for 1 subject, all the condyles fall under the category of Type C and D according to modified Krajenbrink classification after the treatment. 1 subject fall under the category of Type A after the fixed functional appliance therapy.

**CONCLUSION:** The study concluded that no resorption occurred in any of the subject following fixed functional appliance therapy. Only condylar remodeling had occurred in all the subjects.

**KEYWORDS:** Temporomandibular Joint, Condyle, Fixed Functional Appliances, Remodelling, Resorption, Orthopantomogram.

---

## INTRODUCTION

The temporomandibular joint (TMJ) is an articulation that allows free movement between the mandible's condyle and the squamous region of the temporal bone located at the skull's base. This joint's primary purpose is to facilitate seamless and efficient motion of the mandible during essential activities such as mastication, swallowing, and speech.

The mandibular condyle is a crucial component due to its role in mandibular growth expression. Generally, it is presumed that the condylar head must maintain a convex form and exhibit symmetry between opposite sides within an individual. A normal dentofacial alignment categorized as Class I shows the condyle's centered position within the glenoid fossa. However, in Class III malocclusion, the condyle moves anteriorly, while in Class II malocclusion, it shifts more anteriorly within the glenoid fossa than in Class I.<sup>1</sup>

The management of Class II malocclusion can be effectively addressed with fixed functional appliances, which is the sole successful treatment option for non-compliant postpubertal patients that can avert the need for subsequent orthognathic surgery. These appliances are capable of correcting skeletal issues of Class II by stimulating mandibular growth while also inducing dentoalveolar effects.<sup>2</sup>

Fixed functional appliances trigger adaptative alterations in the glenoid fossa, inducing growth modulation of the condylar cartilage. The treatment's effects on the temporomandibular joint (TMJ) in young adults and adolescents include condylar remodeling, glenoid fossa remodeling, shifts in the condyle's position within the fossa, and changes in the articular disc's position.<sup>3</sup>

Orthodontic treatment may lead to morphological transformations of the condyle, detectable through radiographic assessments. These changes may manifest as either condylar remodeling or resorption.<sup>4</sup>

The present study aims to assess alterations in the condyle's morphology subsequent to therapy with fixed functional appliances.

## MATERIALS & METHOD

A total of 20 cases of fixed functional appliance therapy were selected from Department of Orthodontics & Dentofacial Orthopedics, Dasmesh Institute of Research & Dental Sciences, Faridkot.

## INCLUSION CRITERIA

1. Patients who underwent fixed functional appliance therapy

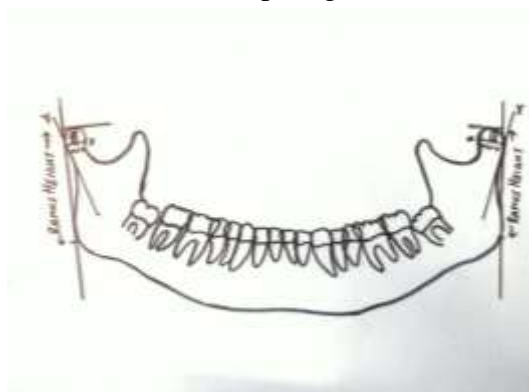
## EXCLUSION CRITERIA

1. Patients who underwent previous orthognathic surgery
2. TMJ deviation

3. Patients with history of joint trauma
4. Patients with any systemic disease

Pre-treatment and Post-treatment orthopantomograms of patients were taken who had undergone fixed functional appliance therapy and the same was traced using tracing sheet made of lead acetate 0.05mm thickness in which a ramus tangent and a line drawn perpendicular to it through the most superior point of the condyle was drawn. The distance from the top of the condyle to the inferior point of tangency was measured as Ramus Height (RH).

The contour of the condyle was assessed. The condyle was defined by the tangent to the posterior border of the condylar neck (Y-axis) and a line drawn perpendicular to the condyle tangent through the broadest point of the condyle (X-axis). The top of the condyle was related to the midpoint on the X-axis. The contour of the condyle was determined by the condylar height (H)-to-width (W) ratio and the location of the top (Figure 1).



**FIGURE 1: Construction of reference lines and planes**

The surface of the condyle was subdivided in an anterior, superior, and posterior part (Figure 2).



**FIGURE 2: Anterior, superior and posterior parts of condyle**

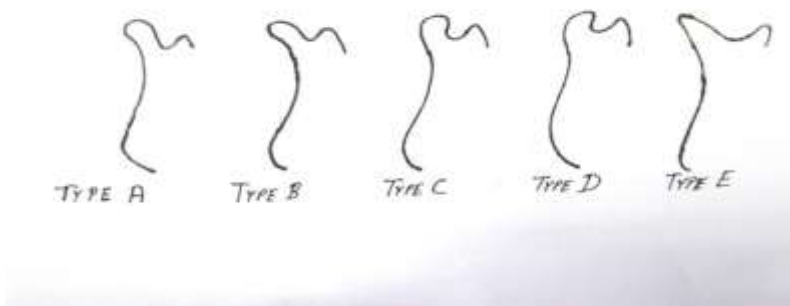
The condyles were categorized based on modified Krajenbrink classification of TMJ (Figure 3):  
Type A : The condyle has a height-to-width ratio equal to or more than 1. The top of the condyle is situated posterior of the horizontal midpoint.

Type B : The condyle has a height-to-width ratio less than 1. The top of the condyle is situated posterior of the horizontal midpoint. The superior part of the condylar neck is curved posteriorly.

Type C : The condyle has a height-to-width ratio less than 1. The top of the condyle is situated halfway along the X-axis. The condyle has rounded superior surface.

Type D : The condyle has a height-to-width ratio less than 1. The top of the condyle is situated anterior to the horizontal midpoint. The superior part of the condylar neck is curved anteriorly.

Type E : Spiky and finger-shaped condyle on which the most protruding point (belly) cannot be identified.<sup>5</sup>



**FIGURE 3: Different types of condylar forms classified by condylar height-to-width ratio and location of top**

Based on the above condylar condition on OPG, it was classified into-

- No condylar change
- Condylar remodeling
- Condylar resorption

Condylar remodeling is characterized by morphologic changes, but with stable ramus height not leading to relapse. Condylar remodeling was judged according to the following parameters:

- (a) Minor bone resorption and/or bone apposition on one of the condylar sites;
- (b) Ramus height, as measured on radiographs at one-year or long term follow up was compared with the pre-operative or immediately post-operative radiographs, should differ less than or be equal to 6%.

Condylar resorption is characterized by severe morphologic changes with decreased condylar configuration, volume and decreased ramus height. Condylar resorption was judged according to the following parameters:

- (a) Major bone resorption with or without bone apposition and reduction of condylar contour and volume;

(b) Ramus height as measured on radiographs at the one-year or long-term follow up was compared with the pre-operative or immediately post-operative ones should differ more than 6%.<sup>6</sup>

## RESULTS

The contour of the condyle of left side was assessed on the basis of height to the width ratio. On comparing the height to width ratio of the condyle for pre-treatment orthopantomograms, the mean value was found to be 0.611 with standard deviation and standard error of 0.159 and 0.035 respectively. Similarly, for the left side, on comparison of height to width ratio of the condyle, for post-treatment orthopantomograms after one year, the mean value was found to be 0.638 with standard deviation and standard error of 0.195 and 0.043 respectively. By performing paired t-test between two groups the 'P' value was found to be 0.581 (i.e.  $p > 0.05$ ) which revealed that the difference between the pre and post-treatment values of height to width ratio of the condyle of left side was non-significant.

The contour of the condyle of right side was assessed on the basis of height to the width ratio. On comparing the height to width ratio of the condyle for pre-treatment orthopantomograms, the mean value was found to be 0.619 with standard deviation and standard error of 0.159 and 0.035 respectively. Similarly, for the right side, on comparison of height to width ratio of the condyle, for post-treatment orthopantomograms after one year, the mean value was found to be 0.638 with standard deviation and standard error of 0.177 and 0.039 respectively. By performing paired t-test between two groups the 'P' value was found to be 0.689 (i.e.  $p > 0.05$ ) which revealed that the difference between the pre and post-treatment values of height to width ratio of the condyle of left side was non-significant.

The condylar remodeling of the left side was assessed on the basis of ramus height. On comparing the ramus height for pre-treatment orthopantomograms, the mean value was found to be 44.932 with standard deviation and standard error of 6.769 and 1.513 respectively. Similarly, for the left side, on comparison of ramus height, for posttreatment orthopantomograms after one year, the mean value was found to be 46.171 with standard deviation and standard error of 6.910 and 1.545 respectively. By performing paired t-test between two groups the 'P' value was found to be 0.027 (i.e.  $p < 0.05$ ) which revealed that the difference between the pre and post-treatment values of ramus height of left side was significant.

The condylar remodeling of the right side was assessed on the basis of ramus height. On comparing the ramus height for pre-treatment orthopantomograms, the mean value was found to be 45.697 with standard deviation and standard error of 6.684 and 1.494 respectively. Similarly, for the right side, on comparison of ramus height, for posttreatment orthopantomograms after one year, the mean value was found to be 46.803 with standard deviation and standard error of 6.775 and 1.514 respectively. By performing paired t-test between two groups the 'P' value was found to be 0.019 (i.e.  $p < 0.05$ ) which revealed that the difference between the pre and post-treatment values of ramus height of left side was significant.

The condyles were categorized on the basis of modified Krajenbrink classification of TMJ. On the left side during the pre-treatment phase, none of the condyles were categorized as Score-A. 70.0% of the condyles (i.e. 14 subjects) were categorized as Score-C. 30% of the condyles (i.e. 6 subjects) were categorized as Score-D. Similarly, on the left side, at the post-treatment phase 85% of the condyles (i.e. 17 subjects) were categorized as Score-C and 15% of the condyles (i.e. 3 subjects) were categorized as Score-D. By performing chi-square test, the 'P' value was found to be 0.206 (i.e.  $P>0.05$ ) which revealed that the difference between pre & post-treatment values of modified Krajenbrink classification of left side was non-significant.

On the right side during the pre-treatment phase, 100.0% of the condyles (i.e. 20 subjects) were categorized as Score-C. Similarly, on the right side, at the post-treatment phase 90% of the condyles (i.e. 18 subjects) were categorized as Score-C, 5% of the condyles (i.e. 1 subject) was categorized as Score-A and 5% of the condyles (i.e. 1 subject) was categorized as Score-D. By performing Chi-square test, the 'P' value was found to be 0.249 (i.e.  $P>0.05$ ) which revealed that the difference between the pre and posttreatment values of modified Krajenbrink classification of right side was non-significant

## DISCUSSION

This study aimed to evaluate changes in the condyle subsequent to fixed functional appliance therapy. A total of 20 participants meeting the inclusion criteria were selected from individuals who received treatment at the Orthodontics & Dentofacial Orthopedics Department of Dasmesh Institute of Research & Dental Sciences in Faridkot.

The study involved obtaining pre- and post-treatment radiographs of patients who underwent fixed functional appliance therapy. The height-to-width ratio of the left and right condyles was measured in pre-treatment subjects and compared with post-treatment subjects. Interestingly, no significant differences were observed between pre- and post-treatment values, indicating no discernible changes in the condyle after fixed functional appliance therapy. This observation is consistent with the findings of Kinzinger et al. (2006), who examined the effects of fixed functional orthopedic appliances on the positions of the condyle and glenoid fossa in patients with skeletal Class II malocclusions. Their study showed that upon adoption of the therapeutic position, the condyles were displaced from the centric position within the fossa toward caudal and ventral directions, but returned to their original position at the end of treatment. Furthermore, the width of the anterior or posterior joint spaces did not differ significantly from initial findings.<sup>7,8</sup>

Habets et al. (1987) have reported on the accuracy of orthopantomographic radiographs in determining the vertical dimension images of the condyles and rami. Technical errors may cause differences of up to 6% between the left and right sides due to magnification. In the present study, preoperative and immediately post-operative orthopantomographic radiographs did not reveal any differences between the right and left side exceeding the 6% threshold.<sup>9</sup>

In our study, the height of the ramus was measured from the top of the condyle to the inferior point of the ramus tangent. The findings indicated that in 12 of the subjects, there was a slight increase in ramus height in the post-treatment phase. However, since this increase was less than 6%, it suggested that condylar remodeling had taken place in these subjects. Similarly, in 8 subjects, there was a decrease in ramus height, but as the decrease was also less than 6%, it suggested that condylar remodeling had occurred in these cases. Carbonell et al. (2016) provided further support for these observations by reporting that treatment with functional appliances resulted in a more advanced position of the condyle, with remodeling of the condyle and adaptation of the morphology of the glenoid fossa. Singh et al. (2020) also demonstrated that both the Twin Block and Herbst groups showed significant improvement in anterior-posterior skeletal discrepancy, with a significant increase in mandibular length. Although the duration of treatment was shorter for the Herbst group, both groups showed a significant increase in lower anterior and posterior face height and ramus height.<sup>10</sup>

The accuracy of superimposing tracings of rami and condyles on orthopantomographic radiographs was found to be inadequate unless the horizontal and vertical magnification factors were considered. Therefore, Krajenbrink's modification of Berry's classification was deemed more suitable for analyzing the expected changes in condylar images on orthopantomographic radiographs.

The condyles were categorized according to modified Krajenbrink classification. It was observed that all condyles fall in Groups A, C and D.

During the pre-treatment phase on the left side, none of the condyles were classified as Score-A, with 70.0% being categorized as Score-C and 30% as Score-D. In the post-treatment phase on the left side, 85% of the condyles were classified as Score-C and 15% as Score-D. Comparison of the left-side condyles before and after treatment revealed no significant difference, indicating no significant change in the condyle following fixed functional appliance therapy. This finding is consistent with the results of Habets et al. (1987), who reported that the reliability of the vertical dimension images of the two condyles and their rami in orthopantomographic radiographs may be affected by technical errors, resulting in differences of up to 6% between the left and right sides.

During the pre-treatment phase on the right side, all of the condyles were classified as Score-C. At the post-treatment phase, 90% of the condyles were classified as Score-C, while 5% were classified as Score-A and 5% were classified as Score-D. Upon comparing the pre and post-treatment condyles on the right side, no significant changes were observed after fixed functional appliance therapy. These findings were corroborated by Ezhil et al.'s (2018) study, which demonstrated that modified Krajenbrink classification-based comparison of pre-operative and one-year follow-up orthopantomograms revealed remodeling of both condyles in all patients who underwent orthodontic treatment. Furthermore, 75% of the 20 patients reported an improvement in their TMJ symptoms one year after undergoing orthodontic treatment and orthognathic surgery.<sup>11</sup>

## **CONCLUSION**

The objectives of this study were to evaluate condylar remodeling, condylar resorption and difference in height to width ratio of both the condyles after fixed functional appliance therapy.

The results revealed that:

1. There was no significant change in the height to width ratio of condyle after fixed functional appliance therapy revealing no condylar resorption.
2. In 12 subjects, there was slight increase in ramus height after fixed functional appliance therapy but as this difference in height was less than 6%, it revealed that condylar remodeling had occurred in these subjects. In 8 subjects, there was slight decrease in ramus height but as this difference in height was also less than 6%, it revealed condylar remodeling had occurred in these subjects.
3. Except for 1 subject, all the condyles fall under the category of Type C and D according to modified Krajenbrink classification after the treatment. 1 subject fall under the category of Type A after the fixed functional appliance therapy.

The study concluded that no resorption occurred in any of the subject following fixed functional appliance therapy. Only condylar remodeling had occurred in all the subjects.

## **SUMMARY**

Morphological changes of the condyle are a sequel of orthodontic treatment which can be noted radiographically. Morphological changes can either be in the form of condylar remodeling or resorption.

Condylar remodeling is characterized by morphological changes, but with stable ramus height not leading to relapse whereas condylar resorption is characterized by severe morphologic changes with decreased ramus height.

The aim of the study was to evaluate morphological changes of condyle following fixed functional appliance therapy. Twenty patients of fixed functional appliance therapy were selected for the study. Pre-treatment and post-treatment orthopantomograms of these 20 patients were taken and compared for evaluating condylar remodeling or resorption. The linear measurements obtained from orthopantomograms were statistically analysed using paired t-test and Chi-square test. All the statistical analysis were performed at the level of significance i.e. 'P' value <0.05.

The results revealed that there was no significant change in the height to width ratio of condyle after fixed functional appliance therapy revealing no condylar resorption. It also revealed that there was slight increase in ramus height after fixed functional appliance therapy revealing condylar remodeling had occurred. Except for 1 subject, all the condyles fall under the category



of Type C and D according to modified Krajenbrink classification. Only 1 subject fall under the category of Type A after the fixed functional appliance therapy.

The study concluded that resorption occurred in none of the subject following fixed functional appliance therapy. Only condylar remodeling had occurred in all the subjects.

## REFERENCES

1. Arici, S., Akan, H., Yakubov, K. and Arici, N., 2008. Effects of fixed functional appliance treatment on the temporomandibular joint. *American journal of orthodontics and dentofacial orthopedics*, vol. 133, no. 6, pp. 809-814.
2. Panigrahi, P. and Vineeth, V., 2009. Biomechanical effects of fixed functional appliance on craniofacial structures. *The Angle Orthodontist*, vol. 79, no. 4, pp. 668-675.
3. Rai, P., Gandhi, A. and Tripathi, T., Effects of Fixed Functional Appliance Therapy on Temporomandibular Joint Assessed by MRI: A Literature Review. *International Journal of science and Research*, vol. 8, no. 11, pp. 1057-1063.
4. Ezhil, I., Arun, A.V. and Kumar, M.P., 2018. Morphological changes of the mandibular condyle following orthodontic treatment. *Drug Invention Today*, vol. 10, no. 1, pp. 2802-2804.
5. Hoppenreijts, T.J., Freihofer, H.P.M., Stoelinga, P.J., Tuinzing, D.B. and van't Hof, M.A., 1998. Condylar remodelling and resorption after Le Fort I and bimaxillary osteotomies in patients with anterior open bite: A clinical and radiological study aesthetic and reconstructive surgery. *International journal of oral and maxillofacial surgery*, vol. 27, no. 2, pp. 81-91.
6. Habets, L.L.M.H., Bezuur, J.N., Naeiji, M. and Hansson, T.L., 1988. The Orthopantomogram®, an aid in diagnosis of temporomandibular joint problems. II. The vertical symmetry. *Journal of oral rehabilitation*, vol. 15, no. 5, pp. 465-471.
7. Kinzinger, G., Gülden, N., Roth, A. and Diedrich, P., 2006. Discondyle relationships during Class II treatment with the Functional Mandibular Advancer (FMA). *Journal of Orofacial Orthopedics / Fortschritte der Kieferorthopädie*, vol. 67, no. 5, pp. 356-375.
8. Kinzinger, G., Kober, C. and Diedrich, P., 2007. Topography and morphology of the mandibular condyle during fixed functional orthopedic treatment - a magnetic resonance imaging study. *Journal of Orofacial Orthopedics / Fortschritte der Kieferorthopädie*, vol. 68, no. 2, pp. 124-147.
9. Hegde, S., Praveen, B.N. and Shetty, S.R., 2013. Morphological and radiological variations of mandibular condyles in health and diseases: a systematic review. *Dentistry*, vol. 3, no. 1, pp. 154.
10. Singh, D.P. and Kaur, R., 2018. Fixed functional Appliances in Orthodontics-A review. *J Oral Health Craniofac Sci*, vol. 3, pp. 001-010.
11. Kaur, A., Natt, A.S., Mehra, S.K., Maheshwari, K. and Singh, G., 2016. Improved Visualization and Assessment of Condylar Position in the Glenoid Fossa for Different Occlusions: A CBCT Study. *The journal of contemporary dental practice*, vol. 17, no. 8, pp. 679-686.