



## Ovarian germ cell tumors clinicopathological characteristics and treatment outcome

Maryam Vaezi 1, Fatemeh Abdali 1\*, Parvin Sarbakhsh 2, Manizheh Sayyahmelli 3, Parvin Mostafa Gharebaghi 3, Mehri Jafari Shobeiri 3, Vahide Rahmani 3

1. Women's Reproductive Health Research Center, Tabriz University of Medical Sciences, Tabriz, Iran
2. Department of Statistics and Epidemiology, School of Public Health, Tabriz University of Medical Sciences, Tabriz, Iran
3. Fellowship Oncology, Al-zahra Hospital, Tabriz University of Medical Sciences, Tabriz, Iran

\***Corresponding author:** Fatemeh Abdali, Women's Reproductive Health Research Center, Tabriz University of Medical Sciences, Tabriz, Iran

Email: [abadifatemeh1@gmail.com](mailto:abadifatemeh1@gmail.com)

DOI: 10.48047/ecb/2023.12.5.253

### Abstract

**Background:** Ovarian germ cell tumors have low incidence and are responsible for about 20% of ovarian tumors. The current study aimed to analyze the clinicopathological features and treatment outcomes and subsequent fertility outcomes in patients with ovarian germ cell tumors and to increase awareness of this condition.

**Material and Methods:** This is a retrospective descriptive study on ovarian germ cell tumor patients treated in Alzahra Hospital, the teaching and tertiary referral hospital in Tabriz, between 2011 to 2022.

**Results:** 37 patients with ovarian germ cell tumors were identified. The mean age of the patients was 23.92 years old, and the most common chief complaint was abdominal pain. 90.32% of patients were diagnosed with stage I neoplasm. None of the patients had bilateral ovary involvement, and tumor recurrence was reported in 7.9% of patients. 71.1% of patients underwent adjuvant chemotherapy, and 86.84% of patients did not use assisted reproductive technology for fertility. From the histopathological point of view, dysgerminoma was the most commonly diagnosed ovarian germ cell tumor (36.8%). In our patients, the most commonly elevated tumor markers were LDH and AFP (39.47%).

**Conclusion:** Ovarian germ cell tumors patients have an excellent prognosis, and the current treatment with surgery and adjuvant chemotherapy does not substantially affect their fertility.

**Keywords:** Ovarian germ cell tumors, Chemotherapy, Prognosis, clinicopathological findings, descriptive study.

## **1. Introduction**

Ovarian germ cell tumors are rare neoplasms that arise from primitive germ cells of the ovary; they are responsible for 20% of all ovarian neoplasms (1). The underlying cause of ovarian germ cell tumors remains unknown; however, pregnancy and estrogen exposure have been implicated in their development (2). From the histopathological point of view, these tumors are classified into dysgerminoma, yolk sac tumor, embryonal carcinoma, non-gestational choriocarcinoma, mature teratoma, immature teratoma, and mixed germ cell tumor, Based on the classification of the World Health Organization (3). In the United States, their incidence is 1000-2000 cases per year, and females before the age of 20 are mostly affected (4).

The most commonly associated sign and symptoms are abdominal enlargement and palpable pelvic-abdominal mass; amenorrhea can also be present in some affected patients. Fever, vaginal bleeding, and abdominal distension are the less commonly encountered signs and symptoms. In 10% of cases, acute abdominal pain due to the complications of ovarian germ cell tumors, e.g., rupture, can be developed (5). From the laboratory standpoint, elevated levels of human chorionic gonadotropin (hCG),  $\alpha$ -fetoprotein (AFP), and lactate dehydrogenase (LDH) can be suggestive of these neoplasms (6). More specifically, an elevated level of AFP is seen in yolk sac tumors and approximately 30% of immature teratomas; an increased level of hCG is observed in choriocarcinoma, and occasionally increased level of LDH is observed in patients with dysgerminoma (5).

Abdomino- pelvic spiral CT scan with and without intravenous and oral contrast and chest CT scan without contrast are recommended to determine the extent of the disease and metastasis workup. Since ovarian germ cell tumors can develop in dysgenetic gonads, the karyotype is recommended in highly suspicious cases. The presence of the Y chromosome can lead to gonadoblastoma and increase the likelihood of cancerous transformation (3). When the diagnosis of ovarian germ cell tumor is highly suspected, fertility-sparing surgery is indicated for histopathological diagnosis and determining the extent of the neoplasm. Considering the fact that these ovarian tumors usually develop in child-bearing ages, radical surgery nor biopsy of the unaffected ovary is not indicated (3, 7). Overall, the prognosis of

affected patients with surgery and chemotherapy is excellent, and the 5-year survival of patients is above 85% (8).

Due to the low prevalence of ovarian germ cell tumors, there aren't many comprehensive studies in this regard. For this reason, The current study aimed to analyze the clinicopathological features and treatment outcomes and subsequent fertility outcomes in patients with ovarian germ cell tumors diagnosed with these tumors between 2011 to 2022 In a tertiary referral center in the northwest of the country in Iran – Tabriz.

## **2. Material and Methods**

This is a retrospective descriptive study to investigate the clinicopathologic and treatment outcome of patients with ovarian germ cell tumors that underwent surgery and were followed up at the oncology department of Alzahra Hospital between 2011 to 2022.

The inclusion criteria were patients who underwent surgery in this center, followed up, and their final pathology was reported as ovarian germ cell tumor. Those who could not be reached for follow-up were excluded from the study, which was one case in this study.

All patients were operated by Gynecology Oncology Fellowship. Surgery in most patients was performed conservatively based on NCCN global guidelines with preservation of fertility. Standard surgery included laparotomy with midline incision and preparation of peritoneal cytology, unilateral Salpingo ophorectomy and infracolic omentectomy, lymphadenectomy, biopsy of bilateral paracolic gutters and tumore debulking.

To decide on adjuvant treatment after surgery, all patients were discussed at Tumor board Gynecology Oncology meetings, and their treatment and follow-up plans were determined. In our center, After completing the treatment, including surgery and adjuvant treatment of the patients, the regular follow-up program is done every 1-3 months for 2 years, then every 6 months for the next 3 years, and then annually. If the patients do not come for the next visits, the follow-up nurse reminds the patients of the follow-up visits schedule by calling.

The following information was extracted from the patients' medical files; the age of diagnosis, the patients' chief complaint, the follow-up time, tumor stage based on the International Federation of Gynecology and Obstetrics (FIGO), tumor histopathology, post-operation complications, chemotherapy regimens received, tumor marker positivity (LDH, AFP, cancer antigen-125 (CA-125),  $\beta$ -hCG, carcinoembryonic antigen (CEA), inhibin A), recurrence rate, tumor recurrence anatomical place, bilateral or unilateral involvement of the

ovaries, and the fertility of patients, disease-free period and patient survival. The rest of the patients' information was collected in terms of their current health status, menstrual cycles, fertility outcomes, through phone calls and patients' attendance at the oncology clinic and their visits.

Descriptive statistical analyses were done with SPSS software v.20.0 (SPSS Inc, Chicago, USA). Survival analysis was done using Kaplan–Meier method. Disease-free survival rate (DFSr) was defined as the time from diagnosis to the date of recurrence. Overall survival rate(OSR) was defined as the time from diagnosis to the date of death or last follow-up.

This study was approved by the Ethics Committee of Tabriz University of Medical Sciences (IR.TBZMED.REC.1401.792).

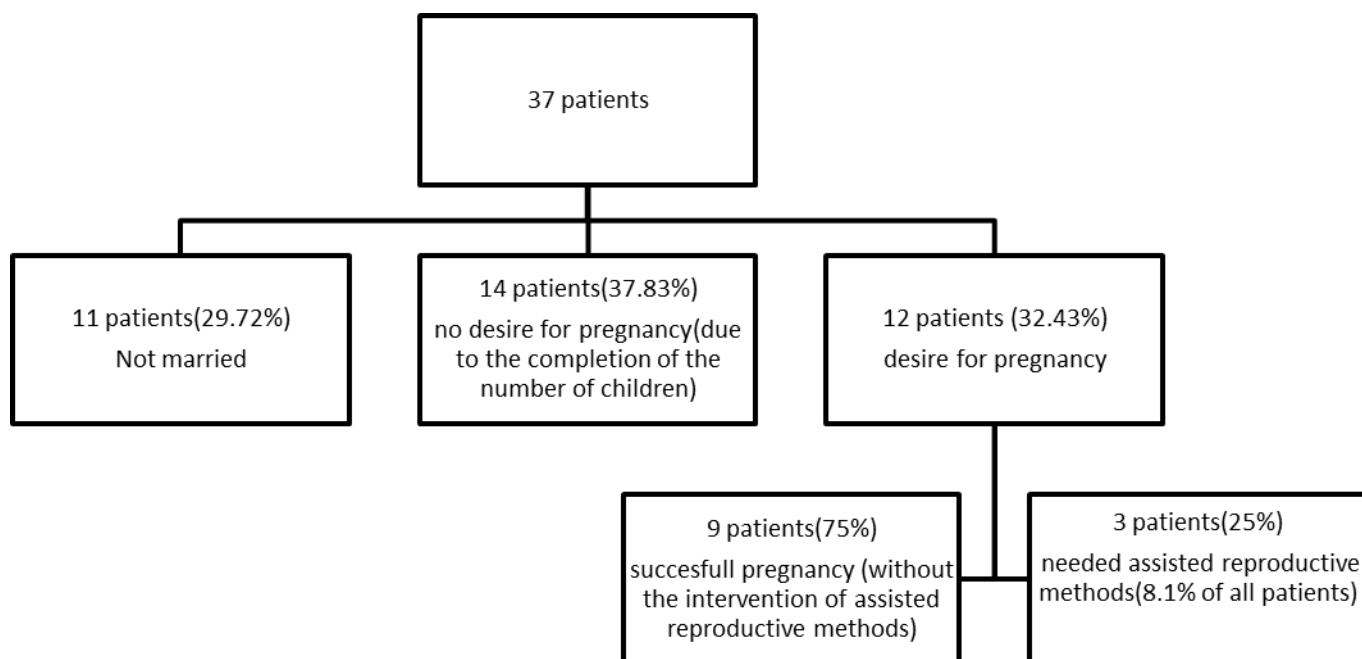
### 3. Results

#### 3.1. Primary and fertility information of included patients

Based on the above-mentioned criteria, our search in the oncology department of Alzahra Hospital led to the identification of 38 patients with ovarian germ cell tumors. One patient was excluded from the study due to the lack of access to follow-up in this center. The mean age of diagnosis was 23.92 years old, and the follow-up period was 4.5 years. According to the occurrence of germ cell tumors at young ages in this study, 11(29.72%) of the 37 patients under investigation were not married and did not want to get pregnant, 14(37.83%) of them did not want to get pregnant due to the completion of the number of children. 12 (32.43%) cases tried to get pregnant that 9(75%) had a successful pregnancy without the intervention of assisted reproductive methods. 3(25%) cases needed assisted reproductive methods due to delay in fertility. Only 8.1% of all patients used fertility with assisted reproductive technologies. (figure 1). On average, the labor of patients started at 39.29 weeks of gestation (Table. 1).

**Table. 1** The basic and fertility information of included patients

	Mean	Std. deviation
Age of diagnosis (year)	23.92	7.638
Follow-up period (year)	4.5	1.6279
Week of labor	39.29	1.254



**Figure 1**-Patient distribution according to pregnancy desire

### 3.2. Clinicopathological and surgical information of included patients

The most frequently documented chief complaint was abdominal pain. None of the patients had undergone neoadjuvant chemotherapy, but most of them went through adjuvant chemotherapy (72.97% of cases) according to the NCCN guidelines. None of the patients developed bilateral ovarian germ cell tumors. Post-operation complications were rarely reported (one case-2.7% of patients).

Three cases of patients (8.1%) experienced tumor recurrence. Lung, cul-de-sac, and para-aorta regions were the anatomical places of tumor recurrence. From the histopathological point of view, dysgerminoma was the most reported ovarian germ cell tumor(41% of patients) (Table. 2). Due to the fact that the patients were of reproductive age, most of the patients, which included 34 cases( 91.89%) in our study, were subjected to conservative surgery including one-sided salpingo-oophorectomy, bilateral pelvic lymphadenectomy, para-aortic lymphadenectomy and omentectomy. 3 cases(8.1%) due to the completeness of the number of children and unwillingness To get pregnant again, underwent complete surgery

including hysterectomy and bilateral salpingo-oophorectomy, bilateral pelvic lymphadenectomy and para-aortic lymphadenectomy and omentectomy.

**Table. 2** Clinicopathological information of included patients

		No.	Percentage
Chief complaint	Abdominal pain	26	70.27%
	Abdominal enlargement	11	29.72%
Neoadjuvant chemotherapy	Yes	0	0%
	No	37	100%
Adjuvant chemotherapy	Yes	27	72.97%
	No	10	27.03%
Ovary involvement	Unilateral	37	100%
	Bilateral	0	0%
Tumor recurrence	Yes	3	8.1
	No	34	91.9
Anatomical place of tumor recurrence	Cul-de-sac	1	33.33%
	Para-aorta	1	33.33%
	Lung	1	33.33%
Stage	I	34	91.89%
	II	1	2.7%
	III	2	5.4%
	IV	0	0%
Surgery	complete	3	8.1%
	conservative	34	91.89%
Post-operation complications	Present	1	2.7%
	Absecent	36	97.3%
Histopathological type	Dysgerminoma	15	40.54%
	mixed germ cell tumor	12	32.43%
	Immature teratoma	8	21.62%
	Yolk sac tumor	2	5.4%

### 3.3. Tumor biomarkers in the included patients

Regarding the tumor biomarkers, most of the patients did not demonstrate increased levels of studied tumor biomarkers; however, the most commonly elevated tumor markers are LDH, AFP, and CA-125. Inhibin A was the least commonly elevated tumor marker in the patients (Table. 3).

**Table. 3** Tumor biomarker status of the patients

		No.	Percentage
LDH	Elevated	15	39.47%
	Not elevated	22	57.89%
AFP	Elevated	15	39.47%
	Not elevated	22	57.89%
CA-125	Elevated	13	34.21%
	Not elevated	24	63.16%
$\beta$ -hCG	Elevated	2	5.263%
	Not elevated	35	92.11%
CEA	Elevated	2	5.263%
	Not elevated	35	92.11%
Inhibin A	Elevated	1	2.632%
	Not elevated	36	94.74%

### 3.4. The OSR and DFSR of the included patients

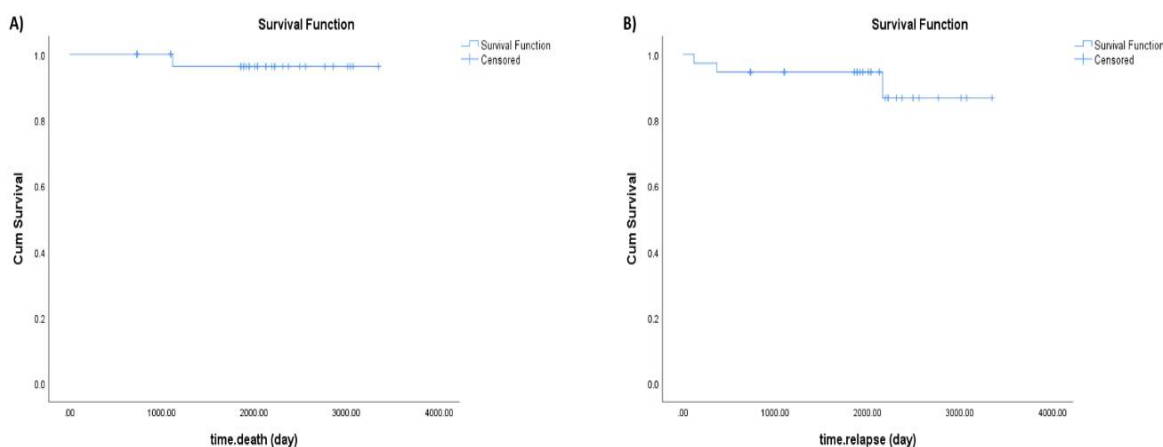
In the 10 years of included patients' follow-up, our results have shown that the OSR of patients with ovarian germ cell tumors is excellent (Fig. 2A). In our study, there was a case of death(2.7%) of a patient who came at the age of 29 with a complaint of abdominal pain and a report of an ovarian mass. Due to the desire to preserve fertility, she underwent conservative surgery. The final pathology was reported as mixed germ cell tumor (choriocarcinoma main component as well as foci of yolk sac tumor). The patient underwent adjuvant chemotherapy. 18 months later, the disease recurred in the lung, and she underwent chemotherapy, but the cure did not happen, and the patient expired 3 years after the initial diagnosis

Also, our results have indicated that tumor relapse is uncommon in patients with ovarian germ cell tumors (fig. 2B) Of the 37 patients followed, three cases(8.1%) of disease recurrence were reported. In the first case, a 16-year-old woman complained of abdominal pain and ovarian mass that underwent conservative surgery. The final pathology was mixed germ cell tumor (dysgerminoma 90% & embryonal carcinoma 10%) FIGO stage III

.. The patient relapsed 4 months after completing adjuvant chemotherapy.

The Second case, a 29-year-old woman complained of abdominal pain and ovarian mass and underwent conservative surgery, the final pathology was mixed germ cell tumor

(choriocarcinoma main component as well as foci of yolk sac tumor)FIGO Stage I a.recurrence was reported in this case 12 months after diagnosis. The third case was a 24-year-old woman who had undergone conservative surgery with complaints of abdominal swelling and pain. The final pathology was yolk sac tumor, FIGO Stage I a. Recurrence was reported in this patient 72 months after the initial diagnosis. All three patients underwent adjuvant chemotherapy after surgery.



**Figure 2-** The overall survival and tumor recurrence in patients with ovarian germ cell tumors. A) OS and B) DFSR

#### 4. Discussion

Ovarian germ cell tumors stem from primordial germ cells and are responsible for 20% of ovarian tumors. They are most commonly diagnosed in females younger than 30 years old (9). On average, our patients are diagnosed with these neoplasms around 24 years old. Although most cases of ovarian germ cell tumors are diagnosed in the second decade, there are several reported cases at older ages as well (10, 11). In our patients, the most commonly reported chief complaint was abdominal pain. In line with our findings, it has been indicated that abdominal pain and palpable mass are the most commonly documented complaint of affected patients (12). Our study has identified that none of the cases have bilateral ovary involvement. The current evidence also indicates that the majority of patients with ovarian germ cell tumors do not develop neoplasm bilaterally (5, 10). Overall, ovarian germ cell tumors can be the differential diagnosis of clinicians in young female patients presented with abdominal pain and a palpable mass.



Despite the potentially detrimental effect of chemotherapeutic agents on ovaries and future fertility, our results have shown that approximately 89% of patients did not need assisted reproductive technology for fertilization, and on average, their labor started at 39.29 weeks of gestation. 11(29.72%) of the 37 patients under investigation were not married and did not want to get pregnant, 14(37.83%) of them did not want to get pregnant due to the completion of the number of children. 12 (32.43%) cases tried to get pregnant that 9(75%) had a successful pregnancy without the intervention of assisted reproductive methods. 3(25%) cases needed assisted reproductive methods due to delay in fertility . Only 8.1% of all patients used fertility with assisted reproductive technologies.. Consistent with our results, over 85% of patients with ovarian germ cell cancers have physiological menstruation after treatment, and premature ovarian failure is less than 5% (15). In line with this, Satoshi et al. have reported that 42 out of 45 patients with ovarian germ cell cancers became pregnant (16). Seung-Chul et al. have also shown that adolescent and premenarchal patients with ovarian germ cell cancer treated with fertility-preserving surgery and adjuvant chemotherapy can have normal menstruation (17). Thus, the current treatment of ovarian germ cell tumors does not affect the fertilization of patients.

In our study, dysgerminoma was the most commonly diagnosed ovarian germ cell tumor (40.54% of all cases). In line with this, Smith et al. have reported that 35.6% of identified ovarian germ cell cancer is dysgerminoma (18). Lakshmanan et al. have also shown that dysgerminoma is the most commonly diagnosed ovarian germ cell tumor accounting for 37.1% of cases (19). Besides, Pauniaho et al. have indicated that dysgerminoma accounts for 31% of identified germ cell tumors; however, the most common one was teratoma (20). Regarding the post-operation complications and tumor relapse, our study has shown that the post-operation complications in our patients were negligible. More than 90% of our patients did not develop tumor relapse, Of the 37 patients followed, three cases(8.1%) of disease recurrence were reported. and the identified anatomical places for tumor recurrence were the lung, para-aorta, and cul-de-sac. 2 out 3 patients with recurrent tumors were treated with chemotherapy, and the other one was treated with chemotherapy and surgery. In the study by Lakshmanan et al., the recurrence was reported in approximately 20% of ovarian germ cell tumor patients, and most of them were treated with adjuvant chemotherapy (19). Pallavi et al. have reported tumor recurrence in 18.4% of patients with ovarian germ cell tumors (21). Similar results are reported in the study by Park et al. On a median follow-up of 93 months, 14.2% of ovarian germ cell tumor patients experienced tumor relapse, and most of them were

treated with bleomycin, etoposide, and cisplatin chemotherapy and surgery. The pelvic lymph node and peritoneum were the most commonly identified anatomical place for tumor recurrence (22). In this regard, Lee et al. have shown that the presence of residual tumors after salvage surgery is considerably associated with primary treatment failure in patients with ovarian germ cell tumors (23). Despite the relatively low recurrence of ovarian germ cell tumors, these tumors can relapse after a decade. Late tumor relapse has been reported after 15 years of diagnosis with ovarian germ cell tumor with metastasis to lung, liver, and retroperitoneal lymph nodes (24).

In terms of biomarkers, the most commonly elevated tumor markers are LDH, AFP, and CA-125, and inhibin A was the least commonly elevated tumor marker in our patients. Specific histological subtypes of ovarian germ cell tumors can not be differentiated based on tumor biomarkers; however, patients with embryonal carcinoma show increased levels of AFP, LDH, and  $\beta$ -hCG, and dysgerminoma patients can show increased levels of LDH and  $\beta$ -hCG (25). Based on the study by Singh et al., AFP is elevated in patients with yolk sac tumors (26). Also, these biomarkers can have prognostic values for affected patients (5). Salonen et al. have indicated that an increased level of CA-125 is considerably associated with poor prognosis of ovarian germ cell tumor patients (27). In line with this, Kim et al. have reported that the increased level of preoperative CA-125 is associated with decreased overall survival of ovarian germ cell tumor patients (28). In patients with yolk sac tumors, the decrease in AFP is also associated with improved overall survival (29). Therefore, increased tumor biomarkers might be suggestive of ovarian germ cell tumors, and their elevation can be associated with poor prognosis in affected patients. In our study, the mean follow-up period was 54 months. The prognosis of ovarian germ cell tumors patients is excellent even though the tumor becomes advanced (13). This promising prognosis is due to the development of platinum-based chemotherapy and the introduction of bleomycin, etoposide, and cisplatin regimen for these patients (5). In line with this, a recent systematic review has indicated that surgery with adjuvant chemotherapy is recommended for most patients with newly diagnosed ovarian germ cell tumors; however, neoadjuvant therapy might be beneficial for patients with advanced tumors in its initial presentation (14). Although none of our patients did not experience neoadjuvant chemotherapy, most of them were treated with chemotherapy after surgery. The current study has several strengths; it is the first study that comprehensively investigated the clinicopathological of ovarian germ cell tumors in the northwest region of Iran. However, it also suffers from several limitations, like the relatively short period of the

follow-up of patients. Overall, this study provides valuable data for clinicians, pathologists, epidemiologists, and policymakers regarding the clinicopathological and survival outcomes of ovarian germ cell tumors in the northeast of Iran.

## **5. Conclusion**

This descriptive study retrospectively investigated the clinicopathological and survival outcomes of ovarian germ cell tumor patients diagnosed between 2011 to 2022 in Tabriz. Based on this study, these tumors most commonly arise in young females and are unilateral. The adjuvant chemotherapy and surgery do not affect patients' fertility, and dysgerminoma was the most commonly diagnosed ovarian germ cell tumor. The tumor recurrence is rare and can be treated with chemotherapy and surgery.

## **Funding**

This research received no external funding.

## **Acknowledgments**

We appreciate the healthcare providers of Alzahra Hospital, a teaching and tertiary referral hospital affiliated with Tabriz University of Medical Sciences, Tabriz, Iran (grant number: 69912). This study was approved by the Ethics Committee of Tabriz University of Medical Sciences (IR.TBZMED.REC.1401.792).

## **Conflicts of Interest**

The authors declare no conflict of interest.

## **Reference**

1. Kurman RJ. Blaustein's pathology of the female genital tract: Springer Science & Business Media; 2013.
2. Parkinson CA, Hatcher HM, Ajithkumar TV. Management of malignant ovarian germ cell tumors. *Obstetrical & gynecological survey*. 2011;66(8):507-14.
3. Gică N, Peltecu G, Chirculescu R, Gică C, Stoicea MC, Serbanica AN, et al. Ovarian Germ Cell Tumors: Pictorial Essay. *Diagnostics*. 2022;12(9):2050.
4. Smith HO, Berwick M, Verschraegen CF, Wiggins C, Lansing L, Muller CY, et al. Incidence and survival rates for female malignant germ cell tumors. *Obstetrics & Gynecology*. 2006;107(5):1075-85.
5. Gershenson DM. Management of ovarian germ cell tumors. *Journal of Clinical Oncology*. 2007;25(20):2938-43.

6. Morrow D. National Academy of Clinical Biochemistry. National Academy of Clinical Biochemistry Laboratory Medicine Practice Guidelines: clinical characteristics and utilization of biochemical markers in acute coronary syndromes. *Circulation*. 2007;115:e356-e75.
7. Berek JS, Renz M, Kehoe S, Kumar L, Friedlander M. Cancer of the ovary, fallopian tube, and peritoneum: 2021 update. *International journal of gynaecology and obstetrics: the official organ of the International Federation of Gynaecology and Obstetrics*. 2021;155 Suppl 1(Suppl 1):61-85.
8. Díaz-Murillo R, Lombarte-García M, de Santiago J, Zapardiel I. MALIGNANT OVARIAN GERM CELL TUMORS: TREATMENT AND PROGNOSIS. *HANDBOOK ON OVARIAN CANCER*.89.
9. Kaur B. Pathology of malignant ovarian germ cell tumours. *Diagnostic Histopathology*. 2020;26(6):289-97.
10. Tangjitgamol S, Hanprasertpong J, Manusrivithaya S, Wootipoom V, Thavaramara T, Buhachat R. Malignant ovarian germ cell tumors: clinico- pathological presentation and survival outcomes. *Acta obstetrica et gynecologica scandinavica*. 2010;89(2):182-9.
11. Patterson DM, Murugaesu N, Holden L, Seckl MJ, Rustin GJ. A review of the close surveillance policy for stage I female germ cell tumors of the ovary and other sites. *International journal of gynecological cancer : official journal of the International Gynecological Cancer Society*. 2008;18(1):43-50.
12. Low JJH, Ilancheran A, Ng JS. Malignant ovarian germ-cell tumours. *Best Practice & Research Clinical Obstetrics & Gynaecology*. 2012;26(3):347-55.
13. Solheim O, Gershenson DM, Tropé CG, Rökkones E, Sun CC, Weedon-Fekjaer H, et al. Prognostic factors in malignant ovarian germ cell tumours (The Surveillance, Epidemiology and End Results experience 1978-2010). *Eur J Cancer*. 2014;50(11):1942-50.
14. Simone CG, Markham MJ, Dizon DS. Chemotherapy in ovarian germ cell tumors: A systematic review. *Gynecologic oncology*. 2016;141(3):602-7.
15. Vasta FM, Dellino M, Bergamini A, Gargano G, Paradiso A, Loizzi V, et al. Reproductive Outcomes and Fertility Preservation Strategies in Women with Malignant Ovarian Germ Cell Tumors after Fertility Sparing Surgery. *Biomedicines*. 2020;8(12).
16. Tamauchi S, Kajiyama H, Yoshihara M, Ikeda Y, Yoshikawa N, Nishino K, et al. Reproductive outcomes of 105 malignant ovarian germ cell tumor survivors: a multicenter study. *American Journal of Obstetrics and Gynecology*. 2018;219(4):385. e1-. e7.
17. Yoo S-C, Kim WY, Yoon J-H, Chang S-J, Chang K-H, Ryu H-S. Young girls with malignant ovarian germ cell tumors can undergo normal menarche and menstruation after fertility-preserving surgery and adjuvant chemotherapy. *Acta obstetrica et gynecologica scandinavica*. 2010;89(1):126-30.
18. Smith HO, Berwick M, Verschraegen CF, Wiggins C, Lansing L, Muller CY, et al. Incidence and survival rates for female malignant germ cell tumors. *Obstetrics and gynecology*. 2006;107(5):1075-85.
19. Lakshmanan M, Gupta S, Kumar V, Akhtar N, Chaturvedi A, Misra S, et al. Germ Cell Tumor Ovary: an Institutional Experience of Treatment and Survival Outcomes. *Indian journal of surgical oncology*. 2018;9(2):215-9.
20. Pauniah SL, Salonen J, Helminen M, Vettenranta K, Heikinheimo M, Heikinheimo O. The incidences of malignant gonadal and extragonadal germ cell tumors in males and females: a population-based study covering over 40 years in Finland. *Cancer causes & control : CCC*. 2012;23(12):1921-7.
21. Pallavi VR, Kansal Y, Rathod PS, Shobha K, Kundargi R, Bafna UD, et al. Impact of Optimal Therapy and Prognostic Factors in Malignant Germ Cell Tumors of Ovary: 20 Years' Institutional Experience. *Indian journal of surgical oncology*. 2022;13(3):633-40.
22. Park JY, Kim DY, Suh DS, Kim JH, Kim YM, Kim YT, et al. Outcomes of pediatric and adolescent girls with malignant ovarian germ cell tumors. *Gynecologic oncology*. 2015;137(3):418-22.
23. Lee CW, Song MJ, Park ST, Ki EY, Lee SJ, Lee KH, et al. Residual tumor after the salvage surgery is the major risk factors for primary treatment failure in malignant ovarian germ cell tumors: a retrospective study of single institution. *World journal of surgical oncology*. 2011;9:123.
24. Khan O, Winquist E, Ettler H, Power N. Late Relapse of Ovarian Germ Cell Tumour. *Journal of obstetrics and gynaecology Canada : JOGC = Journal d'obstetrique et gynecologie du Canada : JOGC*. 2018;40(10):1329-32.
25. Brown J, Friedlander M, Backes FJ, Harter P, O'Connor DM, de la Motte Rouge T, et al. Gynecologic Cancer Intergroup (GCIg) consensus review for ovarian germ cell tumors. *International journal of gynecological cancer : official journal of the International Gynecological Cancer Society*. 2014;24(9 Suppl 3):S48-54.
26. Singh P, Singh D, Anant M, Agrawal M, Sinha R. Clinical Characteristics and Treatment Outcomes of Patients with Ovarian Germ Cell Tumor Treated at a Tertiary Care Center in Patna, India. *Indian Journal of Gynecologic Oncology*. 2020;18:1-8.
27. Salonen J, Leminen A, Stenman UH, Butzow R, Heikinheimo M, Heikinheimo O. Tissue AP-2gamma and Oct-3/4, and serum CA 125 as diagnostic and prognostic markers of malignant ovarian germ cell tumors.

Tumour biology : the journal of the International Society for Oncodevelopmental Biology and Medicine. 2008;29(1):50-6.

28. Kim J-H, Park J-Y, Kim J-H, Kim Y-M, Kim Y-T, Nam J-H. The role of preoperative serum cancer antigen 125 in malignant ovarian germ cell tumors. Taiwanese Journal of Obstetrics and Gynecology. 2018;57(2):236-40.

29. Rouge TdLM, Pautier P, Rey A, Duvillard P, Kerbrat P, Troalen F, et al. Prognostic factors in women treated for ovarian yolk sac tumour: a retrospective analysis of 84 cases. European Journal of Cancer. 2011;47(2):175-82.