



INDIVIDUALIZED CONSTITUTIONAL HOMEOPATHIC MANAGEMENT OF WART: A CASE STUDY

Dr. Poonam Ganesh Kakandikar^{1*}

Abstract: Warts are benign tumors caused by DNA Human Papilloma Virus. Treatment must be started as soon as possible as the patient may suffer from cosmetic disfigurement with pain & remains as a potent source of transmission to others. Treatment requires various oils and ointment costing heavily to patient and sometimes even needs cauterization. Homoeopathic drugs on the other hands are cost effective, safe & with no side effects. Old female patient with 78 years of age was treated for multiple warts, one large below left nostril treated with Nitric Acid 30c followed by 200c. The paper represents systematic investigations and treatment for curing warts. The results indicate that, single medicine has effective role in treatment of wart with priority to the general symptom of patient, by considering the holistic approach towards patient.

Key words: Wart, Filiform Wart, Individualized Homeopathic Remedy, Nitric Acid

^{1*} Assistant Professor, Organon of Medicine Department, Bharati Vidyapeeth Homeopathic Medical College & Research Centre, Pune. poonam.kakandikar@bharativedyapeeth.edu

***Corresponding author:** -Dr. Poonam Ganesh Kakandikar

* Assistant Professor, Organon of Medicine Department, Bharati Vidyapeeth Homeopathic Medical College & Research Centre, Pune poonam.kakandikar@bharativedyapeeth.edu

DOI: 10.53555/ecb/2024.13.04.03

Introduction:

warts are benign proliferation of skin & mucosa caused by human Papilloma virus (HPV). Currently more than 100 types of HPV have been identified. Certain HPV types tend to infect at particular anatomic sites, however warts of any HPV type may occur at any site. Primary clinical manifestation of HPV infection includes common warts, genital warts, flat warts. Less common manifestation of HPV infection includes focal epithelial hyperplasia. The diagnosis is based on clinical manifestation & usually straight forward by visual inspection, cosmetic embarrassment & risk of malignancy. Though sometimes it is a self-limiting disease but on average it takes about 01-02 years of resolution during which affected person suffers from cosmetic disfigurement, thus it is essential to get rid of disease as soon as possible. The detailed case report of female patient, strategy of treatment, medicines prescribed and achieved results are presented in coming sections.

Case Report: A 78-year-old female vegetarian, retired as clerk by profession, belonging to middle

socioeconomic family residing in urban area visited to our OPD on 21st June 2022 at Bharati Vidyapeeth Homoeopathic Medical College Pune with complaints of multiple warts one large below left nostril, various small behind left ear and some flat warts at abdomen and at back for four months. Patient has noticed that wart below left nostril started increasing day by day and raised to 07mm diameter. Patient was suffering from H.T. and lumbar spondylosis and was on Ayurvedic treatment.

Associated Complaints: Tearing pain in lower limbs, slight exertion causes weakness.

History of Present Complaints: Patient was under ayurvedic treatment for H.T. and Lumbar spondylosis. Suddenly patient noticed that warts are rising behind left ear, at abdomen and at back, one large wart increasing rapidly below left nostril. No any causation identified.

Treatment History: Ayurvedic treatment for H.T. and Spondylosis.

Table 1: Holistic Approach Towards Patient:

Appetite	03 Meals/day, 01-02 Chapati, Satisfactory
Thirst	Normal temperature 2.0 - 2.5 liters per day in every season.
Desire	Fat
Stool	Great straining sometimes
Mouth	Putrid breath, salivation ++
Urine	Profuse urination, burning, pricking, stinging pain sometimes
Genitals	External parts sore, vaginal itching
Skin	Rough, dark, multiple small warts behind ears, one large below left nostril
Constitution	Lean, thin, dark complexion
Past History	k/c/o H.T. and Lumbar spondylosis since 7 yrs.
Family History	NA
Mental Generals	Anxiety about health++, Irritability++ when crossed, restlessness, indifference++, cursing when get disappointed with others
General Examination:	
Built	Lean and thin, dark complexion
Height	148cm
Weight	49 kg
Blood Pressure	140/90 mm Hg
Provisional Diagnosis	Filiform and flat warts on physical examination.

Table 2: Case Evaluation

1. Mentals			
	Evaluation	Common/Uncommon	Miasmatic Analysis
Indifference	3+	Uncommon	Tubercular
Irritability	2+	Uncommon	Sycopsoric
Restlessness Night	3+	Uncommon	Sycosis
Cursing	3+	Uncommon	Syphilosycosis
Anxiety about Heart	3+	Uncommon	Psora

2. Physical Genera			
Desire Fat	2+	Uncommon	Psoratubercular
Constipation	2+	Uncommon	Psora
Putrid Breath	3+	Uncommon	Syphilis
Salivation	2+	Uncommon	Psorasycotic
3. Particulars			
Warts on face	3+	Common	Sycosis
Pain in lower limbs aggravated at night	2+	Common	Syphilotubercular
Soreness at genitals	2+	Uncommon	Syphilis
Vaginal itching	2+	Uncommon	Psora

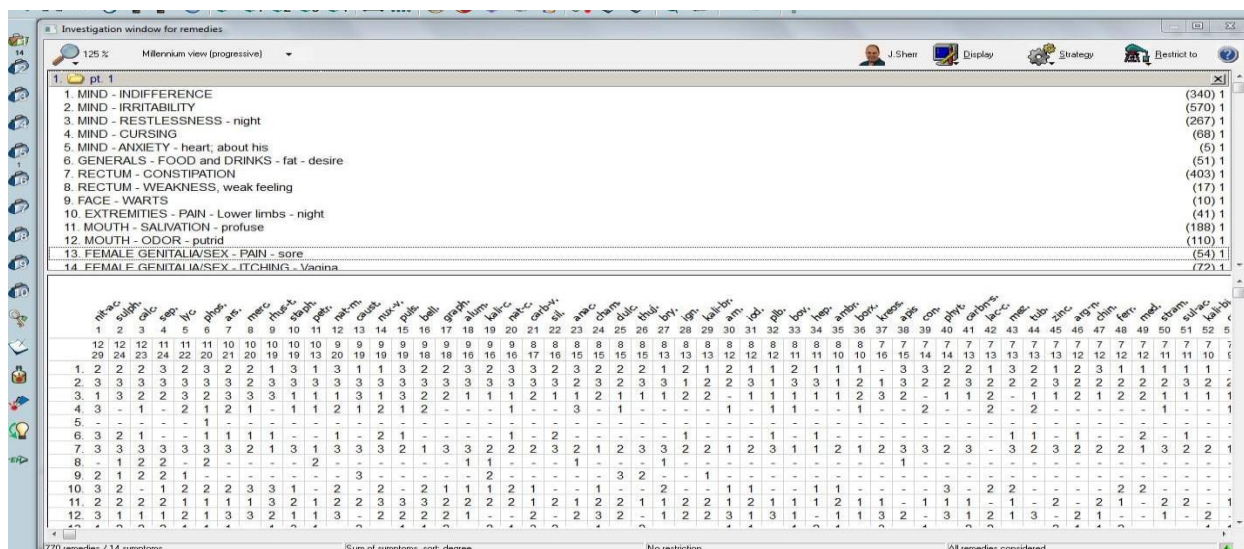


Fig 1. Repertorisation by Radar Synthesis

9.0 Predominant Miasm: Psorasycosis

Repertorisation: As generals were marked along with particulars, the case is repertories with the help of Synthesis repertory version 9.0 (Figure)

Selection of Remedy: Nitric acid was selected on the basis of Repertorisation by considering the symptom similarity.

Selection of Potency: Nitric acid 30 two doses at start

Justification of repetition of doses: It has been done when required according to the principle.

Methodology followed for Treatment Plan, Selection of Medicine, Potency, Doses, and

Repetition: The patient has to go for 11 follow ups after initial diagnosis from June 2022 to December 2022. Patient was prescribed with only one medicine Nitric acid. According to

Repertorisation Sulphur and Calcarea with few others were suggested. Based on case similarity (Aph 26 & Aph 147) and on the basis of constitution of patient, Nitric acid was selected. Repetition of doses were given (Aph 245-251) as per the guideline of our master Dr. Samuel Hahnemann. The initial dose was started with 30c potency. After 02 months of observation the potency was increased to 200c for better results. Placebo was given as supplementary medicine. There was no appearance of new wart and old warts got completely vanished. General management advised was:

1. Do not touch the wart.
2. Don't try to pluck it.
3. Don't Apply any ointment.

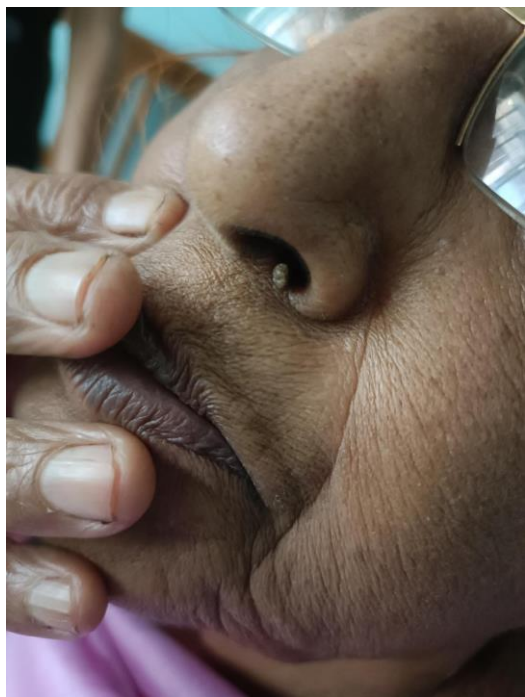

Fig 2. At the time of clinical diagnosis.

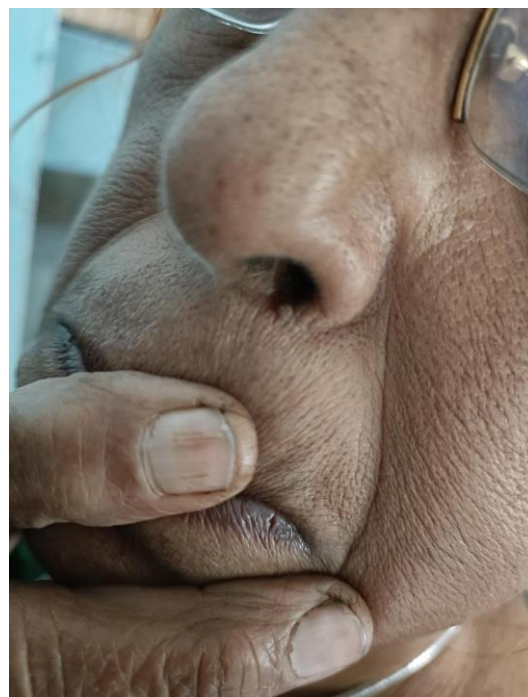


Fig 3. Improvement after two months

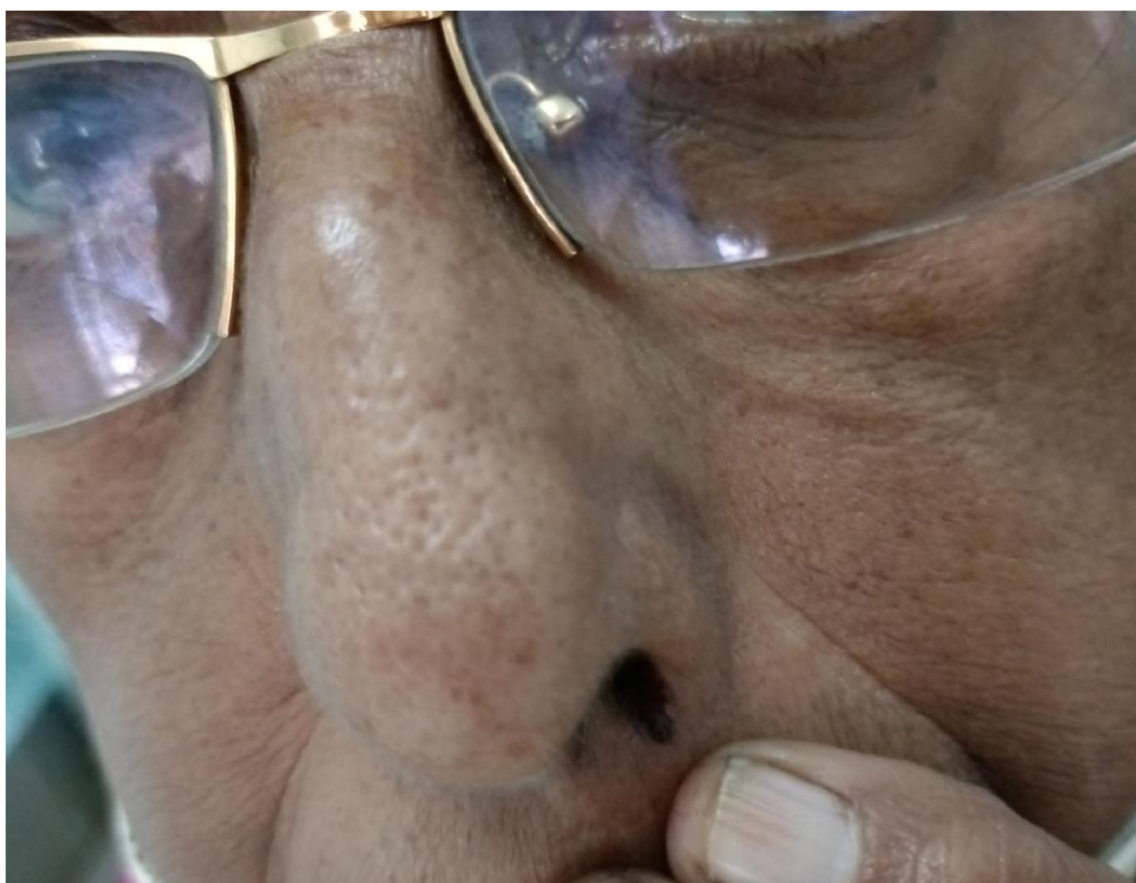


Fig 4. Wart completely vanished after 6 months

The details of follow-ups, with symptoms-based prescriptions and justification for treatment has been discussed in details in following table. The evidence-based photography of patient is shown below.

Table 3: Details of Patients Follow ups and Treatment Given

Sr. No.	Date	Symptom	Prescription	Justification
01	21/06/22	One large filiform wart 0.7cm at left nostril with flat warts behind left ear and abdomen and back	Nitric acid 30 2 powders	First prescription according to totality of symptoms
02	06/07/22	No apparent changes in Leisons	Placebo 30 thrice in a day for 15 days	By considering the action of remedy, only Placebo is given for 15 days
03	22/07/22	Leisons seems to be dried up slightly, lower limb pains, constipation and putrid breath as it is.	Placebo 30 three times a day given	Improvement started so Placebo is given for 15 days
04	07/08/22	Leisons seems to be dried up, lower limb pain relived 50%, putrid breath and constipation as it is.	Placebo 30 three times in a day for 15 days	Improvement started so Placebo is given for 15 days
05	23/08/22	Stand still condition, no improvement	Nitric acid 200c 2 powders given twice in a day followed by Placebo 30	As improvement is on hold same medicine in higher potency is given
06	08/09/22	Leisons started to decrease in size, putrid breath relieved, constipation and extremity pain also relieved.	Placebo 30c thrice in a day for 15 days	As we see improvement placebo is given
07	23/09/23	Leisons started to decrease in size, some small flat warts disappeared	Placebo 30 given thrice in a day for 15 days	Improvement is seen, Placebo is given
08	09/10/22	Leisons started to dried up, small warts started to disappear from region of abdomen and back	Placebo 30 given thrice in a day	Improvement is seen , Placebo is given
09	24/10/22	Wart near nostril becomes very small in size and dried, no new complaints	Placebo 30 thrice in a day for 15 days	Improvement with no new complaints so Placebo is given
10	09/11/22	Wart dried up and became very small in size, no new complaints	Placebo 30 thrice in a day for 15 days	Improvement with no new complaints, Placebo is given
11	24/11/22	Very tiny in size, dried up, no new complaints	Placebo 30 thrice in a day for 15 days	Improvement with no new complaints so Placebo is given
12	09/12/22	Completely disappearance of wart near nostril, no new complaints	No need of medicine	No need of medicine

Conclusion: It can be concluded that individualized potentized homeopathic medicine on the basis of constitutional selection will bring the result in short duration period with complete resolution of complaints without any side effect.

Limitation of Study: As a single case report cannot be conclusive for effectiveness of constitutional individualized homeopathic remedy.

There is a need of more case studies for Constitutional individualized homeopathic medicines.

Patient's consent for publication: the written consent has been obtained from the patient for publication of images but identity of patient has not disclosed.

Conflict of Interest: Author declares that there is no conflict of interest.

REFERENCES:

1. Warts: Overview [Internet]. Cologne, Germany: Institute for Quality and Efficiency in Health Care; 2019 [cited 11 November 2020].
2. Sekhar Namburi U, Babu G, Omprakash. A review on management of warts in Ayurveda. *AYU (An International Quarterly Journal of Research in Ayurveda)* 2011;32(1):100.
3. Khanna N. Illustrated synopsis of dermatology & sexually transmitted diseases. 5th ed. Reed Elsevier Pvt. Ltd, New Delhi. 2016. P-29.
4. Hahnemann S. The Chronic Diseases: Their peculiar nature and their homoeopathic cure sed. B Jain Publishers (p) Ltd, New Delhi. 1995. P-239.
5. Roberts H. The principles and art of cure by homoeopathy. B Jain Publishers (P) LTD; Reprint 2004. Pp 236.
6. Banerjee S. Miasmatic diagnosis. New Delhi: B. Jain; 4th ed. 2011. Pp 175.
7. Rapid Aid to Drug Aided Research 10.0.28 software version, RADAR repertory Programme; 2007.
8. Kent, James Tyler. Lectures on Materia Medica. Delhi, India: B. Jain Publishers, 2004. Pp 398.
9. Boericke, W. Boericke's New Manual of Homeopathic Materia Medica with Repertory. 9th ed. B. Jain Publishers (P) LTD. New Delhi. 41st imprint 2018. Pp 161, 565.
10. Sarkar BK, Majumdar JN, Dudgeon RE. Organon of Medicine by Samuel Hahnemann. Reprint edition. Birla Publications PVT. LTD; Delhi. 2006-2007. Pp 163, 254-255.
11. Close S. The genius of homoeopathy lectures and essays on homoeopathic philosophy Reprint ed. B Jain Publisher (P) Ltd 2008. Delhi. Pp 183, 190.
12. Kent JT: Lectures on Homoeopathic Philosophy. 5th ed. Reprint, B Jain Publishers (P) Ltd., 1989. Pp 67.
13. Biswas B, Roy PS, Mandal S, Roy P. Four cases of warts treated by individualized homoeopathic medicine - a clinical case study. *J Intgr Stand Homoeopathy* 2022; 5:9-18.
14. Shaikh MI. Case studies for treatment of warts with Homoeopathy. *Indian J Res Homoeopathy* 2016;10:272-8.
15. Khanna N. Illustrated Synopsis of Dermatology and Sexually Transmitted Diseases (4th ed). Amsterdam, Netherlands: Elsevier; 2011.
16. Joseph R, Pulimood SA, Abraham P, John GT. Successful treatment of verruca vulgaris with Thuja occidentalis in a renal allograft recipient. *Indian J Nephrol.* 2013;23:362-4.
17. Mahajan N, Mahajan A, Bhinda A, Salodiya S. Homoeopathic treatment of viral warts with calcarea phosphorica. *Indian J Res Homoeopathy.* 2020;14:279-86.
18. Kainz, J. T., Kozel, G., Haidvogel, M., & Smolle, J. (1996). Homoeopathic versus placebo therapy of children with warts on the hands: a randomized, doubleblind clinical trial. *Dermatology*, 193(4), 318-320.
19. Gupta, R., Bhardwaj, O. P., & Manchanda, R. K. (1991). Homoeopathy in the Treatment of Warts. *British Homeopathic Journal*, 80(02), 108-111.