



## ASSESSMENT OF LOWER INCISOR PROCLINATION IN CLASS 2 MALOCCLUSION PATIENTS UNDERGOING TWIN BLOCK APPLIANCE THERAPY AND ITS ASSOCIATION WITH OTHER FACTORS

Gajapriya M<sup>1</sup>, Remmiya Mary Varghese<sup>2\*</sup>

**Article History:** Received: 12.12.2022

Revised: 29.01.2023

Accepted: 15.03.2023

### Abstract:

**Aim:** To assess the lower incisors proclination in class 2 malocclusion patients undergoing functional appliance therapy and its associative factors

**Background:** Class II malocclusion occurs when the lower dental arch is more posterior than the upper dental arch. Currently there are many treatment approaches available in orthodontics for class II malocclusion which includes extraoral traction appliance, functional jaw orthopaedic appliance, arch expansion mechanism, extraction procedures and surgical procedures. The class II malocclusion includes altered molar relationship from class I normal molar relationship, proclination of anterior teeth of upper and lower arch either it involves only upper arch proclination or bimaxillary proclination, skeletal modifications like prognathic maxillary bone or retrognathic mandibular bone. The results of different treatment approaches are varying for different patients according to various factors but the ultimate aim of all treatment approaches is to bring confident smiles.

**Materials and Methods:** The class 2 malocclusion patient undergoing functional appliance therapy in Saveetha dental hospital were included in the study and their pre operative and post operative cephalometric radiographs were collected for the assessment of lower incisors proclination which has to be correlated with various associative factors like age, sex, years of treatment undergone.

**Results:** Mean age of the study sample was  $11.12 \pm 1.56$  years. Mean reduction of lower incisors proclination with twin block appliance was statistically significant ( $p < 0.005$ ). There was no statistically significant difference between males and females in lower incisors with twin block appliance

**Conclusions:** The twin block appliance treatment are statistically significant reduction lower incisor proclination of class 2 malocclusion patients. There was no statistically significant difference between males and females in lower incisors with twin block appliance

**Keywords:** class 2 malocclusion; functional appliance; incisor proclination.

<sup>1</sup>Saveetha Dental College and hospitals, Saveetha Institute of Medical and Technical Sciences (SIMATS) Saveetha University, Chennai-600077, Tamil Nadu, India.

<sup>2</sup>Reader, Department of orthodontics, Saveetha Dental College and hospitals Saveetha Institute of Medical and Technical Sciences (SIMATS) Saveetha University, Chennai-600077, Tamil Nadu, India.

**DOI:** 10.31838/ecb/2023.12.s2.048

## **1. Introduction:**

Class II malocclusion occurs when the lower dental arch is more posterior than the upper dental arch. Currently there are many treatment approaches available in orthodontics for class II malocclusion which includes extraoral traction appliance, functional jaw orthopedic appliance, arch expansion mechanism, extraction procedures and surgical procedures(1). The class II malocclusion includes altered molar relationship from class I normal molar relationship, proclination of anterior teeth of upper and lower arch either it involves only upper arch proclination or bimaxillary proclination(2), skeletal modifications like prognathic maxillary bone or retrognathic mandibular bone. The extraoral soft tissue findings of this malocclusion such as the hyperactive mentalis muscle and the steep upper incisor position with high lip line as the lower lip covering the upper incisors(3).

Incisor angulations play a major role in treating a malocclusion during orthodontic treatment. Main feature of Class II malocclusion which is going to be corrected by upper arch extraction treatment is due to the insufficient palatal root torque of the upper incisors and proclination of the lower incisors(4). Treating the upper and lower incisor proclination are not always achievable which is required for the attainment of ideal overjet, overbite, and buccal segment relationships. Insufficient overjet and overbite relationship for any magnitude of upper incisors angulation results from the excessive proclination of the lower incisor(5). In presurgical orthodontics, adequate advancement of the mandible is impaired due to excessive proclination of lower incisors. Lower incisors which are excessively proclined have the potential to play a major role to an occlusion correction with minimal or no overjet and overbite(6).

The term functional appliance refers to one of the different types of orthodontic appliances designed to activate a change in the various muscles of the face which stimulates the position and function of the mandible in order to pass the forces to the teeth and the basal bone of the teeth(7). Functional appliances have played an important role in orthodontic treatment, which has been used to treat different types of malocclusions which also have some skeletal malformations(8). Limited but well-defined place in orthodontic treatment is performed by functional orthopedic appliance therapy(9). According to the type and character of the malocclusion used to find the indications and contraindications of the functional appliance in

treatment plan(10). While comparing the treatment of choice for class 2 malocclusion the functional appliance alone treatment was not upto the level of functional appliance with temporary anchorage device which helps in reducing the proclination of the lower incisors in the short term(11).

Pre operative and post operative radiographs were used to analyze the changes occurred in the ANB angle and were used to find out the skeletal response to orthodontics treatment(12). Here in this study the pre operative and post operative cephalometric radiographs were used to evaluate the lower incisor proclination changes in the class 2 patients undergoing functional appliance therapy.

Our team has extensive knowledge and research experience that has translated into high quality publications (13–22).(14,16,18,22–25)

## **2. Materials and Methods:**

The outpatients of Saveetha dental college and hospital who all are reported with class 2 malocclusion undergone functional appliance therapy for correction of malocclusion were selected for the study based on inclusion and exclusion criteria from the department of orthodontics in Saveetha dental college and hospital.

Pre and post treatment cephalometric radiographs of the class 2 patient undergoing functional appliance therapy were collected. The collected radiographs were traced and some measurements were taken in order to assess the amount of lower incisor proclination correction with functional appliance therapy.

## **3. Results:**

There was more of the male population(71.43%) than female(28.57%) in this study as shown in bar graph(figure 1). In (figure 2) the patients were aged between 12-14 years old in which 42.86% were 12 years old, 28.57% were 13 years old and 28.57% were 14 years old . In (figure 3) the maximum duration of treatment patients underwent was 7 months (14.29%) and minimum treatment underwent by patients was 3 months(28.51%). In (figure 4) the type of the treatment most of the patients underwent the twin block appliance therapy(57.14%) for class 2 malocclusion. In (figure 5) the pretreatment lateral cephalometric record shows the highest value of measurement of lateral incisors proclination was 100-100.99° (28.57%) .

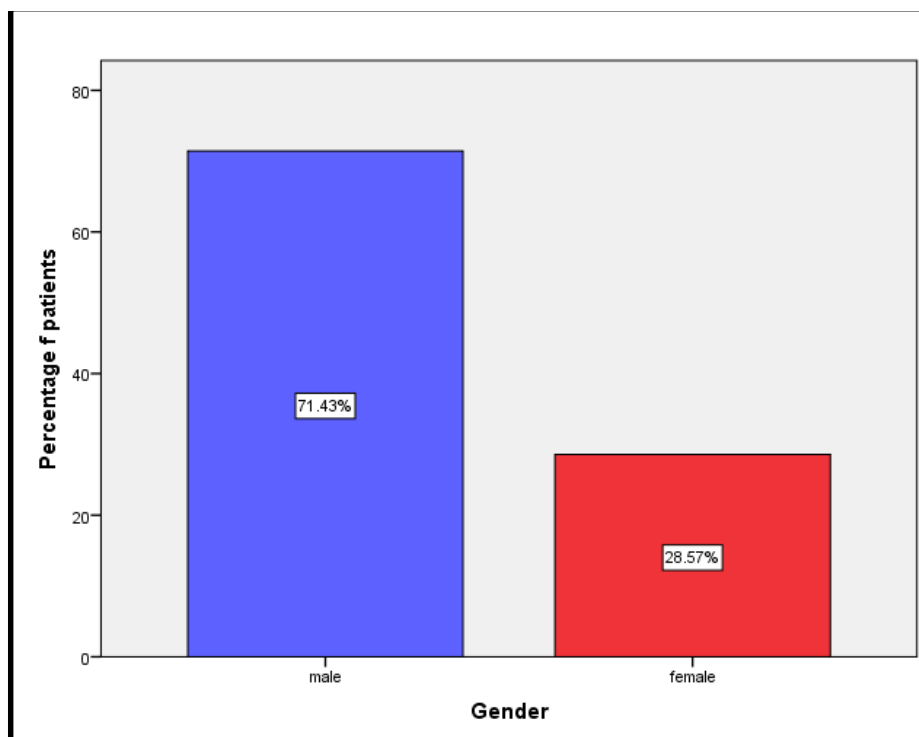


Figure 1: The bar graph depicted the frequency distribution of gender of patients. According to the chart 28.57% of the participants were female and 71.43% of the participants were male.

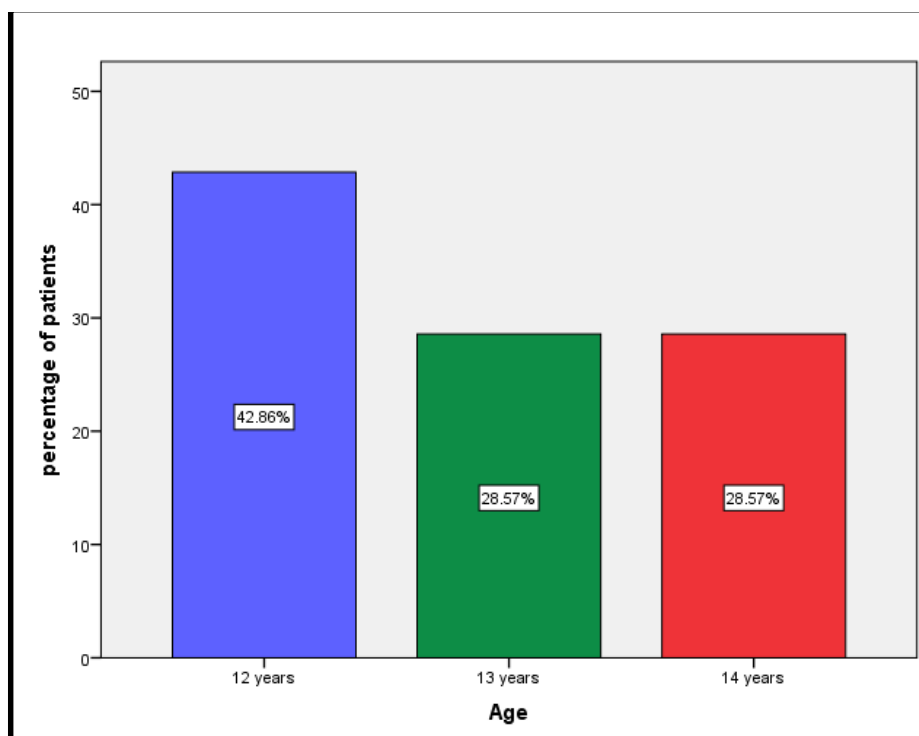


Figure 2: The bar graph depicted the frequency distribution of age of patients. According to the chart 42.86% of the patients were 12 years, 28.57% of the patients were 13 years and 28.57% of the patients were

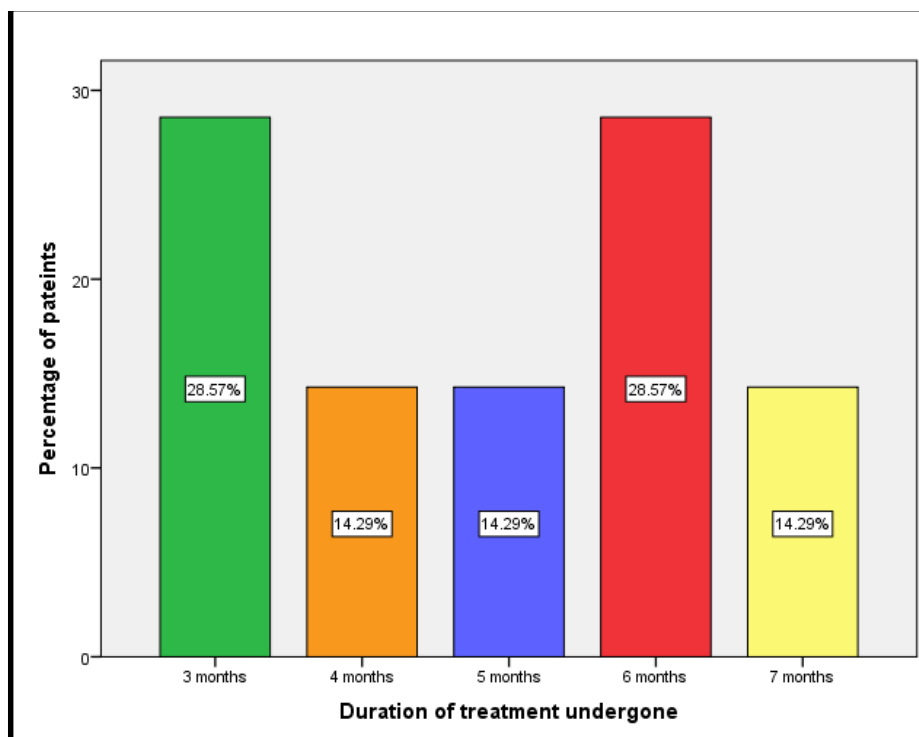


Figure 3: The bar graph depicted the frequency distribution of duration of the treatment the Patients underwent. According to the chart 28.57% of the patients underwent 3 months, 14.29% of the patients underwent 4 months, 14.29% of the patients underwent 5 months, 28.57% of the patients underwent 6 months and 14.29% of the patients underwent 7 months.

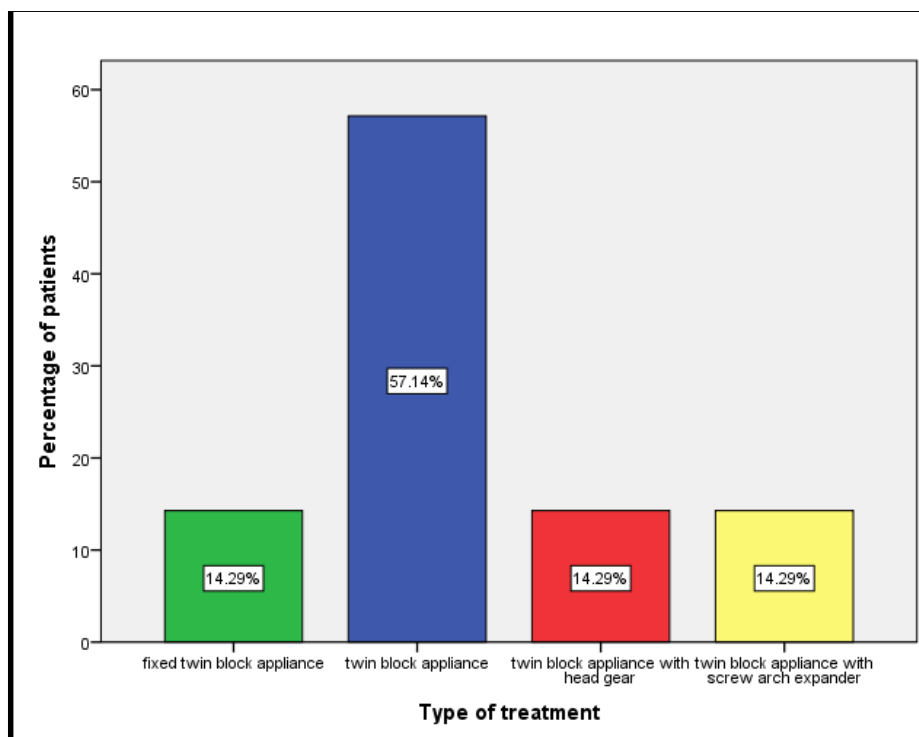


Figure 4: The bar graph depicted the frequency distribution of the type of the treatment the Patients underwent. According to the chart 14.29% of the patients underwent fixed twin block appliance, 57.14% of the patients underwent twin block appliance, 14.29% of the patients underwent twin block appliance with headgear, 14.29% of the patients underwent twin block appliance with screw arch expander.

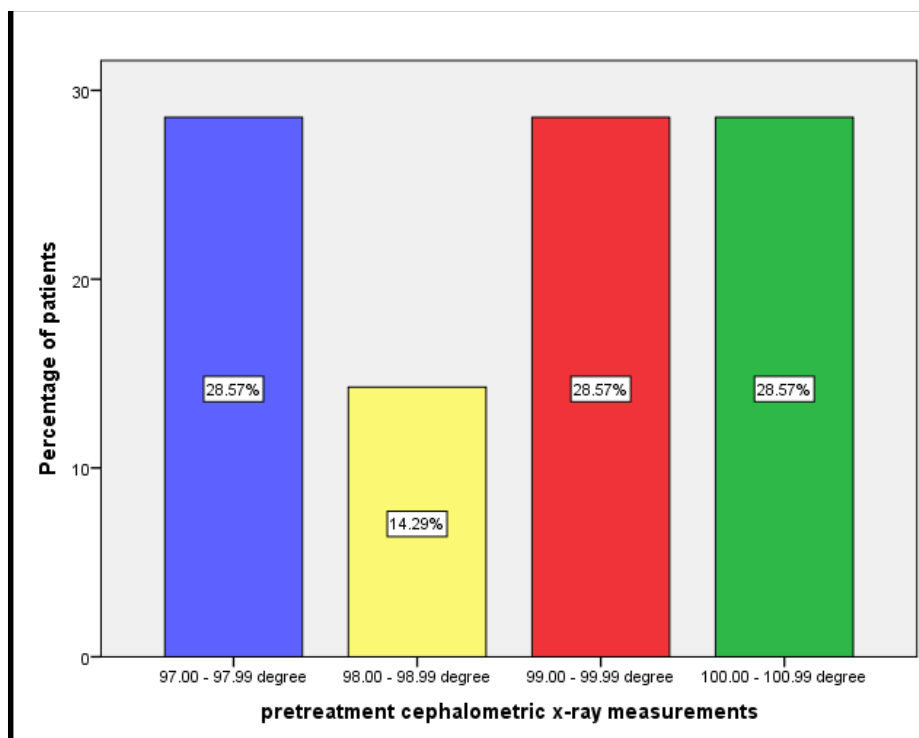


Figure 5: The bar graph depicted the frequency distribution of pre-treatment cephalometric X-ray measurement of lower incisors proclination of the Patients. According to the chart 28.57% of the patients has between 97- 97.99° of lower incisors proclination , 14.29% of the patients has between 98-98.99° of lower incisors proclination, 28.57% of the patients has between 99-99.99° of lower incisors proclination , 28.57% of the patients has between 100- 100.99° of lower incisors proclination

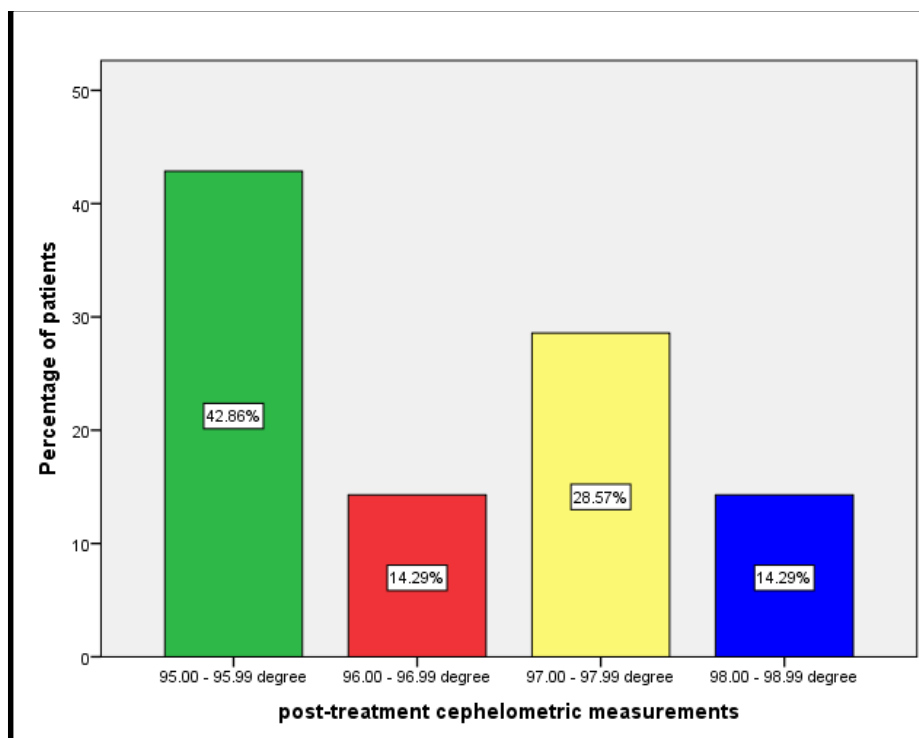


Figure 6: The bar graph depicted the frequency distribution of post-treatment cephalometric X-ray measurement of lower incisors proclination of the Patients. According to the chart 42.86% of the patients has between 95-

95.99° of lower incisors proclination, 14.29% of the patients has between 96-96.99° of lower incisors proclination, 28.57% of the patients has between 97-97.99° of lower incisors proclination, 14.29% of the patients has between 98-98.99° of lower incisors proclination which is reduced than pretreatment measurements.

#### 4. Discussion:

In a study the functional appliances show clinically important treatment modalities that have lasting effects on growth of the mandible and for the treatment of Class II malocclusion which include the proclination of incisors and molar relationship also and the reduction of an increased overjet (26). In a study accurate diagnosis of the lower incisor by evaluating its proclination, is deferred due to its structures which influence and also affect its measurements (27).

In a study shows 6.6° of proclination of lower incisors and by Asad shows 7.7° of proclination of lower incisors which is very higher than the duty which is based on the reference planes used in the present study, had an average proclination of the lower incisor is 4.8°. Therefore, there are some variations in the values that are obtained for each plane (28). In a study the lowest and highest proclination, respectively ( $1.2^\circ \pm 7$  y  $8^\circ \pm 6$ ) were given by McHarris and FMIA angles. From this we can understand that there is an altered incisor measurement that can depend on the reference plane used in the studies (29). A study shows that there is a low correlation between the other planes and FMIA and its large difference is measured with other groups because of the fact that the measurement may also be affected by the position and rotation of the mandible itself (30).

In a study they have reported that the orthodontic treatment has been used as a noncompliance appliance that causes an important treatment correction of the sagittal discrepancies. This correction is related to different output of the treatment as glenoid fossa remodeling, mandibular growth increasing and also the lower incisor proclination (31). In a study, using a tooth inclination protractor the lower incisor proclination is constantly shown as over scored by 2.57 degree. In a study by Marsico et al. because of the lesser level of compliance of the patients so in that study they decided to use the twin block which is a removable or fixed appliance that could have shown better results in the lower incisor proclination (32).

In a study the twin block appliance could be treated only with Class II intermaxillary traction fixed appliances, nevertheless, the disadvantages with this treatment modalities are that it may lead to proclination of the lower incisors and molar correction so the Class I occlusion could be difficult

to achieve. But in this study the reduction in proclination of lower incisors is achieved by twin block appliances used with fixed appliances (33). In a study dentoskeletal changes were compared with Forsus fatigue resistant device and powerscope class II corrector they concluded that the Powerscope group had a higher amount of lower incisor proclination in comparison to the Forsus group (34).

#### 5. Conclusion:

The pre and post operative record of patients shows significant reduction in the lower incisors proclination of class 2 malocclusion patients undergone twin block appliance therapy for different durations. There is no statistical significant difference between and male and female patients.

#### 6. Reference:

- Ehsani S, Nebbe B, Normando D, Lagravere MO, Flores-Mir C. Short-term treatment effects produced by the Twin-block appliance: a systematic review and meta-analysis. *Eur J Orthod.* 2015 Apr;37(2):170–6.
- Baysal A, Uysal T. Soft tissue effects of Twin Block and Herbst appliances in patients with Class II division 1 mandibular retrognathia. *Eur J Orthod.* 2013 Feb;35(1):71–81.
- Zhang C, He H, Ngan P. Effects of twin block appliance on obstructive sleep apnea in children: a preliminary study. *Sleep Breath.* 2013 Dec;17(4):1309–14.
- O'Brien K, Wright J, Conboy F, Appelbe P, Davies L, Connolly I, et al. Early treatment for Class II Division 1 malocclusion with the Twin-block appliance: a multi-center, randomized, controlled trial. *Am J Orthod Dentofacial Orthop.* 2009 May;135(5):573–9.
- Dyer FM, McKeown HF, Sandler PJ. The modified twin block appliance in the treatment of Class II division 2 malocclusions. *J Orthod.* 2001 Dec;28(4):271–80.
- Sidlauskas A. The effects of the Twin-block appliance treatment on the skeletal and dentoalveolar changes in Class II Division 1 malocclusion. *Medicina.* 2005;41(5):392–400.
- Sharma AK, Sachdev V, Singla A, Kirtaniya BC. Skeletal and dentoalveolar changes concurrent to use of Twin Block appliance in class II division I cases with a deficient mandible: a cephalometric study. *J Indian Soc Pedod Prev Dent.* 2012 Jul;30(3):218–26.
- Clark W, Clark WJ. Twin Block Functional

- Therapy. JP Medical Ltd; 2014. 500 p.
- Burhan AS, Nawaya FR. Dentoskeletal effects of the Bite-Jumping Appliance and the Twin-Block Appliance in the treatment of skeletal Class II malocclusion: a randomized controlled trial. *Eur J Orthod*. 2015 Jun;37(3):330–7.
- Tarvade SM, Chaudhari CV, Daokar SG, Biday SS, Ramkrishna S, Handa AS. Dentoskeletal Comparison of Changes Seen in Class II Cases Treated by Twin Block and Forsus. *J Int Oral Health*. 2014 Jun;6(3):27–31.
- Rohida NS, Bhad WA. Accidental ingestion of a fractured Twin-block appliance. *Am J Orthod Dentofacial Orthop*. 2011 Jan;139(1):123–5.
- Lee KY, Park JH, Tai K, Chae JM. Treatment with Twin-block appliance followed by fixed appliance therapy in a growing Class II patient. *Am J Orthod Dentofacial Orthop*. 2016 Nov;150(5):847–63.
- Neelakantan P, Grotra D, Sharma S. Retreatability of 2 mineral trioxide aggregate-based root canal sealers: a cone-beam computed tomography analysis. *J Endod*. 2013 Jul;39(7):893–6.
- Aldhuwayhi S, Mallineni SK, Sakhamuri S, Thakare AA, Mallineni S, Sajja R, et al. Covid-19 Knowledge and Perceptions Among Dental Specialists: A Cross-Sectional Online Questionnaire Survey. *Risk Manag Healthc Policy*. 2021 Jul 7;14:2851–61.
- Sheriff KAH, Ahmed Hilal Sheriff K, Santhanam A. Knowledge and Awareness towards Oral Biopsy among Students of Saveetha Dental College [Internet]. Vol. 11, *Research Journal of Pharmacy and Technology*. 2018. p. 543. Available from: <http://dx.doi.org/10.5958/0974-360x.2018.00101.4>
- Markov A, Thangavelu L, Aravindhan S, Zekiy AO, Jarahian M, Chartrand MS, et al. Mesenchymal stem/stromal cells as a valuable source for the treatment of immune-mediated disorders. *Stem Cell Res Ther*. 2021 Mar 18;12(1):192.
- Jayaraj G, Ramani P, Herald J, Sherlin, Premkumar P, Anuja N. Inter-observer agreement in grading oral epithelial dysplasia – A systematic review [Internet]. Vol. 27, *Journal of Oral and Maxillofacial Surgery, Medicine, and Pathology*. 2015. p. 112–6. Available from: <http://dx.doi.org/10.1016/j.ajoms.2014.01.006>
- Paramasivam A, Priyadharsini JV, Raghunandhakumar S, Elumalai P. A novel COVID-19 and its effects on cardiovascular disease. *Hypertens Res*. 2020 Jul;43(7):729–30.
- Li Z, Veeraraghavan VP, Mohan SK, Bolla SR, Lakshmanan H, Kumaran S, et al. Apoptotic induction and anti-metastatic activity of eugenol encapsulated chitosan nanopolymer on rat glioma C6 cells via alleviating the MMP signaling pathway [Internet]. Vol. 203, *Journal of Photochemistry and Photobiology B: Biology*. 2020. p. 111773. Available from: <http://dx.doi.org/10.1016/j.jphotobiol.2019.111773>
- Gan H, Zhang Y, Zhou Q, Zheng L, Xie X, Veeraraghavan VP, et al. Zingerone induced caspase-dependent apoptosis in MCF-7 cells and prevents 7,12-dimethylbenz(a)anthracene-induced mammary carcinogenesis in experimental rats. *J Biochem Mol Toxicol*. 2019 Oct;33(10):e22387.
- Dua K, Wadhwa R, Singhvi G, Rapalli V, Shukla SD, Shastri MD, et al. The potential of siRNA based drug delivery in respiratory disorders: Recent advances and progress. *Drug Dev Res*. 2019 Sep;80(6):714–30.
- Mohan M, Jagannathan N. Oral field cancerization: an update on current concepts. *Oncol Rev*. 2014 Mar 17;8(1):244.
- Website [Internet]. Available from: Jayaraj, Gifrina, Pratibha Ramani, Herald J. Sherlin, Priya Premkumar, and N. Anuja. 2015. “Inter-Observer Agreement in Grading Oral Epithelial Dysplasia – A Systematic Review.” *Journal of Oral and Maxillofacial Surgery, Medicine, and Pathology*. <https://doi.org/10.1016/j.ajoms.2014.01.006>.
- Website [Internet]. Available from: Li, Zhenjiang, Vishnu Priya Veeraraghavan, Surapaneni Krishna Mohan, Srinivasa Rao Bolla, Hariprasath Lakshmanan, Subramanian Kumaran, Wilson Aruni, et al. 2020. “Apoptotic Induction and Anti-Metastatic Activity of Eugenol Encapsulated Chitosan Nanopolymer on Rat Glioma C6 Cells via Alleviating the MMP Signaling Pathway.” *Journal of Photochemistry and Photobiology B: Biology*. <https://doi.org/10.1016/j.jphotobiol.2019.111773>.
- Website [Internet]. Available from: Sheriff, K. Ahmed Hilal, K. Ahmed Hilal Sheriff, and Archana Santhanam. 2018. “Knowledge and Awareness towards Oral Biopsy among Students of Saveetha Dental College.” *Research Journal of Pharmacy and Technology*. <https://doi.org/10.5958/0974-360x.2018.00101.4>.
- Li L, Liu H, Cheng H, Han Y, Wang C, Chen Y, et al. CBCT evaluation of the upper airway morphological changes in growing patients of class II division 1 malocclusion with mandibular retrusion using twin block appliance: a comparative research. *PLoS One*. 2014 Apr 4;9(4):e94378.
- Siara-Olds NJ, Pangrazio-Kulbersh V, Berger J, Bayirli B. Long-term dentoskeletal changes with the Bionator, Herbst, Twin Block, and



- MARA functional appliances. *Angle Orthod.* 2010 Jan;80(1):18–29.
- Jena AK, Duggal R, Parkash H. Skeletal and dentoalveolar effects of Twin-block and bionator appliances in the treatment of Class II malocclusion: a comparative study. *Am J Orthod Dentofacial Orthop.* 2006 Nov;130(5):594–602.
- Baysal A, Uysal T. Dentoskeletal effects of Twin Block and Herbst appliances in patients with Class II division 1 mandibular retrognathia. *Eur J Orthod.* 2014 Apr;36(2):164–72.
- Gill D, Sharma A, Naini F, Jones S. The twin block appliance for the correction of Class II malocclusion. *Dent Update.* 2005 Apr;32(3):158–60, 163–4, 167–8.
- Parekh J, Counihan K, Fleming PS, Pandis N, Sharma PK. Effectiveness of part-time vs full-time wear protocols of Twin-block appliance on dental and skeletal changes: A randomized controlled trial. *Am J Orthod Dentofacial Orthop.* 2019 Feb;155(2):165–72.
- Flores-Mir C, Major PW. Cephalometric facial soft tissue changes with the twin block appliance in Class II division 1 malocclusion patients. A systematic review. *Angle Orthod.* 2006 Sep;76(5):876–81.
- Khoja A, Fida M, Shaikh A. Cephalometric evaluation of the effects of the Twin Block appliance in subjects with Class II, Division 1 malocclusion amongst different cervical vertebral maturation stages. *Dental Press J Orthod.* 2016 Jun;21(3):73–84.
- Varghese, Subramanian. Comparison of dentoskeletal changes in skeletal class II cases using two different fixed functional appliances: Forsus fatigue resistant device and powerscope .... *J Int Adv Otol* [Internet]. 2021; Available from:  
<https://www.jioh.org/article.asp?issn=0976-7428;year=2021;volume=13;issue=3;spage=234;epage=244;aulast=Varghese>